

New Zealand Obstetric Ultrasound Guidelines

2019

Acknowledgements

The Ministry of Health appreciates the time, expertise and commitment of those involved in developing the New Zealand Obstetric Ultrasound Guidelines.

Content within these guidelines is derived and modified from Canterbury District Health Board's obstetric imaging guidelines with permission.

All scan images were kindly provided by members of the clinical working group.

Members of the clinical working group

Dr Rachael McEwing, Radiologist (Chair)

Dr David Perry, Paediatric and Obstetric Radiologist

Gill Waterhouse, Sonographer

Dr Pippa Kyle, Consultant Obstetrician and Maternal Fetal Medicine Specialist

Rex de Ryke, Charge Sonographer

Peer reviewers

Dr Jay Marlow, Maternal Fetal Medicine Specialist

Martin Necas, Clinical Specialist Sonographer

Dr Rachel Belsham, Radiologist

Dr Tom Gentles, Paediatric Cardiologist

Citation: Ministry of Health. 2019. *New Zealand Obstetric Ultrasound Guidelines*. Wellington: Ministry of Health.

Published in December 2019 by the Ministry of Health
PO Box 5013, Wellington 6140, New Zealand

ISBN 978-1-98-859749-2 (online)

HP 7284



This document is available at health.govt.nz



This work is licensed under the Creative Commons Attribution 4.0 International licence. In essence, you are free to: share ie, copy and redistribute the material in any medium or format; adapt ie, remix, transform and build upon the material. You must give appropriate credit, provide a link to the licence and indicate if changes were made.

Abbreviations

22q11.2 deletion	DiGeorge syndrome; a disorder caused by the deletion of a small piece of chromosome 22
3VT	Three vessel and trachea
4Ch	Four-chamber
AC	Abdominal circumference
AFI	Amniotic fluid index
AIP	Abnormally invasive placenta
ASD	Atrial septal defect
AV	Atrioventricular
AVSD	Atrioventricular septal defect
BCA	Brachiocephalic artery
βhCG	Beta human chorionic gonadotropin
BPD	Biparietal diameter
bpm	Beats per minute
CAT	Common arterial trunk
cc-TGA	Congenitally corrected transposition of the great arteries
cfDNA	Cell-free DNA
CHD	Congenital heart disease
CPR	Cerebroplacental ratio
CRL	Crown-rump length
CSP	Cavum septum pellucidum
CVS	Chorionic villus sampling
DA	Ductus arteriosus
DCDA	Dichorionic diamniotic
DHB	District health board
D-TGA	Complete transposition of the great arteries
DV	Ductus venosus
DVP	Deepest vertical pocket
EDD	Estimated date of delivery
EFW	Estimated fetal weight
FGR	Fetal growth restriction
FL	Femur length
FMF	Fetal Medicine Foundation
GA	Gestational age
GAP	Growth Assessment Protocol
GDM	Gestational diabetes mellitus
HC	Head circumference
HLHS	Hypoplastic left heart syndrome
IAA	Interruption of the aortic arch
IDDM	Insulin-dependent diabetes mellitus
ISUOG	International Society of Ultrasound in Obstetrics and Gynecology
IUCD	Intrauterine contraceptive device
IUFD	Intrauterine fetal death
IVC	Inferior vena cava
IVF	In vitro fertilisation
IVS	Interventricular septum
LGA	Large for gestational age
LLETZ	Large loop excision of the transformation zone
LMC	Lead maternity carer
LMP	Last menstrual period

LSA	Left subclavian artery
LV	Left ventricle
LVOT	Left ventricular outflow tract
MC	Monochorionic
MCA	Middle cerebral artery
MCDA	Monochorionic diamniotic
MCMA	Monochorionic monoamniotic
MFM	Maternal fetal medicine
MoM	Multiples of the median
MRI	Magnetic resonance imaging
MSD	Mean sac diameter
MSS2	Second-trimester maternal serum screening
MUAG	Maternity Ultrasound Advisory Group
NIDDM	Non-insulin dependent diabetes mellitus
NIPS	Non-invasive prenatal screening
NSU	National Screening Unit
NT	Nuchal translucency
NZMFMN	New Zealand Maternal Fetal Medicine Network
PA	Pulmonary artery
PDA	Patent ductus arteriosus
PET	Pre-eclampsia toxaemia
PI	Pulsatility index
PID	Pelvic inflammatory disease
PPROM	Preterm premature rupture of membranes
PROM	Premature rupture of membranes
PSV	Peak systolic velocity
PUL	Pregnancy of unknown location
PV	Blood loss <i>per vaginam</i> (vaginal bleeding)
RANZCOG	The Royal Australian and New Zealand College of Obstetricians and Gynaecologists
RIF	Right iliac fossa
ROI	Region of interest
RUQ	Right upper quadrant
RV	Right ventricle
RVOT	Right ventricular outflow tract
sFGR	Selective fetal growth restriction
SFH	Symphysial-fundal height
SGA	Small for gestational age
SROM	Spontaneous rupture of membranes
SVC	Superior vena cava
T2DM	Type 2 diabetes mellitus
TA	Transabdominal
TAPS	Twin anaemia-polycythaemia sequence
TGA	Transposition of the great arteries
TIS	Thermal index in soft tissue
TIB	Thermal index in bone
TOF	Tetralogy of Fallot
TOP	Termination of pregnancy
TORCH	Toxoplasmosis, other (syphilis, varicella-zoster, parvovirus B19), rubella, cytomegalovirus – CMV – and herpes infections
TRAP	Twin reversed arterial perfusion
TTTS	Twin-to-twin transfusion syndrome
TV	Transvaginal
UA	Umbilical artery
VSD	Ventricular septal defect

Contents

Abbreviations	iii
Introduction	1
First trimester	4
First-trimester ultrasound	4
Normal early intrauterine pregnancy	8
Early pregnancy loss	11
Ectopic pregnancy and pregnancy of unknown location	13
First-trimester reporting pro forma	16
12–13+6 week scan	18
12–13+6 week scan reporting guide and pro forma	21
Cervical length screening	25
Anatomy scan	29
Second-trimester anatomy scan (19+ weeks)	29
Placenta	38
Fetal echocardiography	47
Anatomy scan reporting pro forma	51
Cardiac anomalies	54
Third trimester	78
Third-trimester scan	78
Hydrops	86
Third-trimester reporting pro forma	89
Doppler	92
Twin pregnancy	102
References	109

Appendix 1: Ultrasound scan codes and indications	113
Appendix 2: Low gestational sac in the first trimester with previous caesarean section	115
Appendix 3: Ectopic pregnancy location	117
Appendix 4: Findings in ectopic pregnancy	119
Appendix 5: Non-invasive prenatal screening	120
Appendix 6: Placental anomalies	122
Appendix 7: Fetal renal tract dilation charts	126
Appendix 8: Anatomic locations of ventricular septal defects	128
Appendix 9: SGA scanning schedule	130

List of Figures

Figure 1: β hCG chart	9
Figure 2: Crown-rump length	10
Figure 3: IVS imaging technique	82
Figure 4: IVS reference chart	82
Figure A8.1: Diagrammatic representation of possible VSD locations on standard echo views	129

Introduction

The purpose of this document is to establish detailed, quality guidelines for maternity ultrasound, as recommended by the Maternity Ultrasound Advisory Group¹ (MUAG), to ensure that diagnostic ultrasound usage in New Zealand is clinically appropriate and uniformly of high quality.

Currently, there are local variations in both ultrasound examinations and referral pathways. The ultrasound images documented in these guidelines are minimum images, and extended examination should be performed as appropriate.

If there is concern at any stage about fetal anomaly or wellbeing, prompt referral is required as per local referral pathways.

The following screening examinations are part of routine primary maternity health care in New Zealand and should be offered to all pregnant women.

- **12–13+6 week scan**
- **19+ week anatomy scan.**

An uncomplicated pregnancy does not generally require additional first-trimester (eg, dating) or third-trimester (eg, growth) scans. Specific clinical indications for examinations other than the two screening scans listed above require an appropriate clinical code as per the Maternity Services Notice (the Notice) pursuant to Section 88 of the New Zealand Public Health and Disability Act 2000 (Department of Internal Affairs 2007, see **Appendix 1: Ultrasound scan codes and indications**).

These guidelines contain reporting recommendations, including alerts for conditions requiring urgent or semi-urgent notification to referrers.

Reporting templates are also included, but it is expected that there may be local variation in reporting pro forma.

These often complex examinations must be performed by appropriately credentialed sonographers, radiologists, sonologists, obstetric consultants with training in diagnostic ultrasound or trainees under direct supervision.

The ultrasound equipment used must be fit for purpose and appropriately maintained and serviced.

¹ The MUAG was a subgroup of the National Maternity Monitoring Group. For more information see: www.health.govt.nz/publication/national-maternity-monitoring-group-annual-report-2017

Pregnancy imaging without clinical indication

Any ultrasound scan that a woman is referred for should clearly note the appropriate clinical code and clinical indication. Ultrasound scanning for the purpose of obtaining souvenir images of the fetus is not appropriate and is not funded under the Notice.

For more information, see the **ISUOG statement on the non-medical use of ultrasound, 2009** (Abramowicz et al 2009).

The use of ultrasound should be based on rational clinical need and be underpinned by evidence-based practice. Users of ultrasound must be familiar with biological safety considerations and must implement safe practices during real-time imaging.²

It is recommended that this document is not printed for clinical use, as printed versions may not reflect the most recent version available online at **www.health.govt.nz**

The guidelines will be reviewed in 2022 or as new information becomes available.

This document refers to several guidelines produced by the New Zealand Maternal Fetal Medicine Network (NZMFMN), which is not currently active. The NZMFMN website and guidelines may not be updated in the future, so care should be taken when viewing guidelines not directly linked by this document.

² The thermal index in soft tissue (TIS) should be used in gestations under 10 weeks of gestational age and thermal index in bone (TIB) in gestations beyond 10 weeks. The value of the thermal index should be ≤ 0.7 for the majority of routine examinations. Attention to the thermal index should be paid particularly during M-mode, colour and spectral Doppler imaging as well as during transvaginal (TV) imaging.

Reporting alerts

Emergency

Requires **immediate transfer** to an appropriate local secondary or tertiary hospital if there is immediate risk to life (in an ambulance if in the community, as appropriate).

Examples include:

- abruption
- PV bleeding in the context of suspected accreta
- open cervix
- haemodynamically unstable woman
- sustained fetal bradycardia/tachycardia in a viable pregnancy.

Urgent

Requires phone discussion with the referrer before the woman leaves the department to determine management (same-day assessment is usually required). If not available, then contact the local maternity assessment unit.

Examples include:

- critically abnormal Doppler, for example, umbilical artery absent or reversed end-diastolic flow
- ectopic pregnancy in a stable woman
- fetal hydrops.

Same day

Requires same-day phone discussion with the referrer.

Examples include:

- small for gestational age (SGA) without abnormal Doppler
- unexpected fetal anomaly or demise.

Note: Conditions and situations included in the reporting alerts boxes are not exhaustive and use of clinical judgment is required.

First trimester

First-trimester ultrasound

Routine ultrasound should not be offered or requested simply to confirm an ongoing early pregnancy in the absence of any clinical concerns, symptoms or specific indications.

The first ultrasound of the pregnancy should ideally be offered when the gestational age is thought to be between **12 and 13+6 weeks** gestation (see below) for optimal assessment of fetal anatomy and nuchal translucency (NT). The purpose of the scan is to confirm viability, accurately establish gestational age, determine the number of viable fetuses, evaluate gross fetal anatomy and, if requested, assess the NT as part of the risk assessment for aneuploidy.

Indications for early pregnancy scans (less than 12 weeks)

Indications include:

- bleeding or pain in early pregnancy, or concern about pregnancy loss (section 88 codes **TA and EP**)³
- consideration of termination of pregnancy (section 88 code **CT**)
- unknown dates* (section 88 code **BA**)
- hyperemesis gravidarum
- trauma
- pregnancy with an intrauterine contraceptive device (IUCD) in situ
- previous ectopic pregnancy (section 88 code **EP**)
- complex medical conditions where a change of medication may be indicated such as warfarin.

* **Please note: Confirmation of dates by ultrasound is not routinely required before the 12-week scan.**

³ See **Appendix 1: Ultrasound scan codes and indications** for a full list of the current codes for claiming for ultrasound scans through the New Zealand Public Health and Disability Act 2000 Primary Maternity Services Notice 2007.

Required clinical details

- Last menstrual period (LMP)
- Woman's symptoms
- Beta human chorionic gonadotropin (β hCG) if available
- Previous relevant history
- Appropriate section 88 code
- Previous caesarean section.

Early pregnancy ultrasound examination

- First trimester dating should be determined by crown-rump length (CRL) not from mean gestational sac diameter as the latter is less accurate.
- Estimated date of delivery (EDD) and gestational age (GA) from known in vitro fertilisation (IVF) dates should not be changed.
- Most early pregnancy scans less than 7 weeks will require transabdominal (TA) and transvaginal (TV) imaging.
- TA imaging alone may be sufficient if excellent visualisation of a live intrauterine embryo is achieved and the woman is asymptomatic.
- TV imaging should always be offered when the indication includes abnormal symptoms, such as bleeding or pain.

Early pregnancy scans should include the following as a minimum.

- Determination of the gestational sac location
- Imaging of the relationship of the sac to previous caesarean section scar (see **Appendix 2: Low gestational sac in the first trimester with previous caesarean section**)
- Imaging of yolk sac
- Imaging of embryo (fetal pole)
- CRL
- Imaging of embryonic cardiac activity – document with a cine clip if possible; otherwise annotate cardiac activity present or absent on the relevant image
- Documenting of dates by CRL (see below)
- An assessment of region(s) of haemorrhage
- An assessment of the chorionicity and amnionicity of **multiple pregnancy** (see NZMFMN 2015f)
- An assessment of myometrium, adnexa and degree of free fluid in the pelvis.

See also the sections to follow on:

- **Normal early intrauterine pregnancy**
- **Early pregnancy loss**
- **Ectopic pregnancy and pregnancy of unknown location.**

Reporting guide and referral recommendations

Minimum reporting requirements

Scan technique (TA/TV). Document if the woman declined a TV scan.

Document findings as per **Early pregnancy ultrasound examination** (see above):

- sac location (see **Appendix 3: Ectopic pregnancy location**)
- CRL (date pregnancy if embryo is present)
- mean sac diameter (MSD) if no embryo identified
- cardiac activity
- EDD by CRL if embryo is present
- uterine and adnexal masses (such as fibroids, ovarian cysts, dermoids and other findings)
- free fluid
- significant haemorrhage (small asymptomatic haemorrhages do not need to be reported).

Guide to assessing gestational age with ultrasound

The following guidelines are adapted from the 2017 ASUM First Trimester Ultrasound Standard of practice.

The CRL provides the most accurate estimation of gestational age in the first trimester.

Before an embryo is visible, the MSD can support gestational age by LMP but should not be used to determine EDD.

Once a live embryo is visible, the CRL should be used to calculate the due date. The MSD should not be included in this calculation.

After 11 weeks, multiparametric assessment can be used with biparietal diameter (BPD) being the most often used second measurement.

Accuracy of dating:

- ± 4 days by CRL at ≤ 10 weeks
- ± 7 days by biometry from 10–20 weeks
- ± 14 days from 20–30 weeks
- ± 21 days from 30 weeks.

EDD by assisted reproduction dates (eg, IVF) should not be adjusted.

In the presence of twins, the CRL for the larger twin is used in assessing the EDD.

For more information, see the *Guidelines for the Performance of First Trimester Ultrasound G02* (ASUM 2017).

For reporting pro forma examples, see **First trimester reporting pro forma** below.

Reporting alerts

- Ruptured ectopic pregnancy

- Ectopic without evidence of rupture

- Early pregnancy loss
- Suspected molar pregnancy
- **Implantation of the sac on the caesarean scar**, see Appendix 2 (this indicates a risk of placenta accreta spectrum disorder and requires specialist referral).

Normal early intrauterine pregnancy

Structure development

Structures generally develop in the following predictable sequence.

1. Gestational sac
2. Double decidual reaction
3. Yolk sac (yolk sac with intrauterine gestational sac confirms early intrauterine pregnancy)
4. Embryo
5. Embryonic heartbeat.

The timing of structure development is also fairly predictable.

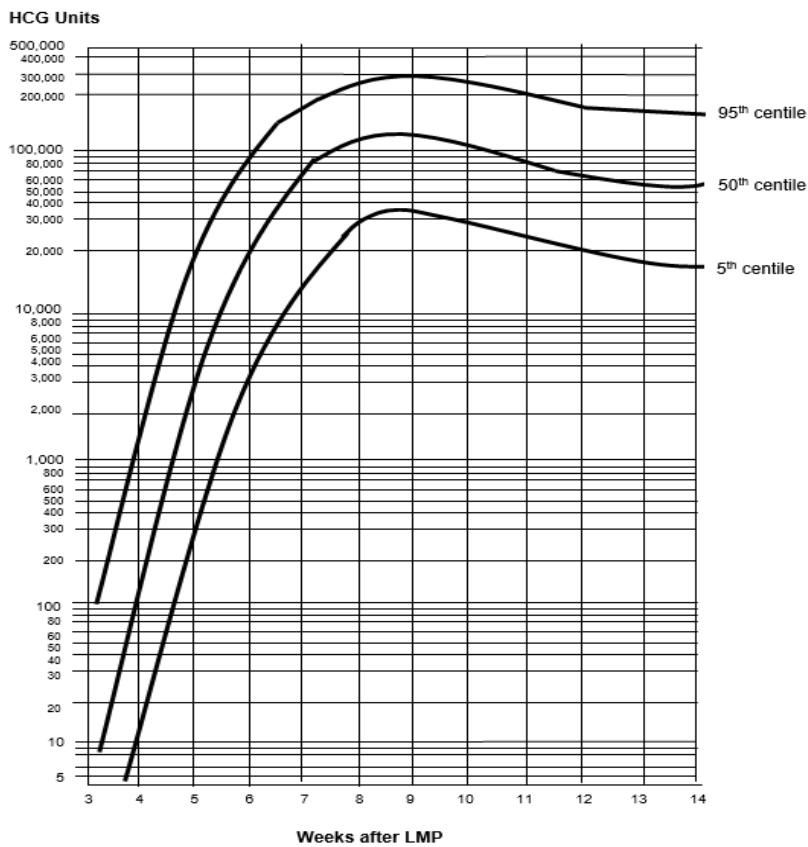
1. Gestational sac:
 - Visible at approximately 5 weeks gestation, \pm 4 days.
2. Yolk sac:
 - Visible at approximately 5½ weeks gestation, \pm 4 days.
3. Embryo and heartbeat:
 - Visible at approximately 6 weeks gestation, \pm 4 days.

General considerations

Beta hCG

Correlate with ultrasound appearances (see below) and refer to local clinical guidelines.

Figure 1: β hCG chart



Source: Canterbury SCL, April 2019.

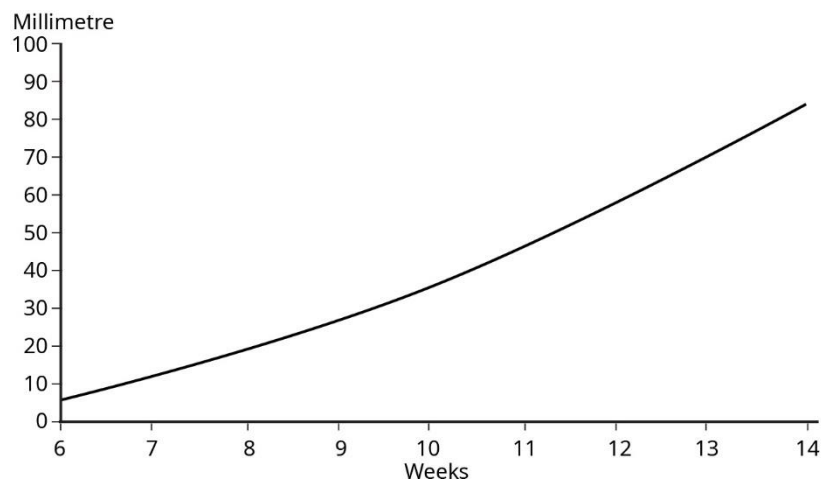
Yolk sac

The presence of a yolk sac within the intrauterine gestational sac confirms an intrauterine pregnancy and essentially excludes ectopic pregnancy. Heterotopic pregnancy is very rare but should be considered if there are suggestive ultrasound features, particularly in the setting of assisted reproductive technology.

Crown-rump length

Growth is approximately 1.2 mm per day, but may be less in a normally developing pregnancy. Interval growth of CRL alone should not be used as a determinant of pregnancy loss.

Figure 2: Crown-rump length



Data source: Westerway et al 2000.

Cardiac activity

Embryonic cardiac activity should always be visualised with a CRL ≥ 7 mm.

Slow embryonic heart rate of < 80 bpm may suggest a guarded prognosis for the pregnancy. Suggest a follow-up scan if clinically appropriate.

Early pregnancy loss

An early pregnancy scan (less than 12 weeks) is indicated when there is bleeding or pain in early pregnancy, or concern about pregnancy loss (section 88 codes **TA and EP**, see Appendix 1).

Required clinical details

- LMP
- Woman's symptoms
- β hCG if available
- Previous relevant history
- Appropriate section 88 code
- Previous caesarean section.

Early pregnancy loss ultrasound examination

No guidelines exist for TA assessment of pregnancy loss, and therefore TV assessment should always be offered.

The scan should include imaging of the following structures (if present).

- Sac location and size (MSD)
- Relationship of the sac to previous caesarean section scar (see **Appendix 2: Low gestational sac in the first trimester with previous caesarean section**)
- Yolk sac
- Embryo (fetal pole)
- CRL
- Embryonic cardiac activity – document with a cine clip if possible; otherwise annotate cardiac activity present or absent on the relevant image
- Absent cardiac activity may be confirmed with colour Doppler assessment if required
- Assess region(s) of haemorrhage
- Assess chorionicity and amnionicity of **multiple pregnancy** (see NZMFMN 2015f)
- Adnexa (document any adnexal masses and free fluid)
- Document fibroids (size and location)
- Document free fluid in acute presentations.

Diagnosis of early pregnancy loss

An experienced practitioner using high-quality TV equipment may diagnose pregnancy loss under any of the following circumstances.

At initial or follow-up scan:

1. when the MSD is ≥ 25 mm with no visible yolk sac or embryo; or
2. when there is a visible embryo with CRL ≥ 7 mm, but no cardiac activity can be demonstrated. The area of the embryonic heart should be observed and documented with a cine clip if possible; otherwise annotate cardiac activity present or absent on the relevant image.

On follow-up scan:

1. if the initial scan showed an embryo CRL < 7 mm with no cardiac activity and a repeat scan in seven or more days also shows no cardiac activity
2. if the initial scan showed a MSD ≥ 12 mm with no embryo and a repeat scan in 7 or more days does not show interval development of a yolk sac or an embryo
3. if the initial scan showed a MSD < 12 mm with no embryo and a repeat scan in 14 or more days shows no visible yolk sac or embryo
4. if a yolk sac is visible on initial scan and there is no embryo with a heartbeat after 11 days
5. absence of cardiac activity, which was seen to be present on an earlier scan.

Seek a second opinion: where there is any doubt about a diagnosis of pregnancy loss or if the practitioner is inexperienced. If required, a follow-up scan in 1 week or more is recommended. If the MSD is < 10 mm at the initial scan, a follow-up scan should be performed more than 14 days later.

No guidelines exist for TA assessment of pregnancy loss. If the woman declines TV imaging, then cautious clinical judgement must be used, with low threshold for follow-up imaging, ideally with a 14-day interval.

For more information, see the articles:

- **Defining safe criteria to diagnose miscarriage: prospective observational multicentre study** (Preisler et al 2015)
- **Diagnostic criteria for nonviable pregnancy early in the first trimester** (Doubilet et al 2013).

Ectopic pregnancy and pregnancy of unknown location

Ectopic pregnancy

Risk factors for ectopic pregnancy

- Previous ectopic pregnancy
- Known inflammatory condition, for example, pelvic inflammatory disease (PID), endometriosis
- IUCD
- IVF
- Previous surgery or instrumentation (eg, caesarean section, tubal ligation).

Clinical signs and symptoms

Clinical diagnosis may be difficult because the symptoms and signs are often non-specific, but they will include:

- pain
- PV bleeding (vaginal bleeding)
- a positive pregnancy test
- poorly rising serum β hCG
- signs of haemodynamic instability (eg, drowsiness, fatigue, pale skin, sweating).

Atypical symptoms and signs

In up to 70 percent of cases, there will be:

- vague discomfort
- contralateral pain
- no PV bleeding
- back pain, vaginal pain, bowel symptoms
- low or normal serum β hCG
- asymptomatic.

Sonographic features of ectopic pregnancy

Sonographic features of ectopic pregnancy may include:

- no intrauterine gestational sac
- endometrial pseudogestational sac (see **Appendix 4: Findings in ectopic pregnancy**)
- adnexal mass
- free fluid or haemoperitoneum (see **Appendix 4: Findings in ectopic pregnancy**).

Ectopic pregnancy ultrasound examination

- Sac location – atypical location of the gestational sac in relation to the endometrial cavity should be reported. This is particularly important for:
 - low-positioned gestational sac, adjacent to or bulging into a caesarean section scar (see **Appendix 2**)
 - cornual or cervical location, separate to the endometrial cavity (often best shown on three-dimensional coronal imaging); document overlying myometrial thickness
 - yolk sac
- Embryo (fetal pole)
- CRL
- Embryonic cardiac activity – document with a cine clip if possible; otherwise annotate cardiac activity present or absent on the relevant image
- Adnexa
- Document free fluid.

Reporting guide and referral recommendations

Minimum reporting requirements

Scan technique (TA/TV). Document if the woman declined a TV scan.

Document findings as per **Ectopic pregnancy ultrasound examination** (see above):

- sac location (see **Appendix 3: Ectopic pregnancy location**)
- CRL (date pregnancy if embryo is present)
- MSD if no embryo identified
- cardiac activity
- adnexal mass or haemorrhage
- largest diameter of ectopic mass or gestational sac
- free fluid – location and amount (document free fluid at or above the uterine fundus).

Note: It is strongly recommended that a β hCG result is available at the time of the ultrasound scan.

Pregnancy of unknown location

There is no defined cut-off β hCG level at which ectopic pregnancy can be excluded. Rather, it is the change in hCG over time that is of value. The clinical scenario in which there is a positive pregnancy test and in which there is no sonographic evidence of intra- or extra-uterine pregnancy and where there are no obvious retained products of conception on TVS, is defined as a pregnancy of unknown location (PUL).

Under these circumstances, there are three possibilities.

1. Early intrauterine pregnancy
2. Ectopic pregnancy
3. Early pregnancy loss.

Reporting alerts

- Ruptured ectopic pregnancy

- Ectopic without evidence of rupture

- Early pregnancy loss
- **Implantation of the sac on the caesarean scar**, see Appendix 2 (this indicates a risk of placenta accreta spectrum disorder and requires specialist referral).

First-trimester reporting pro forma

Normal first-trimester scan

Clinical

[]

LMP: []

EDD by today's ultrasound: []. (EDD by dates: [])*

Gestational age: [] weeks, [] days \pm 4 days

(Gestational age by dates: [] weeks, [] days).*

* May be included to highlight any discrepancy between ultrasound and clinical dates in the first scan of the pregnancy but should not be used after this.

Findings

[TA/TV] scan

Anteverted uterus

There is a single live intrauterine pregnancy

CRL = [] mm

Heartbeat seen, rate = [] bpm.

Right ovary: [normal size and appearance]

Left ovary: [normal size and appearance]

No adnexal abnormality.

Comment

Single live intrauterine pregnancy, [] weeks [] days \pm [] days by scan today.

No complications.

Ultrasound findings

Intrauterine fluid collection, uncertainty whether or not early sac

Probable early intrauterine pregnancy, approximately 4 weeks \pm 4 days. No yolk sac or embryo is evident, too early to confirm live intrauterine pregnancy. There are no specific ultrasound features to suggest an ectopic pregnancy, but this cannot be entirely excluded.

If appropriate, β hCG correlation and a follow-up scan in 14 days could be considered, if there is low clinical likelihood of ectopic pregnancy.

Intrauterine sac containing a yolk sac

Early intrauterine pregnancy, 5½ weeks ± 4 days. A yolk sac is evident but no embryo, too early to confirm live intrauterine pregnancy.

If there is clinical concern, βhCG correlation and a follow-up scan in 14 days is recommended.

Pregnancy loss with CRL ≥7 mm and no cardiac activity

Unfortunately, appearances today are those of early pregnancy loss, [] weeks, [] days by CRL. [Woman's name] is aware of the findings, and the results have been telephoned to [referrer's name].

Embryo CRL <7 mm with no cardiac activity

Early intrauterine pregnancy [] weeks [] days ± 4 days by CRL. No cardiac activity is evident, possibly too early. A follow-up scan is suggested in 7 days to confirm ongoing pregnancy.

Empty sac MSD ≥12 mm but <25 mm

There is an empty gestational sac with MSD of [] mm. Appearances are concerning, however, ultrasound criteria for a pregnancy loss have not been met. Correlation with βhCG and a follow-up scan in 7 days is recommended.

Empty sac MSD <12 mm

There is an empty gestational sac with MSD of [] mm. Appearances are concerning, however, ultrasound criteria for a pregnancy loss have not been met. Correlation with βhCG and a follow-up scan in 14 days is recommended.

No intrauterine gestational sac without evidence of ectopic pregnancy / pregnancy of unknown location

An ectopic pregnancy cannot be excluded on this ultrasound alone. Please interpret scan with βhCG, using advice from gynaecology service or based on gynaecological protocols for PUL.

Serum βhCG

Beware: Very low or normal serum βhCG may occur in ectopic pregnancy. The βhCG level alone should not be relied upon to exclude possible ectopic pregnancy; however, higher levels with an empty uterus increase suspicion of ectopic pregnancy and when beyond 1,500, specialist opinion should be sought.

12–13+6 week scan

The 12+ week scan should be considered an early anatomy scan and may include NT assessment as part of combined screening for Down syndrome and other conditions (see **NSU, Antenatal Screening for Down syndrome and other conditions**).

The scan is optimally performed at 12–13+6 weeks' gestation (see ***Antenatal Screening for Down Syndrome and Other Conditions: Guidelines for health practitioners***, Ministry of Health 2013).

Indications

- Dating of pregnancy
- Early anatomy assessment
- Detection of multiple pregnancy (chorionicity and amnionicity)
- Screening for chromosomal anomalies and other conditions.

Section 88 codes: **NT and NF** (see Appendix 1).

Required clinical details

- LMP
- Any symptoms
- Previous relevant maternal or family history
- History of previous caesarean section.

Ultrasound examination

TA scan is usually adequate. Consider TV assessment if there are technical limitations, such as maternal habitus or retroverted uterus.

- Uterus – anteverted, retroverted
- Adnexa/ovaries
- Fibroids
- Dating – CRL, BPD
- Developing placental location
- Subjective evaluation of amniotic fluid
- **Fetal anatomy** (see below)
- NT for risk assessment if the woman accepts screening (Note: NT ≥ 3.5 mm may be an independent marker of cardiac or skeletal abnormality and Fetal Medicine or other local equivalent specialist review should be offered even if chromosome screening is not requested.).

Early fetal anatomy

Assessment of fetal anatomy is the major component of the 12+ week scan. The following routine fetal anatomy should be assessed as a minimum at the time of the NT scan.

- Skull and brain
- Stomach
- Bladder
- Spine
- Four limbs (document two arms, two legs, two hands and two feet)
- Cord insertion
- Three-vessel cord
- Four-chamber (4Ch) heart (if possible).

Other structures that may be examined, if possible, include:

- situs
- diaphragm
- posterior fossa
- kidneys
- orbits/lenses
- three-vessel view / cardiac outflow tracts
- facial triangle.

Nuchal translucency

- NT increases with gestational age and CRL – see **graph** (Nicolaidis et al 2001).
- An increased NT is associated with an increased risk of chromosomal abnormality, most commonly trisomies 21, 18 and 13.
- Cardiac and other structural and genetic anomalies may also be associated with an increased NT.
- NT measurement and combined screening assessment is not recommended in women with a previous non-invasive prenatal screening (NIPS)* result, and the NT should not be reported. The exception is if the NT is ≥ 3.5 mm, as this is an independent reason for Fetal Medicine or other local equivalent specialist referral.
- Risk assessment is performed as part of combined screening, with first-trimester bloods. The report must be sent to the appropriate laboratory, which is either:
 - **LabPLUS** at Auckland District Health Board (DHB), for Taupō and north of Taupō
 - **Canterbury Health Laboratories** at Canterbury DHB (for south of Taupō).
- If the CRL is greater than the accepted range at NT scan, NT / combined screening can be replaced by second-trimester maternal serum screening (MSS2) or NIPS.*

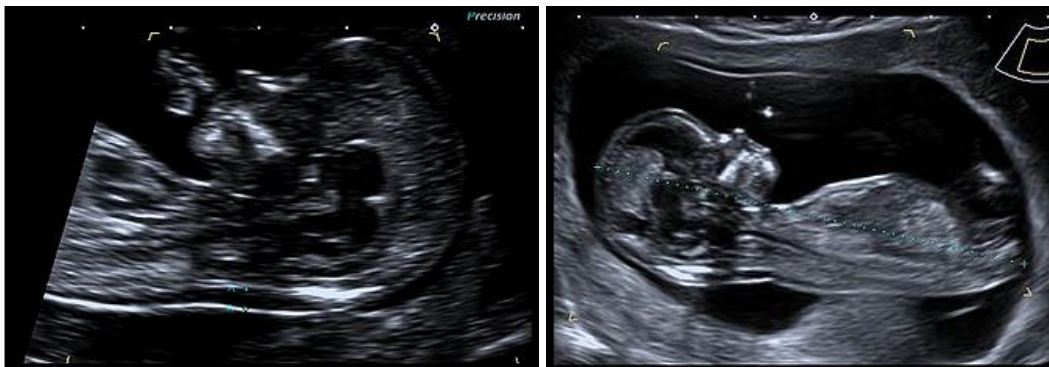
- * **Note:** NIPS is not part of the publicly funded antenatal screening for Down syndrome and other conditions. See **Appendix 5: Non-invasive prenatal screening** for more information.

Nuchal translucency assessment criteria

- Optimally performed at 12–13+6 weeks, or CRL ≥ 56 mm, and must be ≤ 84 mm
- Midline sagittal view
- Fetus magnified to 75 percent of screen, including the fetal head and thorax
- Fetal head in neutral position (ie, not flexed or extended)
- Ensure not measuring amnion (visualise fetus bouncing in real time)
- Measure maximal NT (calipers on-to-on, not including skin) – ideally demonstrate amnion separate to NT
- If nuchal cord is present, measure the NT both above and below the cord, and average the measurements
- Obtain at least three satisfactory images.

For more detail, see the NSU's *Antenatal Screening for Down Syndrome and Other Conditions: Guidelines for nuchal translucency (NT) and crown rump length (CRL) measurements* (Ministry of Health 2015).

Image 1



Measurements of NT (**left**) and CRL (**right**).

12–13+6 week scan reporting guide and pro forma

Reporting guide

Minimum reporting requirements

1. Dating information: CRL, BPD
2. Fetal anatomy documentation
3. NT measurement if combined screening is planned (best of at least three technically appropriate measurements).

Do not perform risk assessment in the Fetal Medicine Foundation (FMF) software. The report must be sent to the referrer and the laboratory.

The laboratory services will provide the referrer with the combined screening risk after combination with first-trimester maternal blood results (PAPP-A and hCG).

If **NT ≥ 3.5 mm** (or there is a cystic hygroma), report in the following manner.

‘NT is ..., increased. Referral to the Fetal Maternal Medicine Unit or local specialist service is recommended in all cases where NT ≥ 3.5 mm because of increased association with cardiac anomalies.’

If NT is required and cannot be obtained on the first attempt, consider a TV scan.

A further separate attempt at NT may be made (using section 88 code **NF**). More than two attempts on separate occasions is not recommended.

If assessment of anatomy is limited, for example, by retroverted uterus or maternal habitus, consider a TV scan.

If the woman presents for NT assessment but gestation is <12 weeks (but CRL is >45 mm) and there is excellent visualisation, NT assessment may be performed. However, anatomy assessment (particularly visualisation of the fetal bladder and skull ossification) may be limited and follow-up may still be required.

If the woman presents for NT assessment but gestation >13+6 weeks (or CRL >84 mm), perform fetal biometric and anatomic assessment as for an NT scan but do not measure the NT.

Report in the following manner.

‘The gestational age is [] weeks [] days, too late for NT risk assessment (possible only for CRL <84 mm). Second-trimester maternal serum screening, or NIPS (not publicly funded), may be considered.’

Fetal nasal bone

Fetal nasal bone is no longer part of combined screening in New Zealand as per the **National Screening Unit (NSU) recommendation** (Ministry of Health 2018) and should not be reported.

Reporting pro forma

Normal 12–13+6 week first-trimester scan

Clinical details

NT scan: for combined screening

LMP: []

EDD by today's ultrasound: []. (EDD by dates: [])*

Gestational age: [] weeks, [] days \pm 7 days

(Gestational age by dates: [] weeks, [] days).*

* *May be included to highlight any discrepancy between ultrasound and clinical dates in the first scan of the pregnancy but should not be used after this.*

First trimester ultrasound

Uterus: anteverted

Fetal heart action present.

CRL: [] mm

BPD: [] mm

NT: [] mm.

Fetal anatomy: skull/brain: appears normal; heart: not fully examined due to early gestation; spine: appears normal; abdomen: appears normal; stomach: visible; bladder: visible; hands: both visible; feet: both visible.

Placenta: [anterior/posterior]

Amniotic fluid: [normal].

Comment

Normal first trimester scan. NT= [] mm.

Combined screening is planned, therefore risk assessment has not been performed.

Sonographer: [name], [FMF number].

Increased NT ≥ 3.5 mm

Normal first trimester anatomy. Increased NT, [] mm. Combined screening is planned, therefore risk assessment has not been performed. A referral to Fetal Medicine or local equivalent specialist is recommended as NT ≥ 3.5 mm. An early detailed fetal heart scan should be considered at 16 weeks.

Gestation > 13+6 weeks (CRL > 84 mm)

Single live intrauterine pregnancy, [] weeks [] days \pm 7 days by today's scan. It is too late for NT assessment (only possible for CRL between 56 and 84 mm). Second-trimester maternal serum screening, or NIPS (not publicly funded), may be considered.

Gestation < 12 weeks (CRL < 56 mm)*

Single live intrauterine pregnancy, [] weeks [] days \pm [] days by today's scan. It is too early for accurate NT assessment. A follow-up scan has been arranged for [].

* Unless excellent visualisation of NT and fetal anatomy and CRL ≥ 45 mm.

Incomplete NT scan

Single live intrauterine pregnancy, [] weeks [] days \pm 7 days by today's scan. NT assessment was limited by [persistent difficult position]. A follow-up scan has been arranged for [date].

Incomplete NT scan on second attempt

Single live intrauterine pregnancy, [] weeks [] days \pm 7 days by today's scan. NT assessment remained limited today by [persistent difficult position]. This was the second attempt at NT assessment. Second-trimester maternal serum screening, or NIPS (not publicly funded), may be considered.

12+ week scan, NT screening not requested/declined or post NIPS

Single live intrauterine pregnancy, [] weeks [] days \pm 7 days by today's scan. Normal first trimester anatomy scan.

NT requested in context of previous NIPS

NT measurement and combined screening assessment is not recommended in women with a previous NIPS result, and the NT should not be reported. The exception is if the NT is ≥ 3.5 mm, as this is an independent reason for Fetal Medicine or other local equivalent specialist referral. Note: NIPS is not publicly funded.

Monochorionic-diamniotic twin pregnancy

Addend report:

Fortnightly scans to screen for twin-twin transfusion syndrome are recommended from 16 weeks.

Reporting alerts

- Ruptured ectopic pregnancy
- Pregnancy loss
- Structural fetal abnormality
- NT ≥ 3.5 mm
- **Low implantation of the sac with previous caesarean section scar** (see Appendix 2).

Cervical length screening

Indications

Women at high risk for spontaneous preterm birth and second-trimester loss who have had:

- a previous spontaneous preterm birth <36 weeks
- a previous spontaneous second-trimester loss 16–24 weeks
- a previous large loop excision of the transformation zone (LLETZ) procedure with known depth of excision ≥ 10 mm
- a knife cone biopsy or trachelectomy or more than one LLETZ procedure
- a known uterine or cervical anomaly, such as unicornuate uterus.

Routine cervical length scanning at the time of the mid trimester anatomy scan is not currently recommended. For more detail, see the NZMFMN statement **Routine measurement of cervical length at time of mid trimester anomaly scan in all women** (NZMFMN 2011b).

In the event of finding a short cervix before 24 weeks, specialist consultation should be sought.

Required clinical details

- Dating information
- Risk factors for spontaneous preterm birth/second-trimester loss (see **Indications** above)
- Any symptoms.

Ultrasound examination

For high-risk women, cervical screening should be performed every two weeks, from **16 up to 24 weeks**.

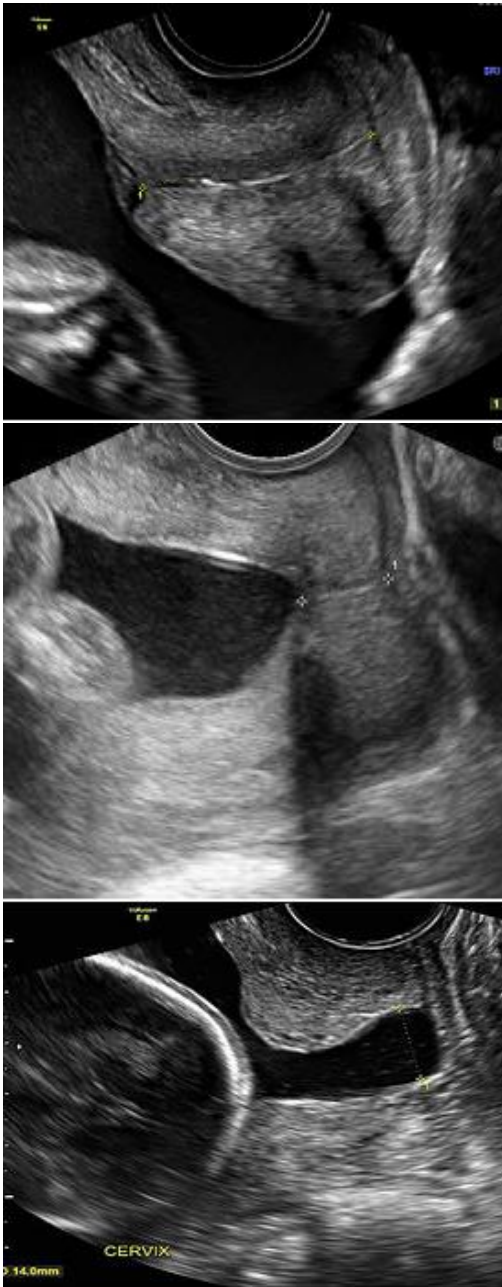Cervical imaging before 16 weeks or after 24 weeks may be required rarely, in some very high-risk individuals (at specialist discretion). These scans can be challenging to interpret and are best performed in specialised units.

A TV scan is required for accurate cervical length measurement (TA assessment with a full bladder falsely elongates the cervical length).

- Perform TV scan with an empty bladder.
- Angle the ultrasound probe gently towards the anterior fornix. Avoid exerting pressure on the cervix as this may falsely increase the apparent length of the cervix.
- Obtain a sagittal view of the cervix, using the endocervical mucosa (which may be of increased or reduced echogenicity compared with the cervix) as a guide to the true position of the internal os, as opposed to the lower segment of the uterus.
- Measure the linear distance between the triangular area of echodensity at the external os and the V-shaped notch at the internal os.
- Scan over a period of 2–3 minutes as the cervical length may change over time due to uterine contractions.
- Record the shortest measurement.
- Apply suprapubic and fundal pressure and record the **shortest** closed cervical length measurement.
- Funnelling is observed sonographically as dilatation of the internal os. The length of funnelling may be measured as the length of the open cervix from the level of the internal os to the medial point of the closed cervix. (Note: Documentation of width of funnelling is not clinically helpful.) Most women with a short cervix will have funnelling of the internal os. Reporting the presence of funnelling may aid clinicians in planning care, but the shortest closed length of the cervix is the only validated measure for predicting risk of preterm birth.
- If the cervix is obviously open with bulging membranes, perform TA and translabial scan if possible. TV scan should not be performed without first discussing it with the referrer.
- Third-trimester cervical length assessment is not recommended.

For further information, please see the FMF webpage: Education: Cervical assessment at: www.fetalmedicine.org/education/cervical-assessment.

Image 2



Normal cervical length (**top**), shortened cervix (**middle**), open cervix with funnelling and bulging membranes (**bottom**).

Reporting guide and referral recommendations

Minimum reporting requirements

1. Dating information, by earliest scan
2. Fetal biometry, if appropriate
3. Cervical length in mm, and any change with application of suprapubic/fundal pressure (Note: A measurement of <25 mm at <24 weeks gestation is considered to be a short cervix.)
4. Length of funnelling
5. If the cervix is completely open with no measurable cervical length, document these findings, along with presence of bulging of fetal membranes into the vagina or retained in the cervical canal
6. Recommend follow-up in 2 weeks (high-risk women only) if the cervix is normal in length
7. Urgent same-day specialist review is recommended for an open cervix.

Reporting alerts

- Open cervix ± bulging membranes

- Short cervix <25 mm.

Anatomy scan

Second-trimester anatomy scan (19+ weeks)

This is a routine screening examination, which should be offered to all women. For optimal visualisation, it is best performed after 19 weeks.

The purpose of the examination is to:

- assess fetal dates if there has been no earlier scan
- assess fetal biometry
- assess fetal anatomy and screen for structural abnormality
- establish placental location.

Section 88 codes: **AN, AF**, see Appendix 1.

Required clinical details

- First-trimester combined screening or **NIPS** result (see Appendix 5) if performed (Note: NIPS is not publicly funded.)
- EDD (and what the EDD is based on, eg, previous scan or LMP)
- Significant relevant obstetric history (maternal or family)
- Previous caesarean section.

Second-trimester dating

Dating should be based on earlier scans, if available. The pregnancy should not be dated at the anatomy scan unless this is the first scan or there is no information available.

If there have been no earlier scans, second-trimester dating can be estimated by biometry, for example, BPD, head circumference (HC), femur length (FL), trans-cerebellar diameter, and is generally accurate to within 7 days (± 7 days).

Ultrasound examination

The following should be assessed.

1. **Fetal number**
2. **Fetal cardiac activity**
3. **Biometry**
 - BPD
 - HC
 - AC
 - FL
4. **Placenta**
 - Ask about any previous caesarean section and document placental location in relation to the scar
 - Location – anterior, posterior, fundal
 - Transverse and longitudinal planes
 - Distance from internal cervical os – measure in mm
 - A full bladder can simulate a low-lying placenta – if in doubt, get the woman to empty her bladder
 - Consider TV scan if not well visualised
 - Less than 20 mm is considered low lying. Third-trimester follow-up is recommended.
 - Placental cord insertion and its location

For further information, see **Placenta** below.
5. **Amniotic fluid:** subjective assessment
6. **Document maternal structures**
 - Adnexa
 - Uterine fibroids
7. **Fetal anatomy** (as described below).

At a minimum, achieve the following.

Extended views, if achievable, are in italics and marked with *. Note: Failure to visualise these is not an isolated reason to recall for further imaging if the remaining anatomy is well visualised and normal.

Head

- Nuchal fold measurement (measure in the plane of the cavum septum pellucidum (CSP), normal is ≤ 6 mm)
- Cerebral ventricles (measure lateral ventricle at atrium, normal ≤ 10 mm)
- Choroid plexus
- CSP and falx
- Cerebellum/vermis
- Cisterna magna (normal ≤ 10 mm)
- Calvarium
- *Sagittal corpus collosum**
- *Sagittal vermis**.

Face

- Orbits + lenses
- Nose/lips (coronal)
- Profile showing nasal bone and mandible
- *Alveolar ridge**
- *Uvula / soft palate**.

Abdomen

- Stomach (situs)
- Kidneys in two planes (transverse and longitudinal/coronal images (measure AP pelvis if renal dilatation is suspected)
- Bladder
- Diaphragm (right and left sides, and document organs in relation to the diaphragm)
- Anterior abdominal wall and cord insertion
- Bowel.

Heart

- Situs, cardiac axis, position and size
- 4Ch heart and transverse view of the interventricular septum
- Outflow tracts: left/right ventricular outflow tract (LVOT and RVOT respectively)
- Three vessel and trachea (3VT) view / arrow view
- Assess fetal heart rate and rhythm (Note: Document M-mode if there is an abnormality of the heart rate or rhythm.)
- An axial sweep cine from stomach to outflow tracts is extremely helpful for offline review and when referring a suspected anomaly.

Include both colour and non-colour imaging on all heart views.

For more information, see the **NZMFMN and ASUM guidelines on fetal heart assessment during the 18–20 week anatomy scan** (Necas and Bagnall 2014).

The following **extended cardiac views** should be considered in case of suspected anomaly, if the operator is experienced in cardiac assessment.

- *Ductal arch and aortic arch**
- *Superior/inferior vena cava* (SVC/IVC respectively)*
- *Pulmonary veins**
- *Foramen ovale**
- *Pulmonary arteries**
- *Thymus**
- *Atrioventricular (AV) valves**
- *Ductus venosus**
- *Abdominal aorta and IVC* (for determination of situs).*

If cardiac anomaly is suspected, prompt referral for fetal echocardiography is required.

For further information on the most common cardiac anomalies, see **Cardiac anomalies** below.

Spine

Assess in three planes (sagittal, coronal and transverse, including skin line and sacrum). Two planes may be acceptable in suboptimal fetal position, but visualisation must be excellent.

Umbilical cord

- Cord insertion: both fetal and placental – see **Appendix 6: Placental anomalies**
- Three-vessel cord.

Extremities

- Document all long bones
- Arms (upper arm and forearm)
- Hands observed open/parallel digits
- Fingers counted
- Legs (upper leg and lower leg)
- Feet/ankles.

Soft markers

The following sonographic findings previously referred to as soft markers are not significant and should not be reported if they are an isolated finding but should prompt careful review of the rest of the fetal anatomy.

- Choroid plexus cyst
- Echogenic cardiac focus
- Single umbilical artery
- Sandal gap toes
- Clinodactyly.

More than two soft markers should be discussed with the referrer for consideration of Fetal Medicine or local equivalent specialist review.

For more information, see the article **Meta-analysis of second-trimester markers for trisomy 21** (Agathokleous et al 2013).

Markers that should be reported and may be indicative of an increased risk of chromosomal abnormality, requiring specialist review, include:

- **increased nuchal fold thickness >6 mm** (see below)
- absent or hypoplastic nasal bone
- ventriculomegaly >10 mm (see **Fetal Ventriculomegaly**, NZMFMN 2010)
- persisting clenched hand
- rocker bottom foot
- echogenic or thick-walled bowel (echogenicity greater than or equal to bone – see **Fetal Echogenic Bowel**, NZMFMN 2015c)
- pleural fluid or ascites
- **pericardial fluid (>2 mm thickness)** (see below)
- **perimembranous VSD** (see below)
- *aberrant right subclavian artery**.

Reporting guide and recommendations

Minimum reporting requirements

- Dating information by previous scan if available (see **Second-trimester dating** above)
- Fetal biometry
- **Placenta** (see below): location and distance of the lower placental margin/marginal sinus from the internal cervical os
- Amniotic fluid: subjective assessment
- Fetal anatomy (with structures as per **Ultrasound examination** above)
- Maternal adnexa
- Documentation of uterine fibroids
- Cervical length, if appropriate (see **Cervical length screening** above)
- **Uterine artery Doppler** (see below), if appropriate.

See **Anatomy scan reporting pro forma** below.

Where any fetal anomaly is suspected, the sonographer should inform the reporting radiologist, who must be available to review the images while the woman is in the scanning facility (Section 88 requirement).

For cases of confirmed or suspected fetal anomaly, the radiologist should contact the referring lead maternity carer (LMC) to discuss referral to Fetal Medicine or local equivalent specialist.

A copy of the report and images should be available for review at the appropriate DHB.

If, after two separate attempts, the anatomy scan remains incomplete, with required structures not visualised, then it should be reported as incomplete. If local services allow, a tertiary referral for completion may be available.

Fetal abnormalities that require specialist referral include:

- **cardiac abnormality** (see below)
- skeletal dysplasia (see **Lethal Skeletal Dysplasia**, NZMFMN 2015e)
- neural tube defect
- brain abnormalities
- cleft lip/palate (see **Cleft Lip/Palate**, NZMFMN 2011a)
- abdominal wall defects (see **Gastroschisis**, NZMFMN 2015d)
- congenital diaphragmatic hernia (see **Congenital Diaphragmatic Hernia**, NZMFMN 2015a)
- hydrops (see **Nonimmune Hydrops Fetalis**, NZMFMN 2012)
- abnormal limb position / akinesia
- genitourinary abnormalities.

Other findings that may indicate underlying abnormality and for which specialist referral is recommended include:

- **persistent / absent small stomach** (see below)
- megacystis
- renal dilatation – see **Appendix 7: Fetal renal tract dilation charts**⁴
- umbilical vein varix >9 mm (see *Umbilical Vein Varix*, NZMFMN 2017).

Nuchal fold thickness

- When increased (>6 mm), this is a hard marker for chromosomal abnormality.
- It should only be assessed between 16 and 21+6 weeks gestational age.
- Take care to avoid 'drop-out' artefact caused by shadowing from the posterior calvarium (angle the probe so that the posterior fossa and nuchal fold are slightly anterior rather than in the transverse plane on the image).
- A Fetal Medicine (or local equivalent) specialist review should be recommended for nuchal fold thickness of >6 mm.
- Careful examination for further anomalies should be performed.

Fetal pericardial fluid

- Greater than 2 mm fluid around a significant proportion of the heart (generally not more than one isolated pocket) may reflect an increased risk of chromosomal abnormality.
- If isolated, <3 mm and with a normal detailed fetal echo, there is usually a normal outcome.

Ultrasound examination

Measurement of the pericardial fluid should be made in diastole (with the AV valves open).

Mimics: the outer myocardium may be hypoechoic and may mimic pericardial fluid.

Extended ultrasound examination should only be performed by individuals with sufficient clinical expertise. Referral to Fetal Medicine should be recommended if appropriate.

⁴ To view the fetal renal tract dilation charts at source, see: <https://media.starship.org.nz/renal-tract-dilation-flow-chart/renal-tract-dilation-flow-chart.pdf>

Further evaluation may include:

- detailed fetal cardiac scan
- assessment for other features of aneuploidy
- assessment for other signs of hydrops (pleural effusions, ascites, subcutaneous oedema)
- assessment of the placenta for placentomegaly
- assessment for polyhydramnios
- middle cerebral artery (MCA) peak systolic velocity (PSV) to exclude fetal anaemia (such as maternal rhesus disease or parvovirus infection)
- features of fetal growth restriction (FGR)
- toxoplasmosis, other (syphilis, varicella-zoster, parvovirus B19), rubella, cytomegalovirus – CMV – and herpes infections (TORCH)
- high-output shunt lesions, for example, placental chorioangioma, vein of Galen aneurysm, tumours.

Persistent small stomach

- May indicate an increased risk of chromosomal abnormality.
- It can also be seen in non-chromosomal structural fetal abnormalities, such as, oesophageal atresia and trachea-oesophageal fistula.
- Extended ultrasound examination should be performed to look for other markers of chromosomal anomaly, to exclude a structural abnormality of the fetal face and brain and to assess amniotic fluid to exclude secondary polyhydramnios.
- A follow-up scan within a week should be considered. If this is a persistent finding, Fetal Medicine referral (or local equivalent) is required.

Talipes/Clubfoot

- May be a marker for aneuploidy if bilateral, in particular trisomy 18.
- May also be found in non-chromosomal structural fetal abnormalities, such as sacral agenesis, spina bifida, arthrogryposis and caudal regression syndrome.
- Fetal Medicine referral (or local equivalent) is required, even if isolated.

Reporting alerts

- Open cervix ± bulging membranes

- Fetal hydrops
- Major structural fetal anomaly
- Unexpected fetal demise

- Significant fetal anomaly
- Suspicion of chromosomal anomaly
- Fetal biometry <5th centile
- Significant oligohydramnios
- Short cervix <25 mm.

Placenta

Ultrasound examination

- Document placental location, for example, anterior, posterior, fundal.
- Ask about any previous caesarean section and document placental location in relation to the scar.
- Image in transverse and longitudinal planes.
- Measure distance of the lower placental margin/marginal sinus from the internal os. Consider a TV scan if the lower margin cannot be well visualised in relation to the internal os.
- A full bladder can simulate low-lying placenta; if in doubt, get the woman to empty her bladder.
- Less than 20 mm is considered low lying. Third-trimester follow-up is recommended.
- Assess placental cord insertion and location.
- In case of **velamentous cord insertion**, **placenta previa** or **succenturiate lobe**, careful assessment of the internal os is required with colour Doppler, with a low threshold for TV imaging, to exclude **vasa previa**.

Placental anomalies

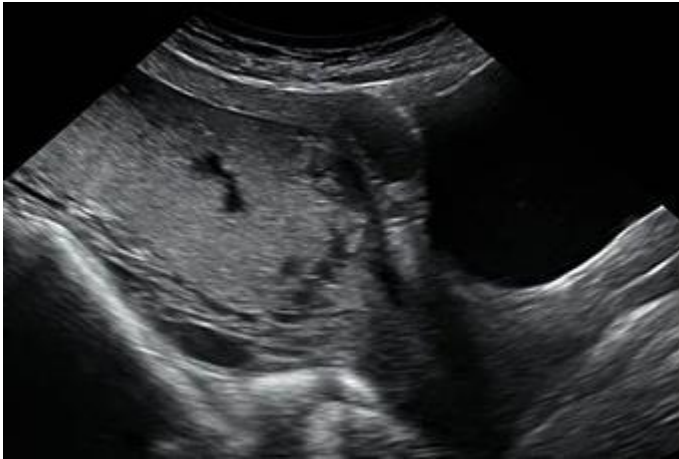- **Placenta previa / low-lying placenta** (see below)
- **Velamentous cord insertion** – see Appendix 6: Placental anomalies
- **Marginal cord insertion** – see Appendix 6: Placental anomalies
- **Succenturiate lobe** – see Appendix 6: Placental anomalies
- **Vasa previa** (see below)
- **Suspected placenta accreta** (see below)
- **Placental mass, for example, chorioangioma** – see Appendix 6: Placental anomalies.

Low-lying placenta and placenta previa

The placenta is inserted wholly or partially into the lower segment of the uterus. Terms used to describe types of placenta previa include:

- complete placenta previa – the placenta completely covers the internal cervical os
- partial placenta previa – the placenta is partly over the cervix
- marginal previa – the placenta is near the edge of the cervix
- low-lying placenta – the placenta/marginal sinus is 20 mm or less from the internal cervical os.

Image 3



Complete placenta previa.

Vasa previa

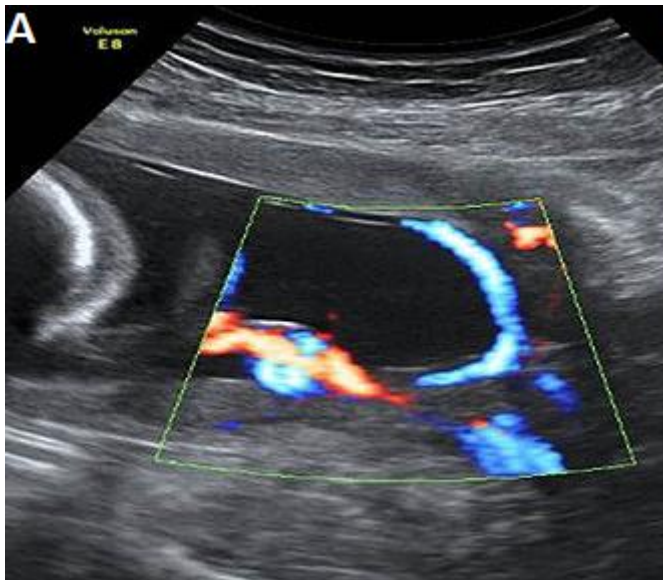
Vasa previa occurs when exposed fetal vessels within the amniotic membranes cover, or are within 20 mm of, the internal cervical os.

This is a clinically significant condition as the vessels are from the fetoplacental circulation, and rupture will lead to rapid fetal exsanguination and death.

There are two types of vasa previa.

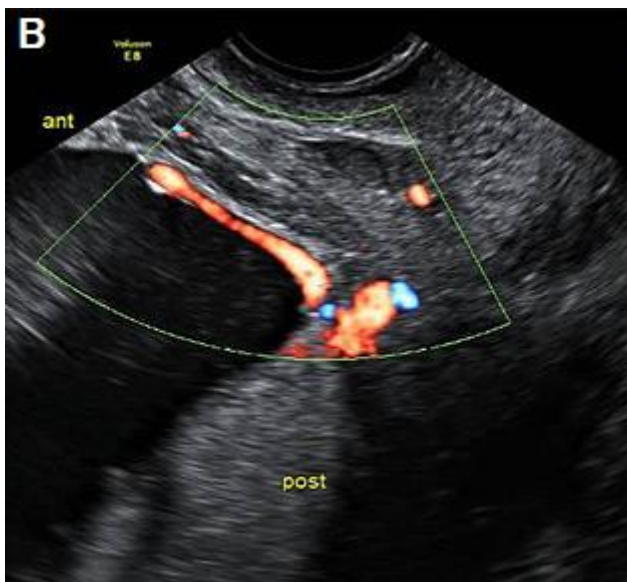
- Type I occurs with velamentous insertion of the umbilical cord into the placenta.
- Type II occurs with velamentous fetal vessels connecting the placenta to a succenturiate placental lobe.

Image 4



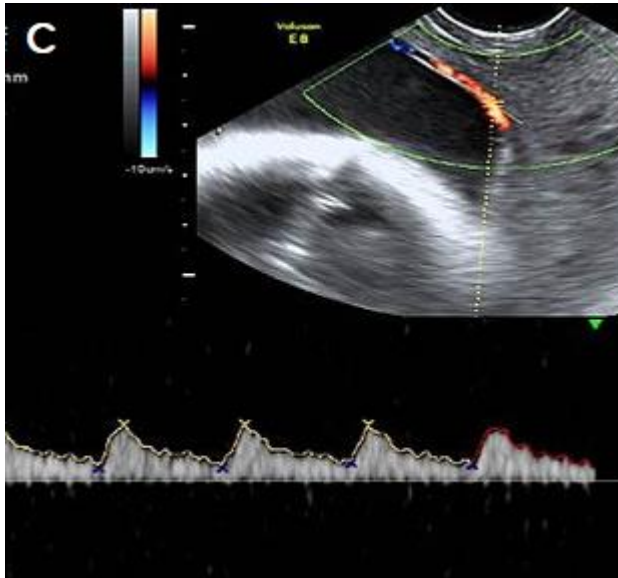
Type I vasa previa, with a velamentous cord insertion and vessels coursing over the internal os.

Image 5



Type II vasa previa, with vessels coursing over the cervix between the main posterior placental lobe and a smaller anterior succenturiate lobe.

Image 6



Pulsed Doppler showing a fetal arterial waveform in the vessels crossing the cervix.

For more detail, see The Royal Australian and New Zealand College of Obstetricians and Gynaecologists (RANZCOG) statement *Vasa Praevia* (RANZCOG 2016).

Reporting guide and recommendations

If a **low-lying placenta and/or placenta previa** (see above) is found at the anatomy scan, recommend follow-up at approximately 32 weeks gestation, which may include a TV scan.

If there is evidence of **vasa previa** (see above) at the anatomy scan, report the finding and recommend specialist review and follow-up scans.

Placenta accreta / abnormally invasive placenta

Placenta accreta / abnormally invasive placenta (AIP) is a disorder of placental implantation where there is invasion of placental tissue into the uterine wall. It is associated with a high risk of maternal and fetal morbidity and mortality.

Careful assessment is recommended with women who have had a previous caesarean section where the placenta overlies the scar, and if there are any concerns, tertiary opinion is recommended.

Traditionally, the extent may be mild, moderate or severe. However, this can be difficult to assess accurately on ultrasound.

- Accreta – placental extension through the thinned decidua basalis without myometrial invasion
- Increta – invasion into the myometrium
- Percreta – invasion through the myometrium with breach of the serosa, with or without invasion into adjacent structures, for example, into the bladder.

The most common risk factors are a previous caesarean section and **placenta previa** (see above).

Features of abnormal placental implantation include:

- irregular placental lakes/lacunae
- focal bulging of the placenta
- abnormal myometrial-bladder wall interface
- loss of retroplacental hypoechoic space
- disordered vascularity.

For first-trimester features, see **Appendix 2: Low gestational sac in the first trimester with previous caesarean section**.

Required clinical details

- Parity
- Number of previous caesarean sections
- Number of classical caesarean sections
- Number of previous surgical evacuations (including termination of pregnancy, TOP)
- Previous uterine surgery (eg, myomectomy, endometrial ablation)
- Past history of accreta/AIP.

Ultrasound features

Greyscale features

- **Loss of clear zone** – loss or irregularity of the hypoechoic retroplacental ‘clear’ zone in the myometrium underneath the placental bed.
- **Myometrial thinning** overlying the placenta to <1 mm, or undetectable.
- **Abnormal placental lacunae** – often numerous, including some that are large and irregular, often containing turbulent flow visible on greyscale imaging.
- **Bladder wall interruption** – loss or interruption of the echogenic bladder wall between the uterine serosa and the bladder lumen.

- **Placental bulge** – deviation of the uterine serosa away from the expected plane, caused by abnormal bulge of placental tissue into a neighbouring structure, typically the bladder. The uterine serosa appears intact, but the outline is distorted.
- **Focal exophytic mass** – placental tissue is evident breaking through the uterine serosa and extending beyond it. This is most often seen within the filled bladder.

Colour Doppler ultrasound features

- **Uterovesical hypervascularity** – striking colour Doppler flow between the myometrium and posterior wall of the bladder.
- **Subplacental hypervascularity** – striking colour Doppler flow within the placental bed.
- **Bridging vessels** – vessels extending from the placenta, across the myometrium ± beyond the serosa into the bladder or other organs; these often course perpendicular to the myometrium.
- **Placental lacunae feeder vessels** – vessels with high-velocity blood flow leading from the myometrium into the placental lacunae, with turbulence.
- **Parametrial involvement** – suspicion of invasion into the parametrium.

Ultrasound examination

- The lower segment of the uterus should be carefully assessed for possible placenta accreta at the anatomy scan in women who have had previous caesarean sections, placenta previa or both, particularly if the placenta is anterior.
- Pay particular attention to the anterior uterine wall-bladder wall interface.
- Assess with a combination of TV and TA scan with a high-frequency transducer, such as a linear array.
- Consider TV scan with the bladder partially full to provide an interface with the myometrium.
- Longitudinal and transverse images (without and with colour Doppler).
- Assess for above features of AIP.

For more detail, see:

1. **FIGO consensus guidelines on placenta accreta spectrum disorders: Prenatal diagnosis and screening** (Jauniaux et al 2018)
2. **Proposal for standardized ultrasound descriptors of abnormally invasive placenta (AIP)** (Collins et al 2016)
3. **Pro forma for ultrasound reporting in suspected abnormally invasive placenta (AIP): an international consensus** (Alfirevic et al 2016).

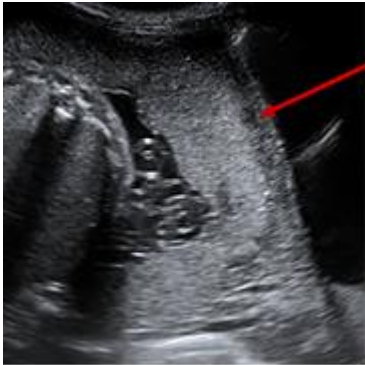
Reporting guide

- Report placental location (anterior, posterior) and distance from os.
- Report suspicious ultrasound findings (as at **Ultrasound features** above).

Recommendations

If there are features suspicious for placenta accreta at the anatomy scan, recommend specialist referral and follow-up detailed scan.

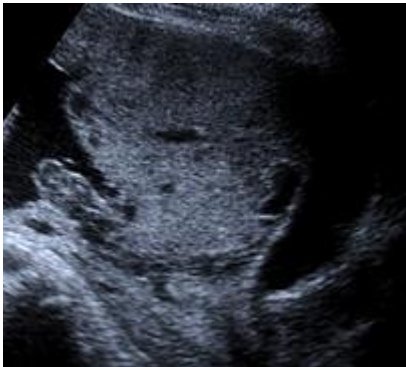Image 7



Normal retroplacental hypoechoic space (decidua basalis)

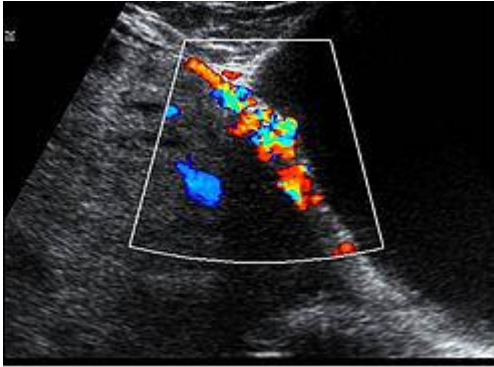
Sagittal view lower uterine segment and bladder (TA)
Complete placenta previa
Normal 'clear zone' retroplacental hypoechoic space
No lacunae
No evidence of placenta accreta on greyscale imaging.

Image 8



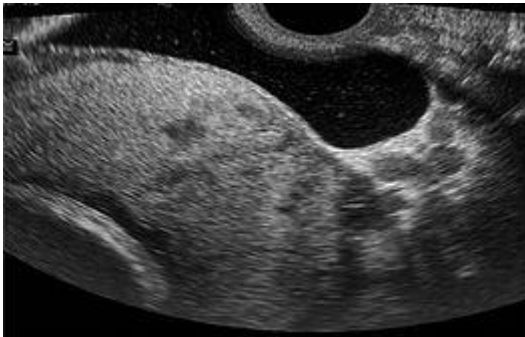
Sagittal anterior lower uterus and bladder (TA)
Complete placenta previa
Loss of clear zone (retroplacental hypoechoic space)
Irregular large lacunae
Placental bulge into bladder
Highly suspicious for placenta accreta on greyscale imaging.

Image 9



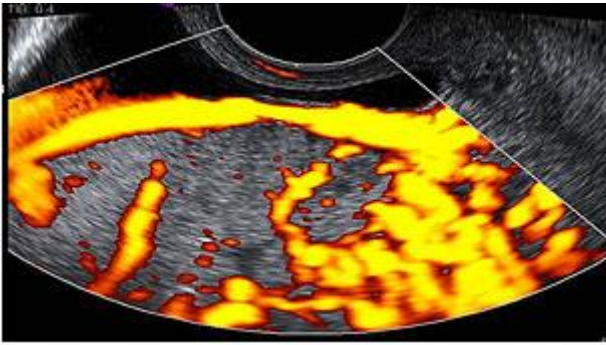
Sagittal anterior lower uterus and bladder TA with colour Doppler
Loss of clear zone
Irregular lacunae
Uterovesical hypervascularity
Subplacental hypervascularity
Bridging vessels
Suspicion of focal exophytic vascular mass into the bladder
Highly suspicious for placenta accreta on colour Doppler imaging.

Image 10



Lower uterine segment and bladder TV with bladder partially filled
Complete placenta previa
Loss of clear zone
Placental bulge
Placental lacunae
Highly suspicious for placenta accreta on greyscale imaging.

Image 11



Lower uterine segment and partially filled bladder TV with power Doppler

Complete placenta previa

Loss of clear zone

Marked placental bed hypervascularity

Placental lacunae and feeder vessels

Highly suspicious for placenta accreta on colour Doppler imaging.

Reporting alerts

- Active bleeding in the setting of vasa or placenta previa or accreta.

Fetal echocardiography

An appropriately experienced operator should perform a screening fetal echocardiogram on women at risk of fetal cardiac anomaly, ideally as part of the 19-week anatomy scan.

A diagnostic fetal echocardiogram is a tertiary-level scan, often performed by a maternal fetal medicine (MFM) or paediatric cardiology service and is usually performed to assess a previously identified or suspected cardiac anomaly.

When a fetal cardiac anomaly is suspected on a routine 19-week anatomy scan, the images should be reviewed by an experienced operator, either locally or at a distant tertiary level, depending on local resources.

If cardiac anomaly is likely, the woman should be referred directly to the regional MFM centre for a diagnostic fetal echo.

If cardiac anomaly is unlikely but more certainty is required, a screening echo should be performed, as described below, by an appropriately trained operator.

Indications for detailed fetal echocardiography

- Suspected fetal cardiac abnormality (as above).
- Increased NT ≥ 3.5 mm at the 12+ week scan.
- Previous baby or direct family history of congenital cardiac abnormality.
- Maternal diabetes (insulin-dependent diabetes mellitus, IDDM, non-insulin dependent diabetes mellitus, NIDDM).
- Clinical risk factor for fetal cardiac abnormality, for example, maternal anti-epilepsy medication.

When views are technically suboptimal/limited, a follow-up scan should be booked at around 22–24 weeks.

Ultrasound examination

Cine clips/sweeps are required if images are to be reviewed in Auckland, or if an anomaly is identified.

When using colour Doppler, the region of interest (ROI) should be minimised to maintain a frame rate of >25 Hz. The aliasing velocity should be set at 20–30 cm/s when interrogating venous flow and 50–60 cm/s otherwise.

- Transverse abdomen: document stomach and aorta to left and IVC to right
- Situs
- Apical 4Ch view: document valves open and closed (with and without colour Doppler) and relative sizes of the ventricles
- 4Ch view transverse: interventricular septum (IVS) long and short axis, with and without colour
- Foramen ovale: colour view to show right-to-left flow
- Pulmonary veins: at least one left and one right seen entering left atrium, with colour
- LVOT: measure at aortic valve, non-colour and colour views
- RVOT: measure at pulmonary valve, non-colour and colour views
- RVOT and pulmonary arteries: measure both left and right proximal pulmonary artery (PA) diameters, plus colour views
- 3VT / arrow view: non-colour and colour view, showing aorta to the left (or right) of the trachea. Measure isthmus and obtain pulsed wave Doppler in the isthmus if small
- Assess aortic arch branching vessels and detect an aberrant origin of a subclavian artery if present, using colour Doppler
- IVC and SVC: colour views in long axis draining into right atrium
- Aortic arch: long axis without and with colour and showing cranial vessels
- Ductal arch: long or short axis with and without colour
- Ductus venosus
- Thymus gland
- Cardiac rate and rhythm
- Pericardial fluid >2 mm.

Cine clips or sweeps if external review is likely to be required, which may include:

- cine loop sweep from abdomen to the atria to assess for abdominal and atrial situs
- cine loop assessment of 4Ch heart view for assessment of relative size of ventricles, ventricular function, AV valve function (with and without colour) and to rule out VSDs (septum to outlet)
- cine loop sweeps from 4Ch view to outflow of great vessels, showing relationship of ventricle to great vessel and great vessel valves

- cine loop sweeps from 4Ch view to 3VT / arrow views (with and without colour)
- cine loop sweep of short axis of ventricles (with colour) to assess for VSD
- cine loop sweep of ductal and aortic arches (with and without colour).

These are the minimum cine clips required for fetal cardiology review; more should be done if required to illustrate pathology.

Fetal arrhythmia

An irregular cardiac rhythm is frequently observed and is predominantly benign in the second trimester, due to premature atrial contractions. This can be documented by M-mode on the atria and ventricle.

A sustained bradycardia (<110 bpm) or tachycardia (>180 bpm) requires referral.

Fetal arrhythmia with reduced fetal movements, hydrops, reduced observed fetal activity or other evidence of fetal compromise requires urgent referral.

For further information, see **Fetal Arrhythmia** (NZMFMN 2015b).

Isolated muscular VSD

Small isolated muscular VSDs are common and usually have an excellent prognosis, with most spontaneously resolving later in pregnancy or in early neonatal life.

Recommend specialist review and diagnostic echo.

Perimembranous VSD

Recommend specialist review and diagnostic echo.

Common cardiac anomalies

See **Cardiac anomalies** below for further information.

Reporting guide and recommendations

Minimum reporting requirements

- Clinical indication for the scan
- General pregnancy information, for example, dating information
- Cardiac anatomy assessment, and any limitations / anatomy incompletely visualised
- Abnormal cardiac findings and suspected diagnosis if appropriate.

Any cases of suspected cardiac anomaly should be referred for specialist review and diagnostic echo.

When the examination is incomplete, recommend a follow-up scan at 22–24 weeks if there is no suspected anomaly; otherwise prompt specialist referral is required.

Reporting alerts

- Fetal arrhythmia with reduced fetal movements, hydrops, reduced observed fetal activity or other evidence of fetal compromise (requires urgent referral)
- Suspected cardiac anomaly.

Anatomy scan reporting pro forma

Normal anatomy scan

Clinical

Routine anatomy scan

EDD by earliest ultrasound at [] weeks: []

Gestational age: [] weeks [] days \pm [7] days.

Findings

Anatomy scan:

Fetal measurements:

Biparietal diameter (BPD) [] mm

Head circumference (HC) [] mm

Abdominal circumference (AC) [] mm

Femur length (FL) [] mm

Nuchal fold [] mm.

Cardiac activity present

Normal fetal movements

Amniotic fluid: normal

Cord: 3 vessels

Placenta: [anterior/posterior/fundal], [not low lying].

Fetal anatomy:

The following were visualised and appear normal:

Head, brain, face, spine, heart (4Ch view and great vessels), diaphragm, stomach, abdominal wall, kidneys and bladder, limbs.

No maternal adnexal abnormality.

Comment

Normal anatomy scan.

Report conclusions

Incomplete anatomy scan

Incomplete anatomy scan.

Visualisation of the fetal [] was limited by [fetal position/maternal habitus, etc]. A follow-up scan has been arranged for [date].

Technically difficult but grossly normal scan

Technically difficult scan due to [maternal habitus, etc]. Allowing for this, no fetal anomaly has been identified.

Low-lying placenta

Normal fetal anatomy.

The placenta is low lying. The lower placental margin is [] mm from the internal cervical os. A follow-up scan is recommended at 32 weeks.

Fetal demise

Unfortunately, appearances today are those of a fetal demise at [] weeks, [] days by [measurements]. [Woman's name] is aware, and the results have been telephoned to [referrer's name]. (Please document other relevant findings such as fetal anomaly.)

Cervical length screening (in a high-risk woman)

The cervix measures [] mm and appears normal without funnelling.

The cervix is short, measuring [] mm, without evidence of funnelling. Follow-up scan and specialist opinion is recommended.

The cervix is short, measuring [] mm, with funnelling. Results have been telephoned to [referrer's name].

The cervix is completely open, with membranes bulging into the lower cervix/vagina. Results have been telephoned to [referrer's name].

Renal dilatation

There is [right/left/bilateral] renal pelvic dilatation, [with/without] peripheral calyceal dilatation (Grade A1/A2/A3). A follow-up scan is recommended at 32 weeks.

See **Appendix 7: Fetal renal tract dilation charts.**⁵

⁵ To view the fetal renal tract dilation charts at source, see: <https://media.starship.org.nz/renal-tract-dilation-flow-chart/renal-tract-dilation-flow-chart.pdf>

Monochorionic-diamniotic twin pregnancy

Monochorionic-diamniotic twin pregnancy, [] weeks, [] days by [earliest scan].
Fortnightly scans to screen for twin-twin transfusion syndrome are recommended from 16 weeks.

Isolated muscular VSD

Isolated muscular VSD, [] mm. Specialist review and detailed fetal echocardiogram is recommended.

Isolated peri-membranous VSD

Isolated peri-membranous VSD, [] mm. Specialist review and detailed fetal echocardiogram is recommended.

Cardiac anomalies

The most common cardiac anomalies are summarised in this section.

The main reference source for this section is *A Practical Guide to Fetal Echocardiography: Normal and abnormal hearts* (Abuhamad and Chaoui 2015). For more detail, please refer to this guide or another fetal echocardiography text.

Ventricular septal defects

- VSDs are the most commonly prenatally-detected cardiac anomaly.
- A VSD is an opening in the ventricular septum, leading to a shunt between the two ventricles.
- VSDs (particularly perimembranous) are frequently associated with other cardiac anomalies, particularly conotruncal anomalies. Identification of a VSD should prompt careful review of the heart.
- If isolated, the majority close within the first year of life.

VSDs are usually classified by their location. The most common VSDs identified prenatally are muscular and perimembranous.

VSDs may also be outlet or inlet in location. For more information, see **Appendix 8: Anatomic locations of ventricular septal defects.**

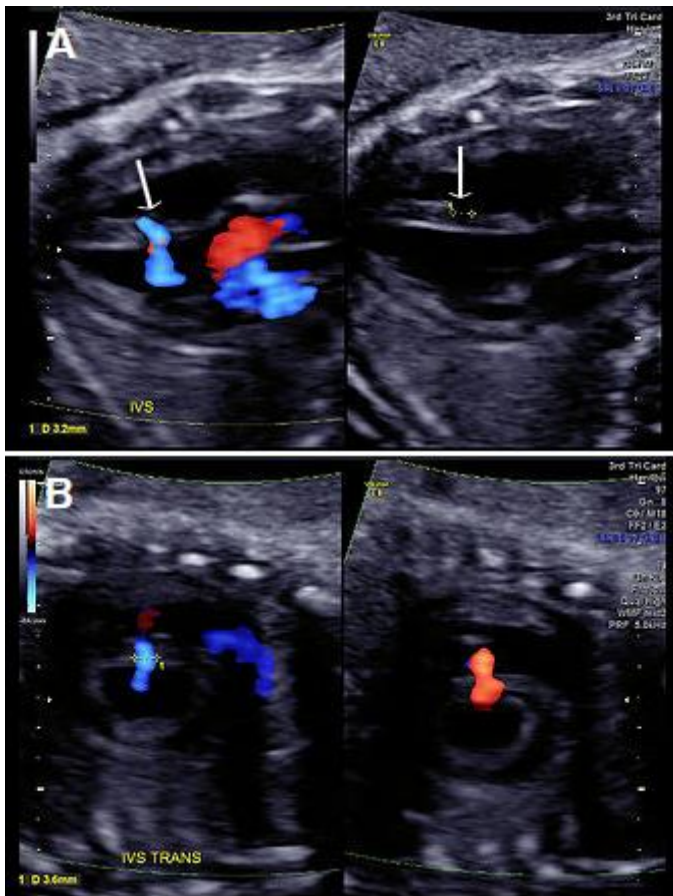
1 Perimembranous VSD

- Perimembranous VSDs are located in the outflow tract beneath the aortic valve.
- They are the most common type of VSD postnatally but may be more difficult to detect prenatally than muscular VSD.
- On greyscale imaging, the VSD is best visualised in the LVOT view, with loss of continuity of the ventricular septum and aorta.
- Colour Doppler may identify VSDs not visualised on 2D imaging.
- Perimembranous VSD can be associated with chromosome abnormality and requires Fetal Medicine review.

2 Muscular VSD

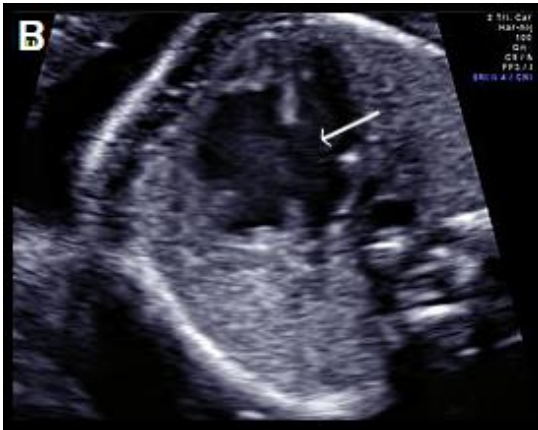- Located in the muscular septum; may be mid-muscular, apical or multiple ('Swiss cheese' septum)
- Account for 10–15 percent of VSDs, but muscular VSDs are the most commonly-detected VSD prenatally
- Frequently close spontaneously
- Approximately 3 percent recurrence risk to siblings
- Rarely visualised on greyscale imaging unless large (>2–3 mm)
- Best identified in the apical or transverse 4Ch view
- The borders of the VSD often appear echogenic (unlike the dropout artefact commonly seen on the apex-up 4Ch view)
- Most easily visualised with colour Doppler, with bi-directional shunt in most cases
- Most common location is the apex or mid septum
- If isolated, muscular VSD is usually benign and not associated with chromosomal anomaly.

Image 15



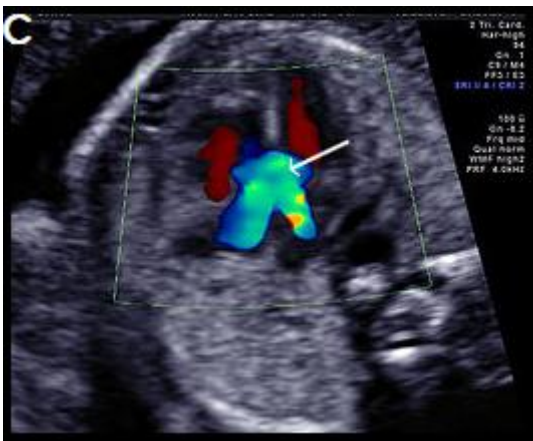
(A) Muscular VSD (arrow) on colour Doppler and greyscale imaging in the transverse long-axis IVS plane (arrows) and **(B)** in the transverse short-axis IVS plane with colour Doppler, showing bi-directional flow.

Image 17



Complete AVSD with common AV valve in diastole (valve open) with a large central defect (arrow).

Image 18



Complete AVSD with colour Doppler filling the large central defect and common valve regurgitation (arrow).

Other atrial septal defects

- Atrial septal defects (ASDs) are rarely detected prenatally and often not detectable until birth.
- Defined as an abnormal opening of the atrial septum, with communication between the left and right atria.
- Common: in approximately 7 percent of infants with congenital cardiac abnormalities.
- Incidence: about 1:1,500 live births.
- When detected prenatally, careful cardiac review for associated anomalies is required (including AVSD, isomerism, anomalous pulmonary venous drainage and aortic coarctation).
- Beware diagnosing an ASD when a persistent left SVC is present. Assess with colour Doppler for left-to-right shunting due to a dilated coronary sinus.
- In the third trimester, the foramen ovale flap may appear redundant ('aneurysm of the foramen ovale'), a normal variant that should not be confused with an ASD.

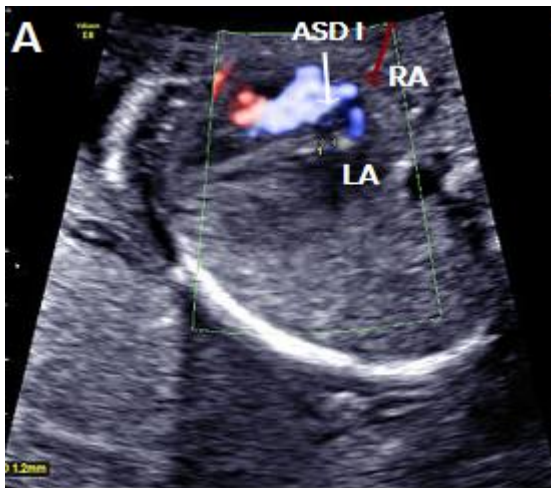Classified according to embryonic origin and location as:

1. Septum primum ASD (ASD I)
2. Septum secundum ASD (ASD II)
3. Sinus venosus ASD – rare and difficult to detect prenatally
4. Coronary sinus defect – rare and difficult to detect prenatally.

1 Septum primum (ASD I)

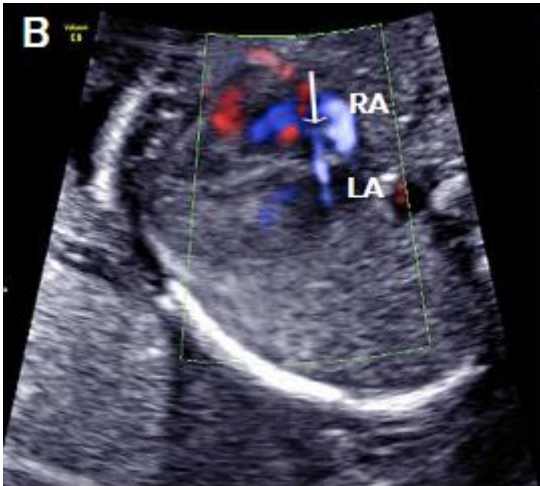
- Also known as partial AVSD.
- Second most common type of ASD (after secundum).
- Characterised by a gap in the embryologic septum primum, adjacent to both AV valves.
- Commonly associated with aneuploidies, such as trisomy 21.
- Can be detected prenatally as a gap in the septum primum, often associated with lack of the normal offsetting (linear insertion) of the AV valves (as seen with an **AVSD**, see above).
- Colour Doppler may confirm the ASD by demonstrating **right-to-left** shunting of blood across the atrial septum adjacent to the AV valves and separate from the normal foramen ovale.
- **Beware:** The normal or dilated coronary sinus may be mistaken for a septum primum ASD but shows colour Doppler flow from **left to right** into the right atrium.

Image 19



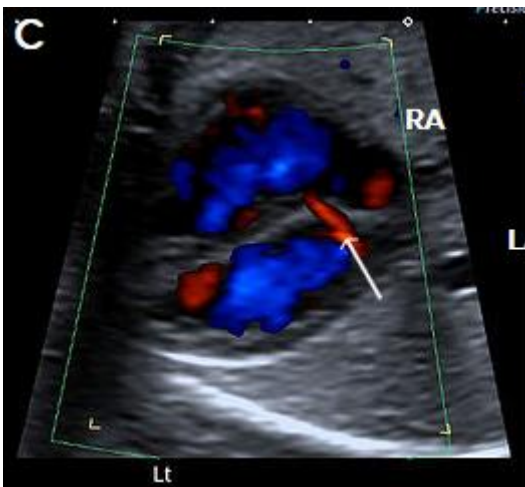
Septum primum ASD (white arrow) shown as a gap in the septum primum separate from the normal foramen ovale with **right-to-left** flow in blue (red arrow).

Image 20



Septum primum ASD (white arrow), with **right-to-left** flow across the atrial septum (blue).

Image 21



Normal coronary sinus (arrow) with **left-to-right** flow (red), which should not be misinterpreted as an ASD.

2 Septum secundum ASD (ASD II)

- Most common: approximately 80 percent of all ASDs but very difficult to identify prenatally.
- Characterised by a lack of tissue in the region of the foramen ovale.
- Associated with partial anomalous venous drainage (in 10–15 percent of cases).
- **Beware:** The redundant foramen ovale flap ('aneurysm of the foramen ovale') is a normal variant of the foramen ovale seen most commonly in the third trimester and should not be mistaken for an ASD.

Tetralogy of Fallot

Tetralogy of Fallot (TOF) is one of the most common forms of cyanotic heart disease, occurring in about 1:3,500 live births. TOF accounts for approximately 5 percent of cases of congenital heart disease.

TOF has three major prenatal components. These are:

1. malaligned (subaortic) VSD
2. overriding aorta (aortic root overrides the VSD)
3. pulmonary stenosis.

The fourth component of the TOF is right ventricular hypertrophy and is usually not identified prenatally.

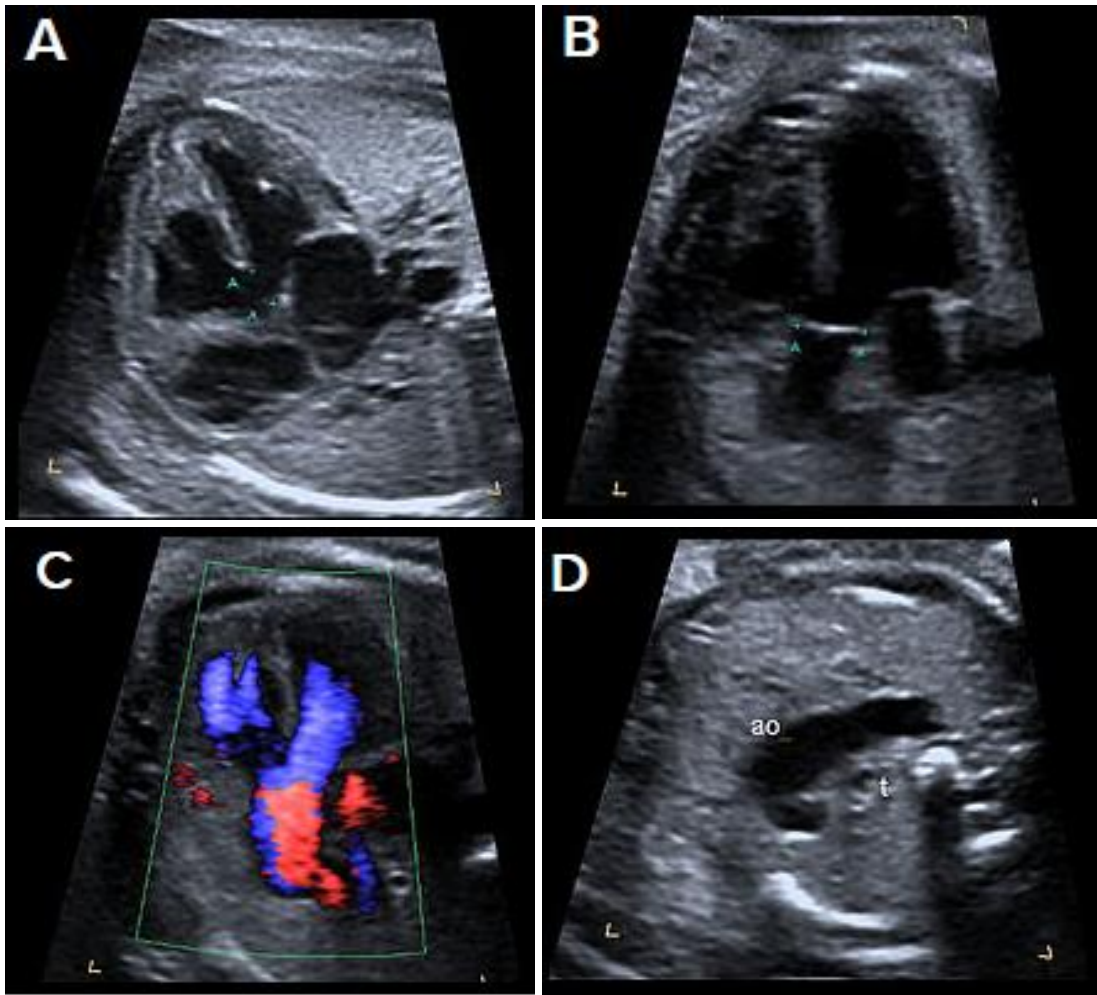
Ultrasound findings

- The 4Ch view will generally appear normal, unless the VSD is large.
- TOF is best identified in the LVOT view as a perimembranous subaortic VSD and overriding aortic root, with discontinuity between the IVS and medial aortic wall (malalignment VSD). The aortic root is slightly aligned to the right, overriding the right ventricle (aortic dextroposition), and is often dilated.
- Pulmonary stenosis is best identified in the 3-vessel or short axis view and may be subtle, particularly in the second trimester. More severe forms are TOF with pulmonary atresia or absent pulmonary valve.
- Doppler is useful in confirming the diagnosis, demonstrating the VSD shunt and the overriding aorta with flow from both ventricles into the aortic root (Y-sign).
- Flow across the ductus arteriosus is antegrade in milder forms of TOF but may be reversed in severe cases.
- Measure branch pulmonary artery calibre.
- Assess for presence of the thymus and right-sided aortic arch – thymic hypoplasia and RAA are associated with DiGeorge syndrome (22q11.2 deletion).

Associations

- Other cardiac abnormalities, such as right-sided aortic arch, aberrant origin of a subclavian artery, AVSD, patent foramen ovale, ASD, persistent left SVC
- Extra-cardiac abnormalities
- Chromosomal abnormality in about 30 percent (particularly when associated with an AVSD) – mainly trisomies 21, 13 and 18, 22q11.2 deletion (10–15 percent)
- Genetic syndromes
- Increased NT.

Image 22



4Ch view (apex up) showing perimembranous VSD (**A**). Overriding, dilated aortic root with perimembranous VSD (**B**) and Y-sign with colour Doppler (blood from both ventricles flowing into the aortic root) on apex-up LVOT view in the same fetus (**C**). On the 3-vessel view only a single large vessel (the aorta) is evident in this case (**D**); colour Doppler may aid in demonstrating a small pulmonary artery.

Transposition of the great arteries

1 Complete transposition of the great arteries

- Complete transposition of the great arteries (D-TGA) is characterised by AV concordance (normally connected atria and ventricles, that is, right atrium to right ventricle, RV, and left atrium to left ventricle, LV).
- Ventriculoarterial discordance (switched connections of the great vessels – the PA arises from the LV and the aorta arises from the RV).
- Relatively common, accounting for approximately 5 percent of congenital cardiac anomalies.

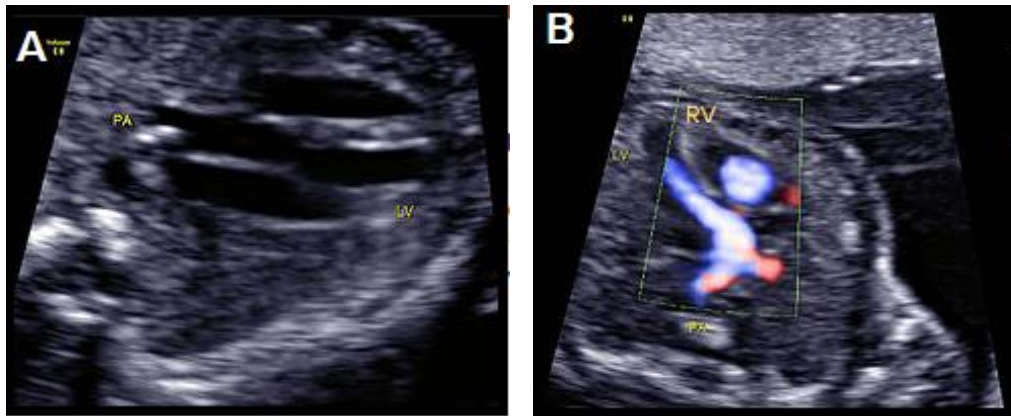
Ultrasound findings

- The 4Ch view is usually normal.
- There is a parallel course of the great vessels, rather than crossing as in the normal situation.
- The aorta is located anterior and to the right of the PA (hence **D**-TGA) and runs parallel to the PA.
- On the LVOT view, the PA arises from the LV and bifurcates shortly after its origin into the branch PAs.
- The normal 3-vessel view cannot be obtained – instead a single large vessel (the transverse aortic arch) is visualised, with the SVC located to its right.
- In the short-axis plane of the great vessels, the PA and aorta are adjacent to each other, rather than the longitudinal PA wrapping around the circular aortic root.
- In the longitudinal plane, the aortic arch, giving rise to the head and neck vessels, arises from the anterior-most RV.
- Colour Doppler may help in confirming the diagnosis, and in assessing for associated anomalies, particularly in early gestation.

Associations

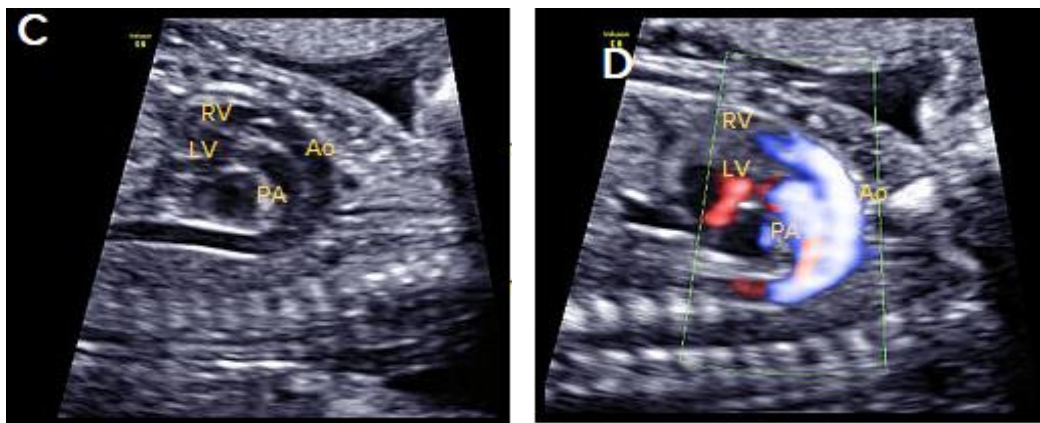
- Other cardiac anomalies, for example, VSD, particularly perimembranous (40 percent of cases), and pulmonary stenosis (most commonly detected in the third trimester).
- D-TGA is often an isolated anomaly, and extra-cardiac anomalies are uncommon.
- Microdeletion of 22q11.2 may be associated with complex D-TGA, especially when there are associated extra-cardiac anomalies.
- Abnormal situs, for example, abdominal situs inversus, which may allow a balanced circulation if there are associated veno-atrial connection anomalies.

Image 23



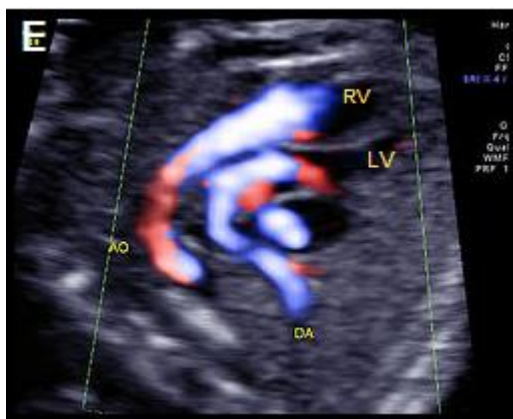D-TGA with ventriculoarterial discordance. The bifurcating PA arises from the LV on the transverse long-axis LVOT plane, in B-mode **(A)** and colour Doppler imaging, apex-up **(B)**.

Image 24



In the longitudinal plane, the aorta (Ao) with head and neck vessels arising from it, arises from the anterior RV, and the PA arises posteriorly from the posterior LV, on B-mode **(C)** and colour Doppler **(D)**.

Image 25



Oblique, apex-up view with colour Doppler showing the aorta arising from the (anterior) RV and the PA arising from the (posterior) LV.

2 Congenitally corrected transposition of the great arteries

Congenitally corrected TGA (cc-TGA) is a rare condition, with both AV and ventriculoarterial discordance (but normal veno-atrial connections).

- The morphologic **right** atrium connects to the morphologic **left** ventricle, and the morphologic **left** atrium connects to the morphologic **right** ventricle.
- The morphologic RV is characterised by the moderator band, more apical attachment of the AV valve, and shorter/triangular configuration. It is located left and posterior in cc-TGA and connects to the left atrium.
- The morphologic LV is located to the right and anterior in cc-TGA, has an elongated and smoother inner chamber and forms the apex of the heart.
- The great vessels are also discordant and transposed with a parallel course (the PA arises from the LV and the aorta from the RV).
- The aorta is anterior and to the left of the PA (hence also known as **L-TGA**).
- The associated AV and ventriculoarterial discordance results in haemodynamic compensation.
- This condition is more commonly associated with other cardiac anomalies than D-TGA (eg, VSD, pulmonary outflow obstruction, tricuspid valve anomalies, dextrocardia and cardiac arrhythmias).
- It is rarely associated with extra-cardiac anomalies or chromosomal anomaly.
- 22q11.2 microdeletion may be associated, particularly when cc-TGA is detected with other cardiac or extra-cardiac anomalies.

Common arterial trunk

Common arterial trunk (CAT) is also known as truncus arteriosus, persistent truncus arteriosus, truncus arteriosus communis and aorticopulmonary trunk. It is:

- characterised by a single ventriculoarterial trunk that gives rise to the pulmonary, systemic and coronary vessels
- almost always associated with a large VSD
- relatively uncommon, representing about 1 percent of congenital heart disease.

It may be classified into the following four types by the origin of the PAs, but this may be difficult prenatally.

1. A short pulmonary trunk arises from the common arterial trunk and divides into right and left PAs.
2. The PAs arise separately from the common arterial trunk, close to each other.
3. The PAs arise separately from the common arterial trunk, distant from each other.
4. The PAs arise from the aortic arch or descending aorta rather than from the common arterial trunk (recently reclassified as pulmonary atresia with VSD).

A dysplastic truncal valve is common.

Ultrasound findings

- The 4Ch view is often normal, unless there is a large VSD.
- CAT is best visualised on the LVOT view where a malaligned VSD and large overriding vessel is evident.
- A single large vessel is identified on scanning in the 3VT plane.
- The PA cannot be identified arising from the RV.
- The pulmonary trunk or branch PAs may be identified arising from the large overriding vessel.
- Colour Doppler may help in identifying the location of the PAs, demonstrating the VSD shunt and showing CAT valvular regurgitation.

Associations

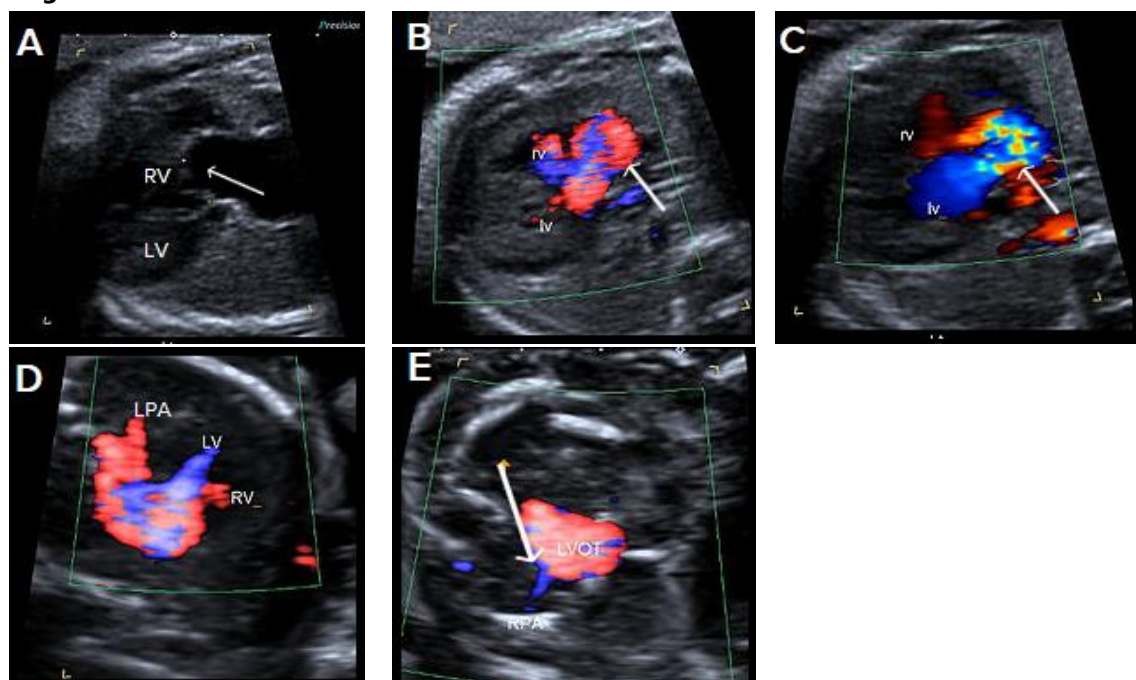
The following cardiac anomalies are commonly associated.

- Perimembranous VSD is almost always identified
- The ductus arteriosus is absent in 50 percent of CAT cases
- Aortic arch abnormalities are common (right-sided aortic arch, interrupted arch and, less commonly, arch hypoplasia and double aortic arch)
- One PA is absent.

Extra-cardiac structural anomalies are present in about 40 percent of CAT cases.

Chromosomal anomalies are common, and include trisomies 21, 18 and 13 as well as microdeletion of 22q11.2 (in 30-40 percent of cases).

Image 26



Single large central vessel (arrow) overriding both ventricles on greyscale **(A)** and colour Doppler imaging **(B)**. There is turbulent flow within the common arterial trunk on colour Doppler **(C)**. The left PA **(D)** and right PA, arrow **(E)**, arise separately and distant from each other from the common arterial trunk (type 3 CAT).

Hypoplastic left heart syndrome and critical aortic stenosis

Hypoplastic left heart syndrome (HLHS) comprises a spectrum of congenital anomalies characterised by under-development or absence of the LV and LVOT.

There are varying degrees of hypoplasia of the LV, mitral valve and aortic valve atresia or stenosis, and hypoplasia of the ascending aorta.

Critical aortic stenosis may progress to HLHS.

Ultrasound findings in HLHS

B-mode

- The 4Ch view is abnormal with a variably small LV (absent, small or sometimes dilated), with reduced contractility and increased echogenicity of the inner wall due to endocardial fibroelastosis.
- The apex of the heart is predominantly formed by the RV.
- The aortic valve is atretic in most cases.
- The mitral valve is usually patent but may be dysplastic.
- The left atrium is small compared with the right atrium.
- The tricuspid valve may be dysplastic, and there may be tricuspid regurgitation.
- Foramen ovale leaflet motion may be paradoxical (from left to right).
- The LVOT is hypoplastic and may be difficult to visualise in the LVOT view.
- In the 3-vessel view, the pulmonary trunk appears dilated, and the aortic arch may be absent or hypoplastic.

Colour Doppler

- There is abnormal or absent filling of the hypoplastic LV and paradoxical left-to-right shunting across the foramen ovale.
- There is a lack of forward flow across the atretic aortic valve.
- There is an abnormal 3-vessel view, with antegrade flow within the dilated pulmonary trunk and reversed flow in the narrowed aortic arch.
- Retrograde flow is evident from the ductus arteriosus into the aortic isthmus.

Ultrasound findings in critical aortic stenosis

B-mode

- The LV is often abnormally dilated, with reduced function and increased echogenicity of the inner wall due to endocardial fibroelastosis.
- The dilated LV may still form the apex of the heart in this condition.
- The left atrium may also be dilated because of mitral valve regurgitation.
- The aortic root appears narrow on the LVOT view, and there may be reduced valvular motion.

Colour Doppler

- There may be evidence of mitral regurgitation.
- In severe cases, there may be reduced left ventricular filling and left-to-right shunting at the foramen ovale.
- Antegrade and often turbulent flow is seen across the severely stenotic but patent aortic valve, with peak velocities often >200 cm/s (however, reduced velocities and aortic regurgitation may also be evident and suggest left ventricular dysfunction).
- On the 3-vessel view, there may be antegrade or retrograde flow within the aortic isthmus, depending on severity.

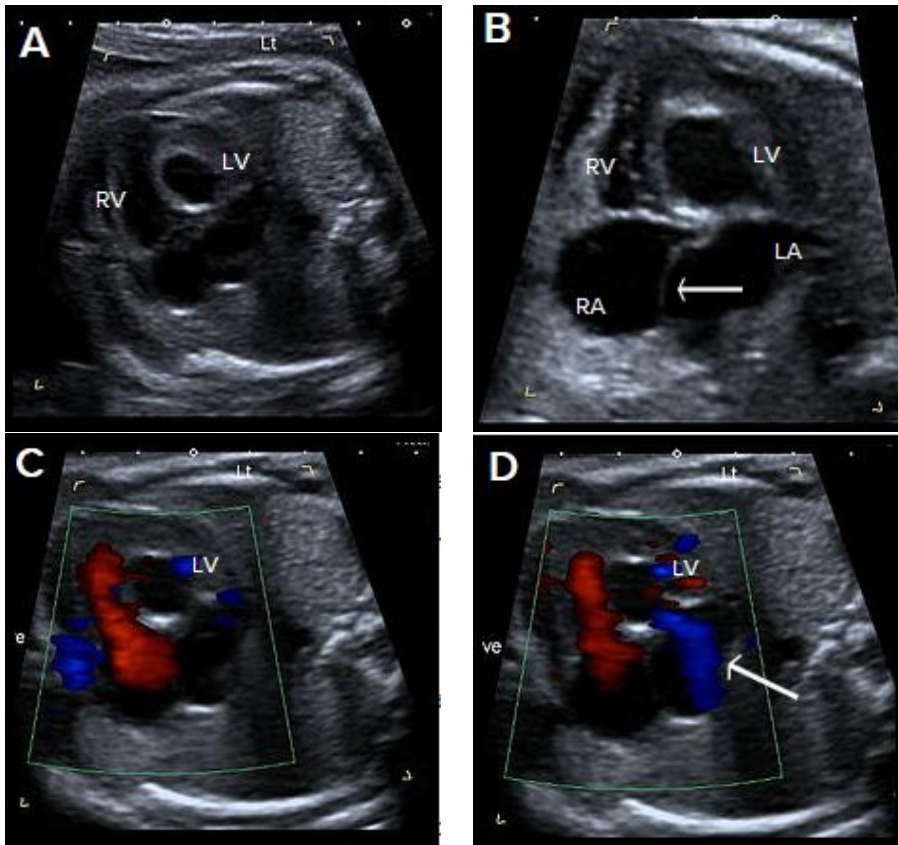
Associations with HLHS

- Chromosomal anomalies can be associated with HLHS (including Turner syndrome and trisomies 13 and 18).
- Extra-cardiac abnormalities are overall less common in HLHS than in other congenital heart disease.
- Risk of recurrence is about 8 percent.
- Intrauterine growth restriction may be associated and is likely due to reduced cardiac output.

Associations with critical aortic stenosis

- Associated cardiac abnormalities are present in about 20 percent of cases and include tricuspid and aortic insufficiency, coarctation of the aorta and postnatal patent ductus arteriosus (PDA).
- Extra-cardiac and chromosomal abnormalities are rarely associated.

Image 27



Abnormal small LV on the 4Ch view with an echogenic inner wall in keeping with endocardial fibroelastosis. The RV forms the apex of the heart (**A**). Paradoxical left-to-right bulge of the foramen ovale flap, arrow (**B**). On colour Doppler imaging, there is minimal left ventricular filling (normal colour filling on the right, in red) (**C**), and mitral regurgitation, arrow (**D**).

Ebstein anomaly

- Ebstein anomaly is characterised by apical displacement of the septal and posterior tricuspid valve leaflets, which are attached to the walls and septum of the RV rather than to the (normally positioned) tricuspid valve annulus.
- This leads to 'atrialisation' of a portion of the morphologic RV, which is contiguous with the right atrium, causing the right atrium to be large and the anatomic RV to be small.
- The anomaly may be mild or severe.
- It is uncommon, accounting for 0.5–1 percent of congenital cardiac anomalies.
- Poor prognostic features include massive cardiomegaly, reduced right ventricular outflow from pulmonary stenosis, hydrops and detection before 20 weeks gestation.

Ultrasound findings

B-mode

- There is cardiomegaly, with right atrial enlargement. This may be subtle in the second trimester, but it may progress later in the pregnancy.
- The septal leaflet of the tricuspid valve may be identified arising more apically than usual from the ventricular wall rather than from the annulus.
- In severe forms, the IVS may demonstrate paradoxical movement, with the apical and basal septum moving in opposite directions.
- The pulmonary artery may be small with abnormal valvular excursion in cases with associated pulmonary stenosis or atresia.

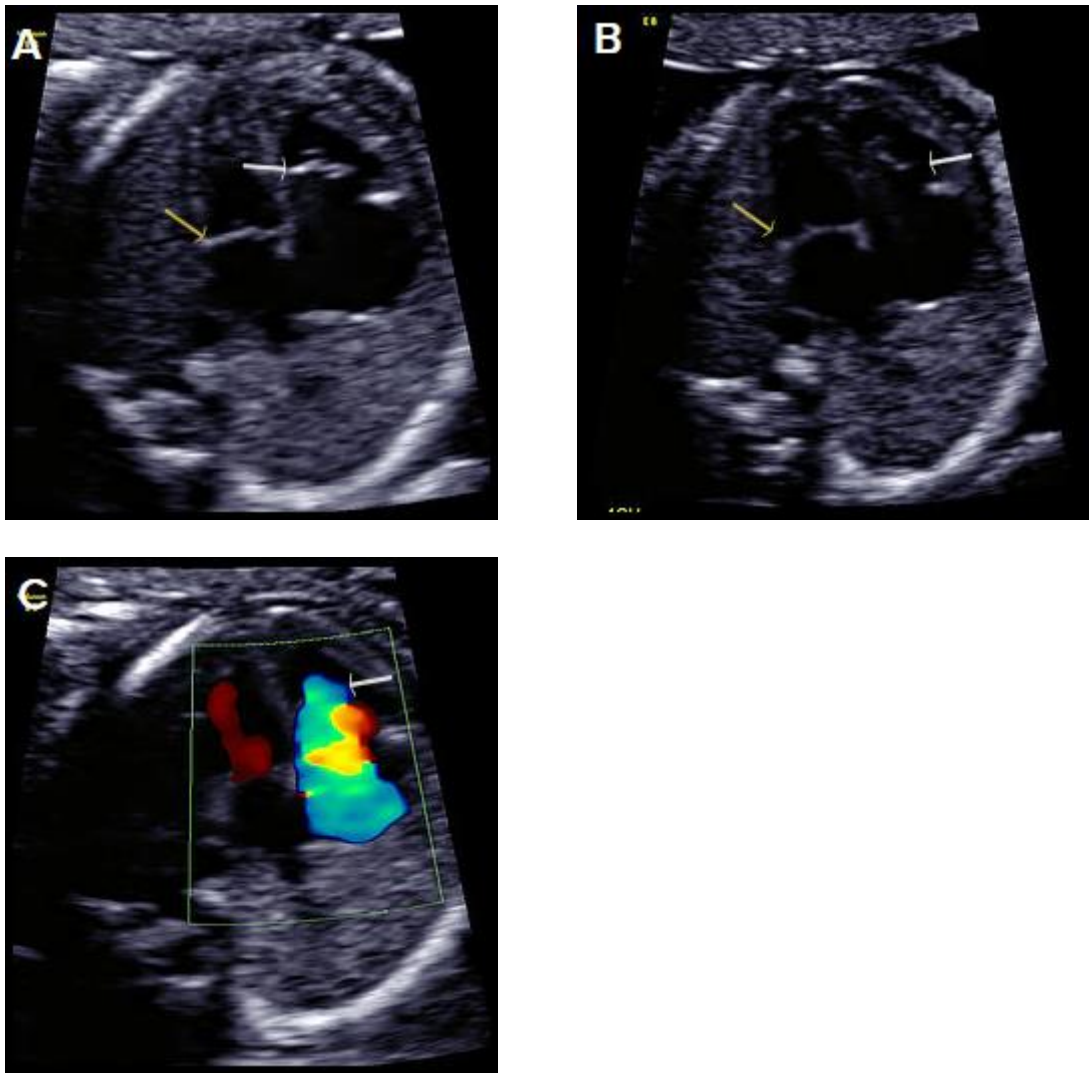
Colour Doppler

- There is often tricuspid regurgitation (typically high velocity >200 cm/s and holosystolic).
- The regurgitant jet usually arises from the mid RV (in comparison to tricuspid dysplasia when the regurgitant jet arises at the level of the valve annulus).
- Assessment of the RVOT with colour Doppler may show reversed flow within the ductus arteriosus towards the pulmonary valve or antegrade flow into a narrow pulmonary artery, with associated pulmonary atresia or stenosis.

Associations

- Other cardiac anomalies are relatively common in association with Ebstein anomaly and include:
 - pulmonary stenosis or atresia (possibly due to severe tricuspid regurgitation causing reduced flow across the pulmonary valve)
 - atrial or ventricular septal defects.
- Supraventricular tachyarrhythmia may be associated but is usually a postnatal finding.
- Most cases are isolated but may be associated with chromosomal anomaly, for example, trisomy 21 or 13.

Image 28



Greyscale 4Ch view in a fetus with Ebstein anomaly showing mild cardiomegaly and apical offset of the septal tricuspid valve leaflet (white arrow), with 'atrialisation' of the RV. Normal mitral valve position (yellow arrow), in diastole **(A)**, with the same fetus in systole, with the valve leaflets open **(B)**. On colour Doppler imaging, there is a large tricuspid regurgitant jet arising from the mid-apical RV, (arrow) **(C)**.

Aortic arch obstruction

1 Coarctation of the aorta

- Coarctation is a relatively common anomaly occurring in 5–10 percent of neonates with congenital heart disease (CHD), characterised by narrowing of the aortic arch, usually at the isthmus, between the left subclavian artery and the ductus arteriosus.
- Tubular hypoplasia occurs when a long portion of the aortic arch is narrowed.
- Antenatal diagnosis may be difficult, particularly in the second trimester. The condition may not present until after closure of the ductus in neonatal life.
- Prenatal ultrasound has a poor positive and negative predictive value in detecting the lesion. This may be improved by measuring the isthmus and plotting it on a normogram (see **Matsui et al 2008**), calculating the isthmic: arterial duct ratio and assessing the isthmus with pulsed Doppler.

Ultrasound findings

B-mode

- Ventricular disproportion, with a narrower LV compared with the right, may be evident on the 4Ch view.
- Left ventricular contractility and the mitral valve are normal (unlike HLHS).
- The LVOT view is typically normal with a normal calibre ascending aorta.
- On the 3-vessel view, the transverse aortic arch is narrow compared with the PA. A persistent left SVC, if present, may also be identified in this plane.
- The extent and location of narrowing is best appreciated in the longitudinal aortic arch view (and most commonly involves the arch between the left subclavian artery and the origin of the ductus arteriosus).
- With severe coarctation, the transverse arch between the left common and left subclavian arteries may be narrowed and elongated, and the left subclavian artery arises at the junction of the ductus arteriosus with the descending aorta.

Colour Doppler

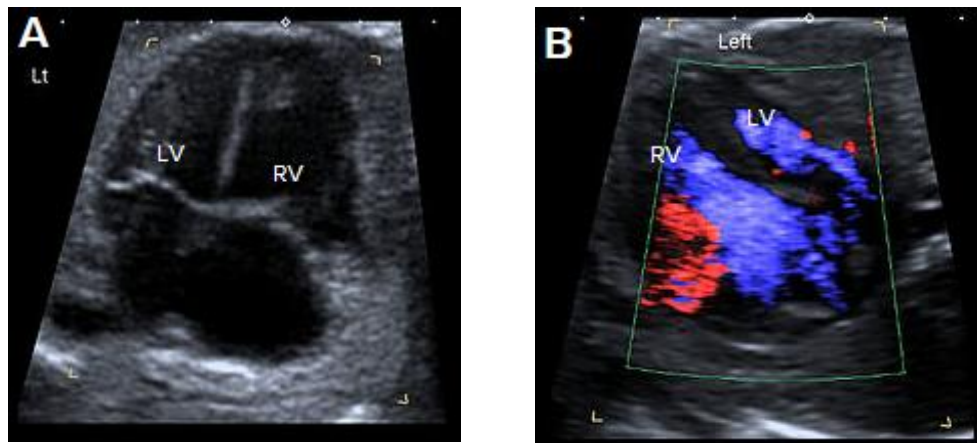
- There is normal filling of the LV in diastole on the 4Ch view (in contrast to HLHS).
- It shows forward flow across the aortic valve in the LVOT view.
- It demonstrates the isthmic narrowing on the longitudinal view, as well as the typical 'shelf' appearance at the junction of the ductus and descending aorta. This may be best appreciated with power Doppler.
- There is a narrow transverse arch on the 3-vessel view, with more pronounced narrowing towards the isthmus.
- Despite the narrowing, velocities are usually not increased, and colour aliasing is not usually present.

Associations

- Other cardiac anomalies, particularly large VSD. Other associated anomalies include aortic stenosis, bicuspid aortic valve, mitral stenosis.
- Persistent left SVC may be associated with coarctation, and this finding should prompt follow-up cardiac examination when there is subtle ventricular discrepancy.
- There can be chromosomal anomaly especially Turner syndrome and trisomies 13 and 18.
- Extra-cardiac abnormalities are common and include vascular anomalies and berry aneurysms.

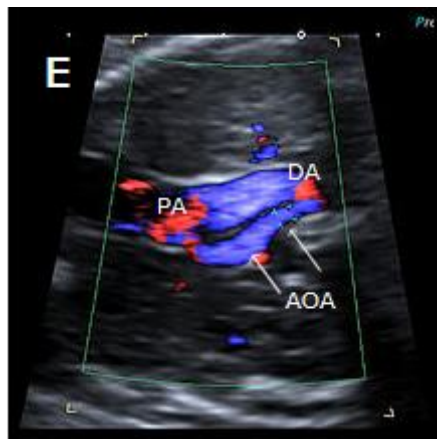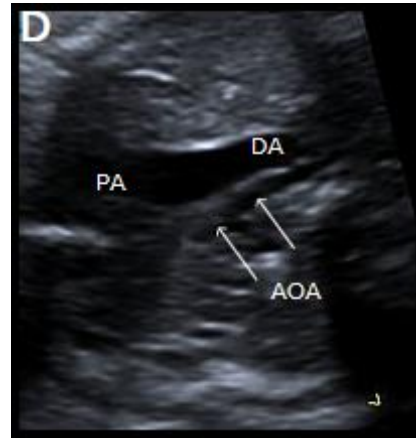
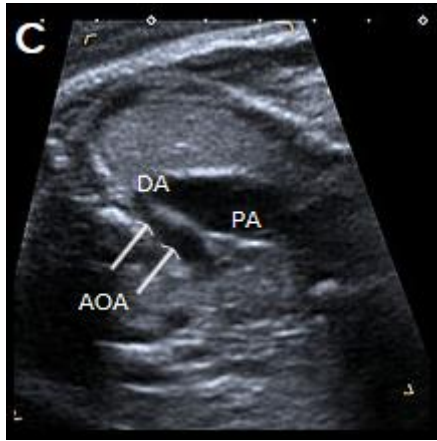
Beware: Severe fetal growth restriction may be associated with a narrowed isthmus due to shunting of blood and may be misinterpreted as coarctation.

Image 29



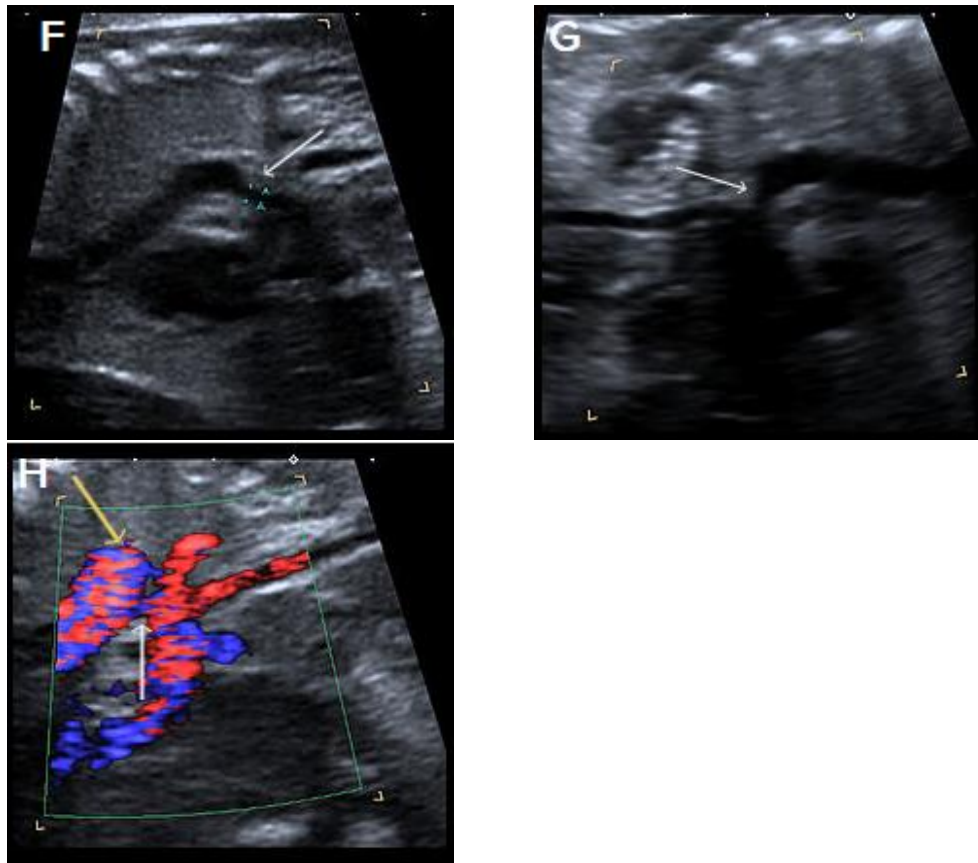
4Ch heart view showing narrower LV compared with the RV, on greyscale imaging (**A**), and with a narrower colour strip and patent AV valves on colour Doppler imaging (**B**).

Image 30



3-vessel view in two different fetuses with coarctation **(C)** and tubular hypoplasia of the aortic arch **(D)**, with a narrow aortic arch compared with the PA. Colour Doppler confirms the narrow calibre of the aortic arch compared with the PA **(E)**.

Image 31



Sagittal views of the aortic arch in greyscale in two different fetuses, showing narrowing in the isthmic region (arrow) **(F)** and **(G)** and in colour Doppler (white arrow) **(H)**, with the coarctation 'shelf' at the junction of the ductus and descending aorta (yellow arrow).

2 Interruption of the aortic arch

Interruption of the aortic arch (IAA) is a rare cardiac anomaly (comprising about 1 percent of CHD) in which there is incomplete development of the aorta, with a gap between the ascending and descending thoracic aorta. It is almost always found in association with other cardiac anomalies, including VSD, aorto-pulmonary window and CAT at the junction of the ductus and descending aorta.

IAA may be classified by the anatomic location of the site of interruption as follows.

- Type A: The aortic arch is interrupted after the left subclavian artery.
- Type B: The aortic arch is interrupted between the left common carotid artery and the left subclavian artery. This is the most common form of IAA and the type most frequently associated with 22q11.2 deletion.
- Type C: The aortic arch is interrupted between the brachiocephalic artery and the left common carotid artery. This is the least common type of IAA.

Ultrasound findings

B-mode

- Unlike coarctation, the left ventricular size is usually normal on the 4Ch view (particularly when associated with a large VSD).
- On the LVOT view, a small aortic root VSD may be evident.
- The 3-vessel view will be abnormal, with loss of continuity of the transverse aortic arch. The pulmonary trunk may appear slightly dilated.
- On the 3-vessel view, the thymus may be hypoplastic or absent (the PA abuts the sternum without normal intervening thymic tissue).
- The longitudinal view fails to show the continuous 'candy-cane' appearance of the aortic arch. The aorta may have a straight course, continuing into the brachiocephalic and left common carotid arteries.

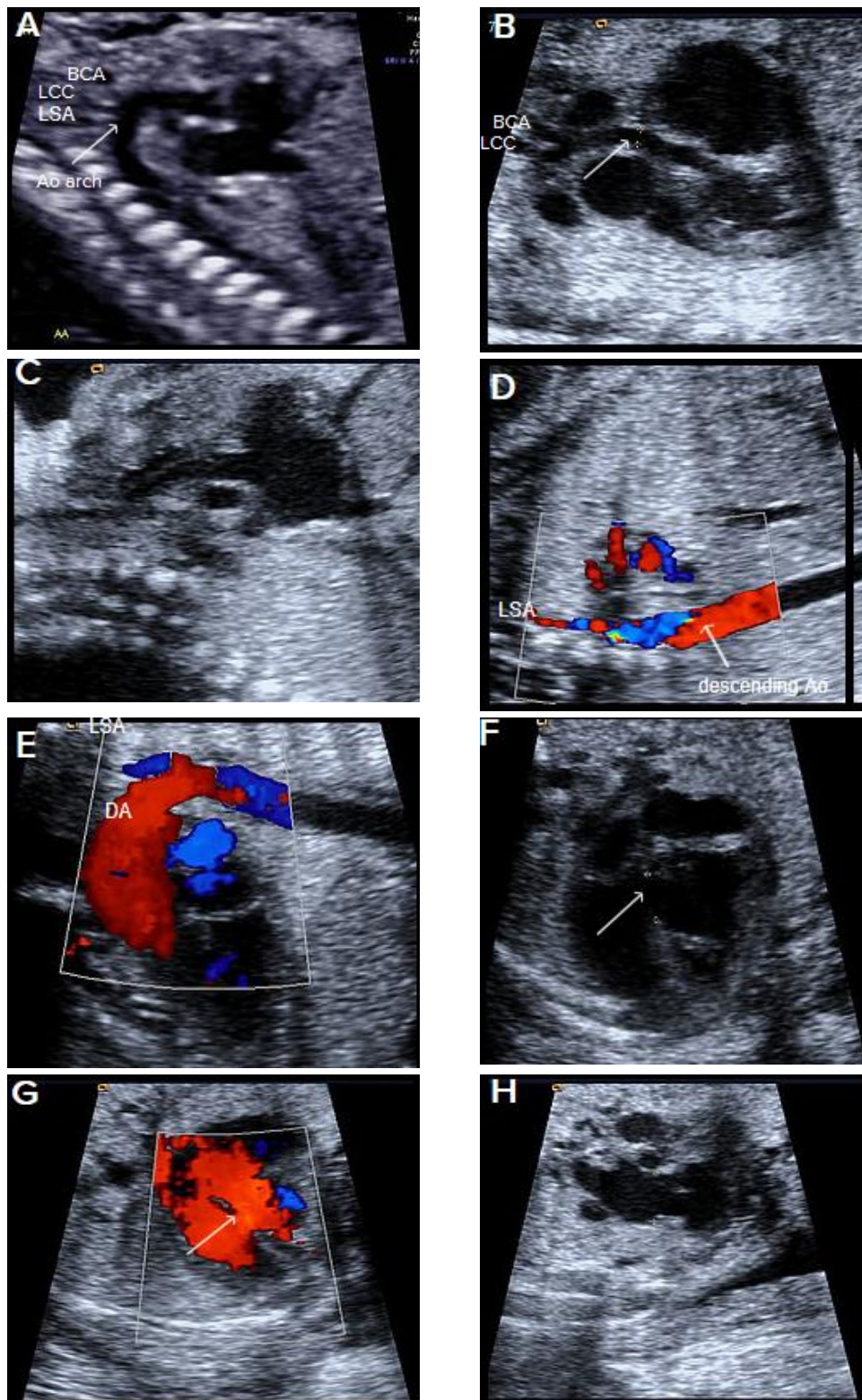
Colour Doppler

- The 4Ch and LVOT views may confirm a VSD.
- It will demonstrate normal flow across the aortic valve.
- There will be loss of continuity and straight course of the aorta towards the head and neck vessels on longitudinal views.
- The left subclavian artery will be arising from the ductus arteriosus (in type B).
- There may be an aberrant right subclavian artery coursing posterior to the trachea.

Associations

- Other cardiac anomalies, particularly VSD (in 90 percent of cases), right-sided aortic arch and aberrant subclavian arteries. Other associated cardiac anomalies include aorto-pulmonary window, AVSD, single ventricle and double outlet right ventricle.
- There could be 22q11.2 deletion (especially type B, in about 50 percent of cases).

Image 32



Longitudinal view of a normal aortic arch **(A)** showing the normal branching of the head and neck vessels. *Brachiocephalic artery (BCA)*, *left common carotid artery (LCC)*, *left subclavian artery (LSA)*.

A fetus with IAA showing an elongated straight course of the small calibre aorta (arrow), continuing into the brachiocephalic and LCC arteries **(B)**, and loss of continuity of the transverse arch in greyscale **(C)**, and colour Doppler **(D)**. The LSA arises from the ductus arteriosus (DA), **(E)**.

A perimembranous VSD is evident on greyscale **(F)**, and colour Doppler **(G)**, arrowed. Note that the ventricles are congruent in size. The RVOT appears dilated compared with the small aorta **(H)**.

Third trimester

Third-trimester scan

Indications

- High clinical risk of fetal growth restriction (maternal hypertensive disease, pre-eclampsia, maternal smoking, IVF, previous FGR/SGA, maternal medical disease) or as per the Growth Assessment Protocol (GAP)
- Current FGR, SGA or reduced interval fetal growth (see the **SGA guideline** for more detail, NZMFMN 2014a and **Appendix 9: SGA scanning schedule**) (section 88 codes: **GR and GF**)⁶
- Diabetes (NIDDM, IDDM, gestational diabetes)
- Placental location (code: **PL**)
- Malpresentation (code: **MP**)
- Antepartum haemorrhage (code: **AH**)
- Abdominal pain (code: **AP**)
- Reduced fetal movements (code: **FC**)
- **Follow up for fetal abnormality** (see below), for example, renal dilatation – see also **Appendix 7: Fetal renal tract dilation charts**⁷
- **Maternal red cell antibodies/Rhesus incompatibility** (see below)
- **Spontaneous or preterm premature rupture of membranes** (see below)
- **Polyhydramnios/oligohydramnios** (see below)
- **Multiple pregnancy** (see NZMFMN 2015f).

Note: A growth scan is not recommended in women where symphysial-fundal height (SFH) is tracking along or above the 90th centile if gestational diabetes has been excluded and there is no clinical concern regarding polyhydramnios (see the **SGA guideline** for more detail, NZMFMN 2014a).

Note: In the absence of any clinical indications, routine post-date scanning is not currently recommended.

⁶ See **Appendix 1: Ultrasound scan codes and indications**.

⁷ To view the fetal renal tract dilation charts at source, see: <https://media.starship.org.nz/renal-tract-dilation-flow-chart/renal-tract-dilation-flow-chart.pdf>

Required clinical details

- Reason for scan/symptoms, as per section 88 indication
- EDD based on earliest scan, if available
- Relevant history
- Previous caesarean section(s).

Third-trimester ultrasound examination

Fetal biometry

Growth charts as per local protocol. At present, ASUM are used in most sites.

- BPD
- HC
- AC
- FL
- Estimated fetal weight (EFW) (Hadlock A) or Shepard (AC and FL) if accurate head measurements cannot be obtained.

As per the **SGA** and **Obstetric Doppler** guidelines (NZMFMN 2014a and 2014b respectively), suboptimal fetal growth is suspected when:

- AC \leq 5th centile on population chart
- AC centile smaller than head by \geq 30 centiles
- AC $>$ 5th centile but dropping by \geq 30 centiles
- change in AC of $<$ 5 mm over 14 days
- EFW $<$ 10th centile on customised chart (eg, GROW)
- EFW dropping by \geq 30 centiles on customised chart.

The minimum interval between growth scans is 14 days. See **Appendix 9: SGA scanning schedule**.

- Fetal number
- Fetal lie and position
- Fetal cardiac activity
- Gestational age
- **Placenta** (see above) – location in relation to the cervix
 - **Placenta accreta**: where there is anterior placenta previa and previous caesarean section, the overlying myometrium should be carefully assessed using high resolution TA and TV scanning with some fluid within bladder

- **Amniotic fluid** (see below)
- Doppler (only if indicated, see **Doppler** chapter below)
- Maternal adnexa (only if indicated, see **Abdominal pain** below)
- Limited fetal anatomy (see **Fetal anatomy** below).

Amniotic fluid

- Measurement to include amniotic fluid index (AFI) and single deepest pocket.
- AFI varies with gestation (plot on a standardised chart).
- Normal deepest pocket is between 2 and 8 cm.
- Polyhydramnios is defined as single deepest pocket of ≥ 10 cm and/or AFI ≥ 25 cm.
- Oligohydramnios is defined as single deepest pocket < 2 cm.

Doppler

Routine Doppler is not indicated.

For more detail, see the **SGA** and **Obstetric Doppler** guidelines (NZMFMN 2014a and 2014b respectively) for Doppler indications and the **Doppler** chapter below.

Fetal anatomy

This assessment is for uncomplicated scans performed after 20 weeks, assuming a previous normal anatomy scan.

For otherwise uncomplicated serial scans, detailed assessment of anatomy is only necessary once in the third trimester.

For the first scan in the third trimester, image:

- ventricle / choroid plexus – measure if abnormal
- 4Ch heart, including IVS (+ colour)
- 3VT / arrow view (+ colour)
- both kidneys (measure AP pelvis in trans if dilated)
- bladder
- stomach
- lips/nose.

Fetal wellbeing (interval amniotic fluid and Doppler) scan

If growth assessment as above has been performed within the last two weeks, a limited fluid and Doppler scan may be indicated, particularly as directed by the **SGA pathway** (see Appendix 9).

Ultrasound examination

- Fetal lie
- Amniotic fluid assessment as above
- Doppler (if indicated, see **Doppler** chapter below)
- Fetal stomach and bladder
- Document fetal movements.

Third-trimester scan for other indications

Ultrasound examination

Routine assessment as per **Third-trimester ultrasound examination** above, with additional views as below.

Diabetes in pregnancy

The recommended frequency of scans for women with gestational diabetes is outlined in *Screening, Diagnosis and Management of Gestational Diabetes in New Zealand: A clinical practice guideline* (Ministry of Health 2014).

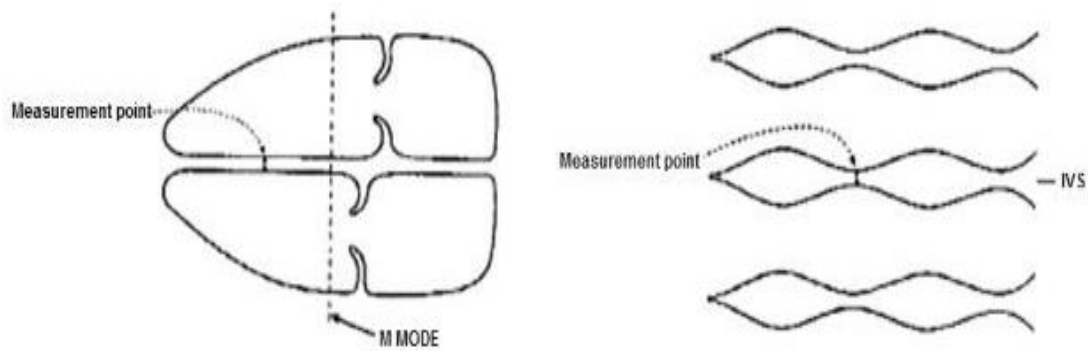
Assessment of IVS in diabetes

An increase in fetal IVS and ventricular wall thickness is reported in diabetic pregnancy. These babies are at increased risk of cardiomyopathy. Consider measurement of the IVS in diabetic patients with EFW ≥ 90 th centile.

IVS imaging technique

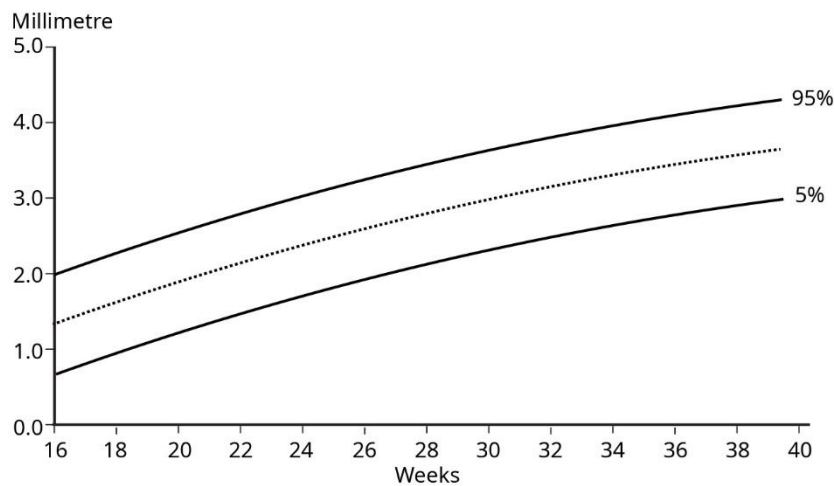
- Orientate transducer so the beam is perpendicular to the long axis of the heart.
- Measure peri-membranous portion of IVS either with M-mode or B-mode.
- Measure during diastole (when AV valves are open).
- Measure at tip of AV valves.
- Plot figure obtained on standardised chart if available.

Figure 3: IVS imaging technique



Source: Canterbury DHB Obstetric and Gynaecology Ultrasound Protocols, June 2019 (internal DHB document).

Figure 4: IVS reference chart



Source: Tan et al 1992.

Maternal antibodies involved in haemolytic disease of the newborn, for example, Rhesus incompatibility

- If there are known maternal antibodies, perform MCA PSV and plot on the appropriate graph. See **New Zealand Obstetric Doppler Guideline** (NZMFMN 2014b). These women should be under specialist care.
- Specialist referral is required for PSV > 1.5 MoM.
- Assess for fetal hydrops – identification of hydrops should prompt immediate discussion with the referrer to arrange urgent Fetal Medicine or specialist referral.

Antepartum haemorrhage

- Ultrasound should not be requested in cases of strong clinical suspicion of abruption as this is a clinical emergency.
- Document placental location, structure, cord insertion and distance of lower placental margin from internal cervical os. Consider use of colour for further evaluation of retroplacental haemorrhage/abruption.

- Routine colour box over internal cervical os to exclude **vasa previa** (see above).
- TV scan should be considered if:
 - the lower placental margin is not clearly seen on TA scan
 - the placenta is low lying or possible previa
 - there is a placental anomaly, for example, succenturiate lobe, velamentous or marginal cord insertion.
- TV scanning is generally contraindicated in patients with ruptured or bulging membranes. PV bleeding is not a contraindication for TV scanning.

Abdominal pain

- Placental location and structure – exclude haematoma (consider use of colour for further evaluation of retroplacental haemorrhage/abruption)
- Maternal adnexa/ovaries
- Maternal renal tract if clinically indicated
- Maternal right iliac fossa (RIF) – if clinically appropriate to assess for possible appendicitis
- Maternal upper abdomen / gallbladder – only if requested or specifically indicated, for example, right upper quadrant (RUQ) or epigastric pain
- If maternal renal colic is suspected, or if maternal ureteric dilatation is seen, consider TV scan to assess for a calculus in the distal ureter.

Spontaneous or preterm premature rupture of membranes

- Document amniotic fluid.
- Place colour box over the cervix – helpful if the cervix appears open in order to exclude a prolapsed umbilical cord.
- TV scanning is generally contraindicated in patients with ruptured membranes.
- Note: Ultrasound is not a substitute for clinical diagnosis of preterm premature rupture of the membranes (PPROM).

Polyhydramnios/Oligohydramnios

- Document amniotic fluid.
- For oligohydramnios, consider causes such as: SGA, spontaneous rupture of membranes (SROM) / premature rupture of membranes (PROM), renal anomalies such as obstructive uropathy and bilateral renal abnormality.
- For polyhydramnios, consider causes such as: large for gestational age (LGA), maternal type 2 diabetes mellitus (T2DM), gestational diabetes mellitus (GDM), upper gastrointestinal problem (such as duodenal atresia, oesophageal atresia or trachea-oesophageal fistula), major brain anomaly, facial abnormality.
- For a combination of SGA and polyhydramnios, consider aneuploidy.

Multiple pregnancy

See **Twin pregnancy** chapter below and the guideline *Multiple Pregnancy* (NZMFMN 2015f).

Placenta

- Follow-up for placental location in cases of low-lying placenta detected in the second trimester (section 88 code **PL**, see Appendix 1) or possible **placenta accreta/AIP** (see above).

Malpresentation

- Section 88 code **MP** (see Appendix 1)
- Report position of the fetus, including the presenting part.

Follow-up of fetal renal dilatation or other relevant second-trimester findings

Assess relevant anatomy, for example, fetal renal tract – see **Appendix 7: Fetal renal tract dilation charts**.⁸

Reduced fetal movements

- Section 88 code **FC** (see Appendix 1)
- Doppler (umbilical artery Doppler, ± middle cerebral artery if appropriate – see *New Zealand Obstetric Doppler Guideline*, NZMFMN 2014b)
- Document fetal movements/breathing.

Reporting guide and recommendations

Minimum reporting requirements

- Dating information by previous scan (if available)
- Fetal biometry
- Fetal position/lie
- Placental location and its relation to the cervix
- Amniotic fluid (AFI, deepest pocket)
- Fetal anatomy with structures, as per **Third-trimester ultrasound examination** (see above)

⁸ To view the fetal renal tract dilation charts at source, see: <https://media.starship.org.nz/renal-tract-dilation-flow-chart/renal-tract-dilation-flow-chart.pdf>

- **Doppler** – only if indicated (see the **SGA** and **Obstetric Doppler** guidelines, NZMFMN 2014a and 2014b respectively)
- Conclusion regarding interval growth if there has been a previous third-trimester scan
- Recommendation of follow-up scan at an appropriate interval if there is concern regarding growth, amniotic fluid or Doppler as per the **SGA guideline**.

Scan frequency

See the **SGA guideline** (NZMFMN 2014a) and **Appendix 9: SGA scanning schedule**.

- High-risk pregnancies: 2- to 3-week scan interval, for example, for monochorionic diamniotic (MCDA) twins (see **Multiple Pregnancy**, NZMFMN 2015f), previous FGR, pre-eclampsia toxemia (PET), intrauterine fetal death (IUFD) or reduced interval growth on scan
- Routine: 4-weekly intervals, for example for GDM, dichorionic diamniotic (DCDA) twins demonstrating normal interval growth.

Reporting pro forma

See below for **third-trimester reporting pro forma**.

Reporting alerts

- Placental abruption

- Critically abnormal Doppler
- Hydrops
- Anhydramnios
- PV bleeding in context of accreta
- Absent fetal movements in context of other evidence of fetal distress

- Abnormal Doppler, eg, elevated umbilical artery Doppler with continuous forward flow
- Mildly reduced MCA pulsatility index and cerebroplacental ratio
- Structural fetal anomaly, unless previously reported and stable.

Hydrops

Hydrops is defined as fluid within two or more body spaces, for example:

- pericardial effusion
- pleural effusion/s
- ascites
- skin oedema.

Causes

- Non-immune (see *Nonimmune Hydrops Fetalis*, NZMFMN 2012)
- Immune (see **RBC antibodies and thalassemia** below).

Ultrasound examination

As per **Third-trimester ultrasound examination** above.

Additional views

- Heart rate and rhythm to exclude fetal cardiac arrhythmia.
- MCA PSV (see *New Zealand Obstetric Doppler Guideline*, NZMFMN 2014b) to exclude fetal anaemia from maternal rhesus disease or other causes. Obtain the waveform when the fetus is quiescent and ideally at an angle of 0 degrees (but 30 degrees or less is acceptable). Chart on the appropriate graph (as per *New Zealand Obstetric Doppler Guideline*).
- Document hydrops.

Reporting guide and recommendations

- Report general findings as per the **third-trimester reporting guide** above.
- Report MCA PSV, comment on multiples of the median (MoM).
- Comment on hydrops/body cavity involvement.

If MCA PSV is elevated, then moderate to severe fetal anaemia is likely. This is an obstetric emergency, usually requiring intrauterine blood transfusion or delivery. Notify referrer to arrange Fetal Medicine or specialist referral immediately.

Reporting alerts

- Hydrops
- Elevated MCA PSV.

RBC antibodies and thalassemia in pregnancy

Women with maternal red cell antibodies or thalassaemia in pregnancy are at increased risk of fetal anaemia. Rhesus disease has been the most common, but a list is included below. Fetal Medicine review is recommended.

Frequency of scanning should be as per local Fetal Medicine / specialist unit recommendation.

Indications

- Fetal hydrops
- Rhesus alloimmunisation (RhD)
- Rhesus c
- Anti-Kell
- Anti-Fya or Anti-E (rarely)
- Thalassemia (alpha)
- Parvovirus infection can also present with hydrops and fetal anaemia.

These are the main risks for fetal anaemia. Please discuss any others with a Fetal Medicine / specialist unit.

Ultrasound examination

As per **Third trimester ultrasound examination** above.

See also ***New Zealand Obstetric Doppler Guideline*** (NZMFMN 2014b).

Additional views

- MCA PSV and chart on graph (see ***New Zealand Obstetric Doppler Guideline***, NZMFMN 2014b).
- Assess for hydrops (fluid in two or more compartments, ie, pericardial effusion, pleural effusion, fetal ascites, skin oedema).
- Assess amniotic fluid.

Reporting guide and recommendations

- Report general findings as per the **third-trimester reporting guide** above.
- Report MCA PSV, comment on MoM.
- Comment on hydrops/body cavity involvement.

If MCA PSV is elevated, then moderate to severe fetal anaemia is likely. This is an obstetric emergency, usually requiring intrauterine blood transfusion or delivery. Notify referrer to arrange Fetal Medicine or specialist referral immediately.

Reporting alerts

- Hydrops
- Elevated MCA PSV.

Third-trimester reporting pro forma

Normal third-trimester scan report

- Compare growth with previous scans, if available.
- Note that this is a non-customised growth estimate and recommend customised growth charts.

Clinical

[]

EDD by earliest ultrasound at [] weeks: []

Gestational age: [] weeks, [] days, \pm [] days.

Growth scan:

Fetal measurements:

BPD [] mm

HC [] mm

AC [] mm

FL [] mm.

EFW = [] g, \pm 15 percent. EFW lies on the []th centile.

Fetal movements visible

Presentation: [cephalic/breech, spine right/left]

Amniotic fluid: normal, AFI [] cm

Placenta: [anterior], [not low lying].

Fetal anatomy not assessed in detail. Normal fetal cerebral ventricles, stomach, 4Ch heart, kidneys, bladder.

Comment

EFW lies on the [] centile. Normal amniotic fluid.

Report conclusions

Normal initial growth scan

EFW lies on the [] centile. Normal amniotic fluid.

Normal serial growth scan

Satisfactory interval growth. EFW lies on the [] centile. Normal amniotic fluid.

Normal serial growth scan with clinical indication for Doppler

Satisfactory interval growth. EFW lies on the [] centile. Normal amniotic fluid and [umbilical artery, etc] Doppler.

Increased interval growth

There has been an increase in interval growth from the previous scan at [] weeks, [] days, predominantly based on [AC, etc]. EFW lies on the [] centile. Normal amniotic fluid.

Reduced interval growth

There has been a decline in interval growth, predominantly based on [AC, etc]. EFW lies on the [] centile. Normal amniotic fluid and [umbilical artery, etc] Doppler.

Amniotic fluid and Doppler interval scan

Normal [AFI / deepest vertical pocket (DVP)] and Doppler. Measurements have not been repeated today as the last scan was less than 2 weeks ago.

Placental location follow-up

The placenta is no longer low lying.

The placenta remains low lying, [] mm from the internal cervical os. A further scan is recommended at [] weeks (*if appropriate*).

Doppler requested by referrer but not indicated

As there are no clinical risk factors for SGA indicated and fetal growth is normal with no other adverse features, Doppler assessment has not been performed (as per the New Zealand Obstetric Doppler Guideline).

Post-dates Doppler

Normal Doppler post-dates may be falsely reassuring. Clinical assessment is required.

Customised growth chart recommendation

This should be added to all growth scan reports.

Growth measurements in this report are plotted on population-based growth charts. It is recommended that EFW be plotted on a customised chart (eg, GROW). If the EFW is below the 10th centile on the customised chart, please refer for urgent Doppler assessment.

Pain in third trimester

No obstetric cause for pain seen. If symptoms persist, GP referral is recommended.

Isolated muscular VSD

Isolated muscular VSD 1–2 mm requires neonatal review. Postnatal echo will be arranged if a murmur is heard on auscultation.

Isolated muscular VSD >2 mm requires neonatal review and postnatal echo.

Doppler

Doppler assessment should follow the national guidelines recommended in the **SGA** and **Obstetric Doppler** guidelines (NZMFMN 2014a and 2014b respectively).

Routine fetal Doppler is not indicated in a normal, low-risk pregnancy.

For more detail, see **Doppler in Obstetrics** (Nicolaides et al 2002).

Indications for Doppler

1. **Suspected fetal growth restriction / compromise / hypoxia**
 - Umbilical artery (UA PI), with the addition of middle cerebral artery (MCA PI), ductus venosus (DV PI) as per the **SGA** and **Obstetric Doppler** guidelines (NZMFMN 2014a and 2014b respectively).
2. **Screening for severe early onset FGR or pre-eclampsia in high-risk women**

Note: Routine screening in low-risk women is not currently recommended in New Zealand.

 - Uterine artery Doppler at 20–24 weeks.
3. **Assessing for fetal anaemia**
 - MCA PSV or V-max.
4. **MCDA twins** (covered in the section under the next chapter **Twin pregnancy**)

1 Suspected fetal growth restriction / compromise / hypoxia

Umbilical artery pulsatility index (UA PI)

Indications

- Suspected or known SGA fetus
- EFW on customised chart (eg, GROW) is <10th percentile
- EFW on customised chart is dropping percentiles by ≥ 30 percent
- AC on the population scan chart is <5th percentile
- Discrepancy (≥ 30 percent) between the HC and AC percentile with lower AC percentile
- Maternal hypertensive disorders, for example, pre-eclampsia
- Decreased fetal movements.

The **abnormal UA waveform** shows progressive high-resistance flow with reduced, absent and then reversed diastolic flow.

>95th percentile is abnormal.

Middle cerebral artery pulsatility index (MCA PI)

Indications

- SGA/FGR with abnormal UA PI at any gestation
- SGA/FGR with normal UA PI after 34 weeks gestation.

Abnormal MCA PI indicates fetal compensation by redistribution of fetal blood flow to the brain ('brain sparing') and shows progressive low-resistance flow with increasing diastolic flow.

<5th percentile is abnormal.

Cerebroplacental ratio (CPR)

If MCA PI assessment is performed, the CPR should be calculated and recorded.

The CPR is the ratio of MCA PI and UA PI (ie, MCA PI divided by UA PI).

<5th percentile is abnormal.

Ductus venosus pulsatility index (DV PI)

DV can be technically challenging to measure and should only be performed by experienced individuals.

Indications to perform DV PI (if possible)

- Markedly raised UA PI (>95th) and reduced MCA PI in preterm SGA.
- MCDA twin pregnancy with **twin-to-twin transfusion syndrome (TTTS)** (see below) or selective FGR.

An **abnormal DV PI** (\pm absent or reversed atrial (A) wave) indicates fetal cardiac decompensation.

>95th percentile is abnormal.

2 Screening for severe early onset FGR or pre-eclampsia in high-risk women

Mean uterine artery pulsatility index

Indications

- Screening of women at high risk of early pre-eclampsia or early SGA at 20 or 24 weeks
- If abnormal at 20 weeks, repeat at 24 weeks
- Early onset FGR
- Current hypertensive disorder in pregnancy
- Full assessment of suspected SGA or PET in pregnancy.

Abnormal mean uterine artery pulsatility index

- >95th percentile is abnormal.
- Notching after 24 weeks is abnormal.

3 Assessing for fetal anaemia

Middle cerebral artery peak systolic velocity (MCA PSV)

Indications

- Maternal-fetal alloimmunisation
- Any suspicion of fetal anaemia
- Unexplained hydrops
- MCDA twins >24 weeks gestation
- MCDA twins with known or suspected TTTS or twin anaemia-polycythaemia sequence (TAPS).

>1.5 MoM is abnormal.

Doppler technique

See *New Zealand Obstetric Doppler Guideline* (NZMFMN 2014b).

Umbilical artery pulsatility index

- If the PI is within normal range, only sample one of the umbilical arteries.
- If the PI is abnormal, sample both umbilical arteries and use the more normal (lower) value.

Middle cerebral artery pulsatility index

- Perform assessment during fetal quiescence.
- Start with the BPD view and move caudally to visualise the butterfly shape of suprasellar cisterns and the sphenoid.
- Assess the MCA that is closer to the transducer.
- Move anteriorly and angle back to align the MCA flow direction with the Doppler beam.

Ductus venosus pulsatility index

- Perform assessment during fetal quiescence.
- Sagittal and transverse approaches are acceptable as long as the Doppler angle is 0–60 degrees.
- Use colour Doppler to identify the DV at the end of the umbilical vein.
- If PI >95th percentile, assess umbilical vein for pulsatility.

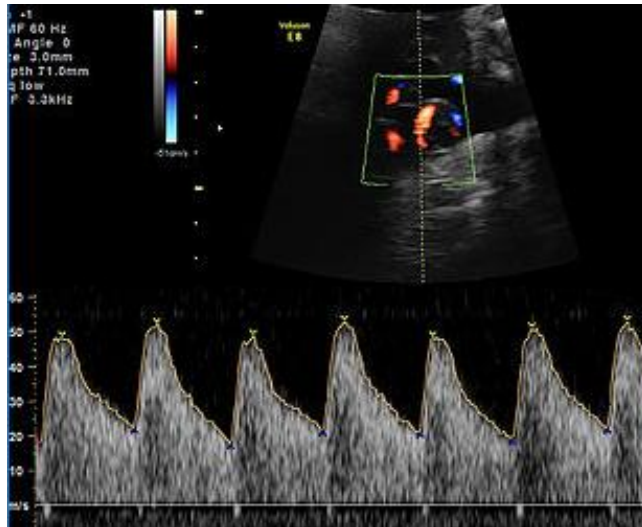
Middle cerebral artery peak systolic velocity

- As above for MCA PI but with an ideal interrogation angle of 0 degrees.
- An interrogation angle of 30 degrees or less is acceptable but requires angle correction.
- If PSV >1.5 MoM, obtain three high-quality samples and use the highest value.

Doppler waveforms: Normal and abnormal

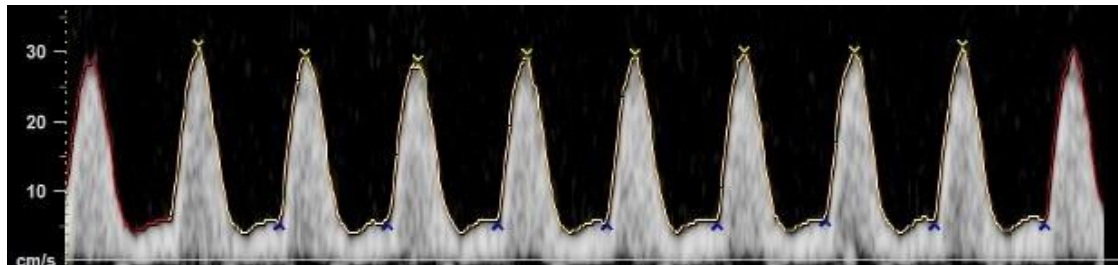
Umbilical artery Doppler

Image 33



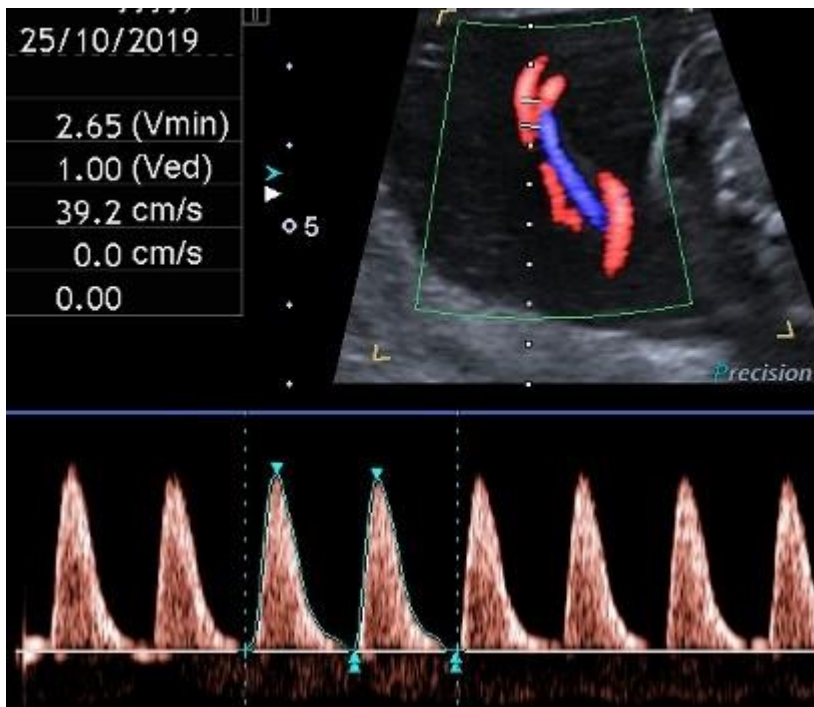
Normal umbilical artery Doppler: Low resistance.

Image 34



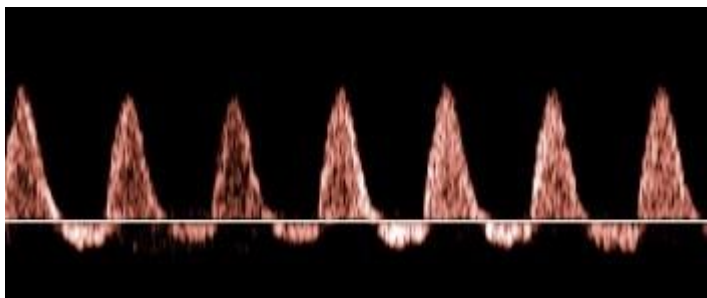
Abnormal: High PI / resistive index (high resistance trace).

Image 35



Abnormal: Very high PI / resistive index with absent end-diastolic flow and pulsatility in the umbilical vein.

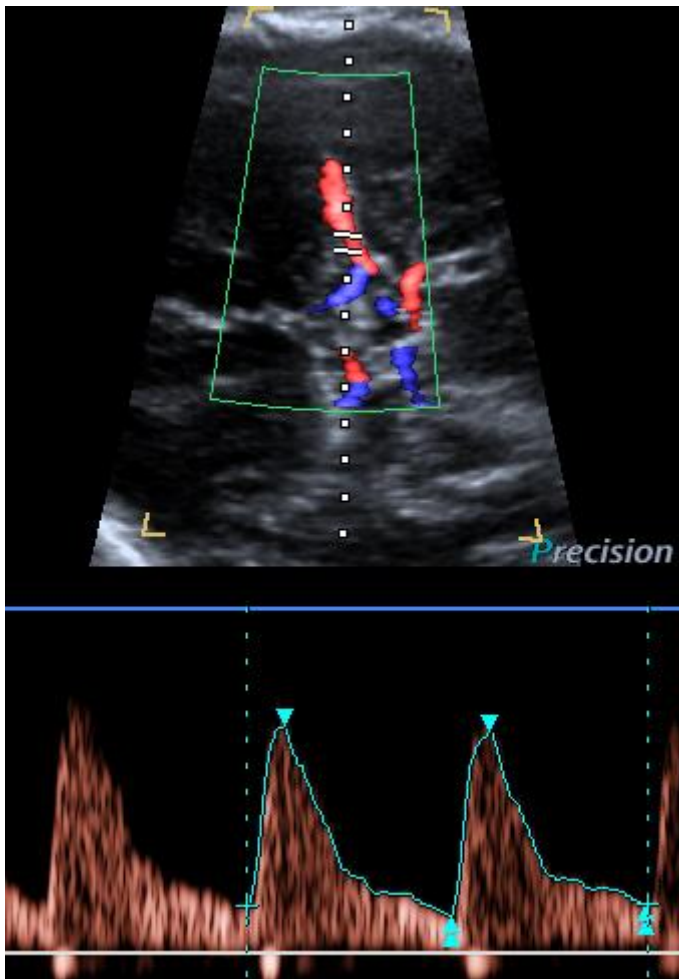
Image 36



Abnormal: Reversed end-diastolic flow.

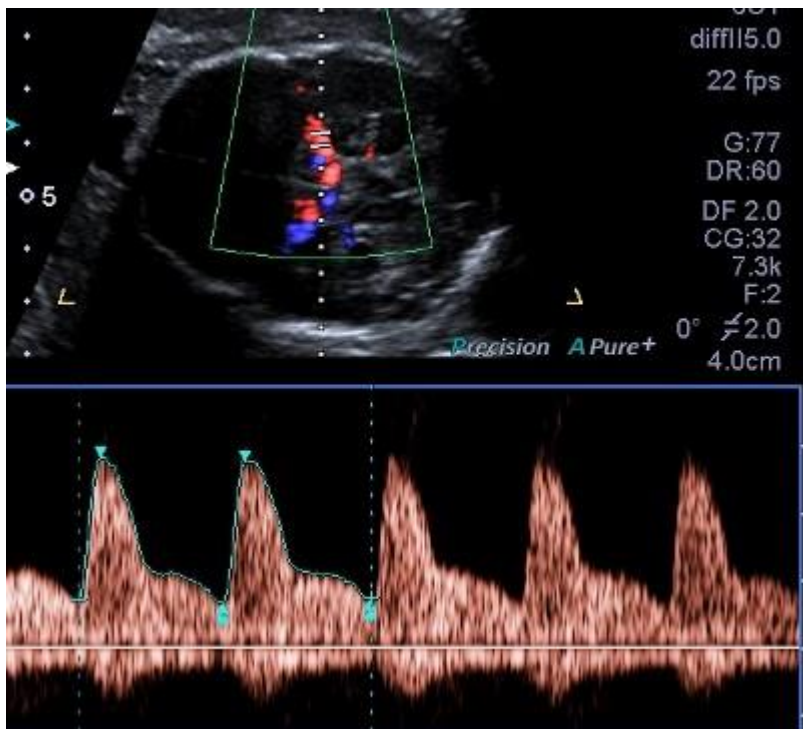
Middle cerebral artery Doppler pulsatility index

Image 37



Normal MCA Doppler: High resistance with low diastolic flow velocities.

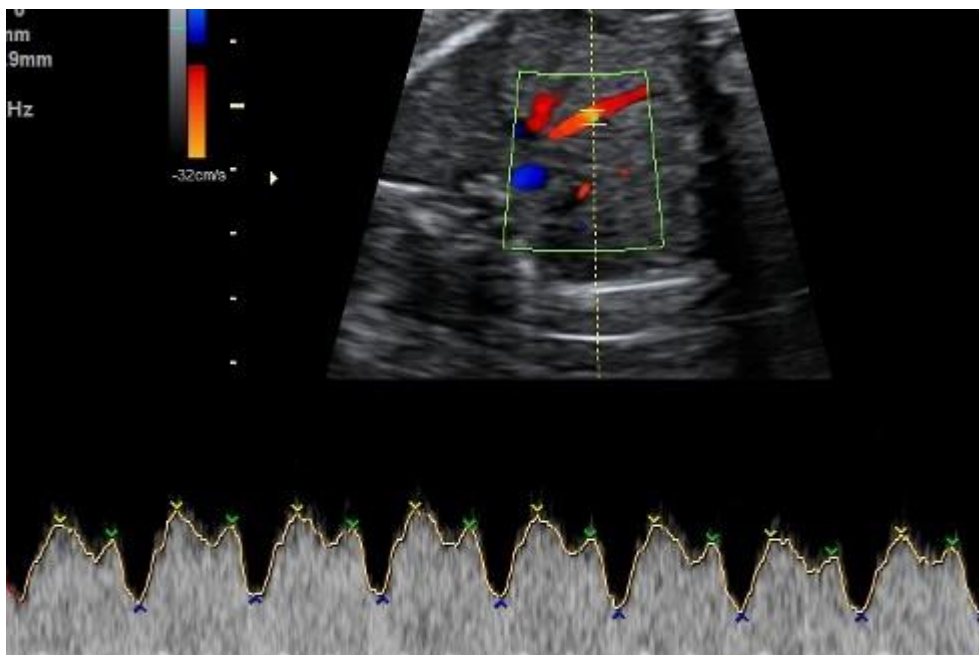
Image 38



Abnormal: Low-resistance MCA waveform with high diastolic velocities.

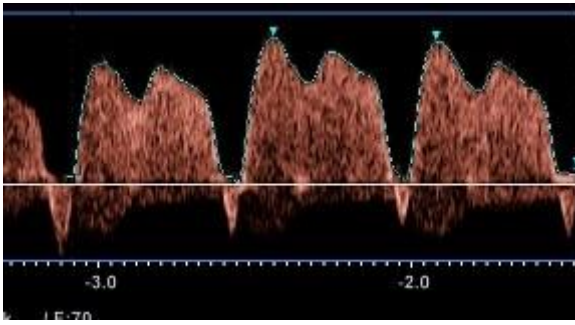
Ductus venosus Doppler

Image 39



Normal waveform with A wave above baseline.

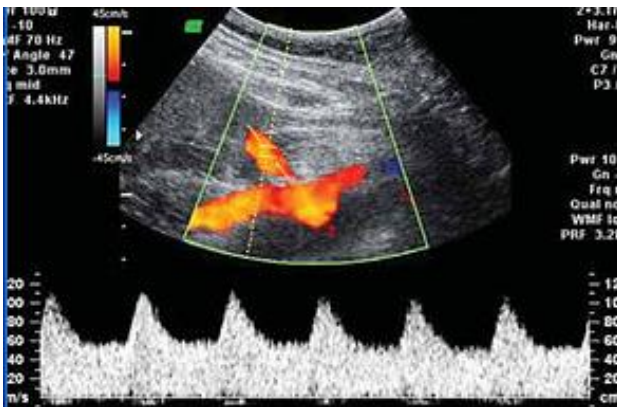
Image 40



Abnormal waveform: A wave below baseline and increased pulsatility.

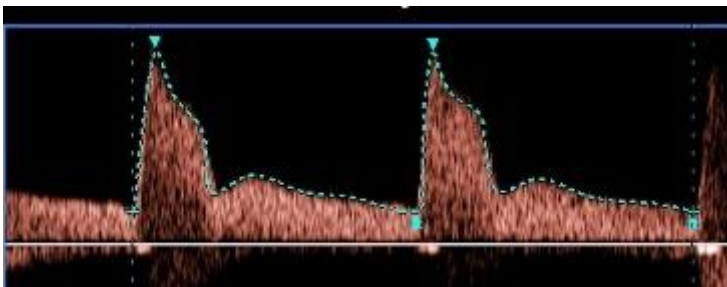
Uterine artery Doppler

Image 41



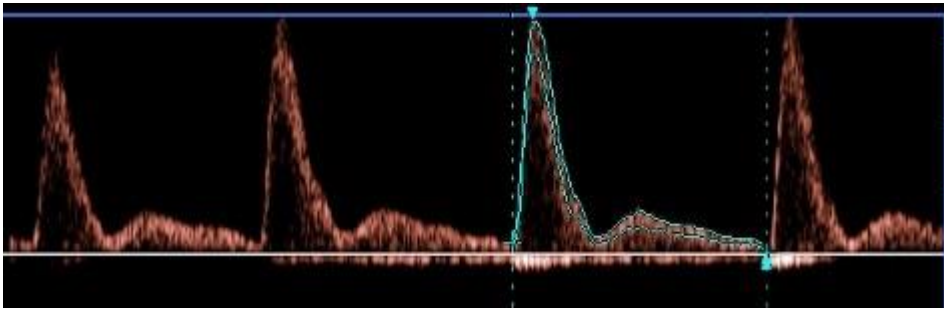
Normal low impedance / low resistance waveform with high diastolic flow and no notch.

Image 42



Normal diastolic flow (normal impedance to flow) but early diastolic notching.

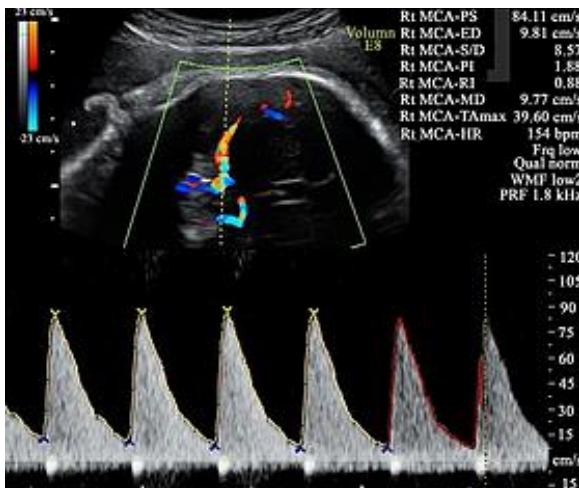
Image 43



Abnormal waveform: Increased PI, with reduced diastolic flow and early diastolic notching.

Middle cerebral artery peak systolic velocity (MCA PSV)

Image 44



Elevated MCA PSV, well above 1.5 MoM.

Reporting guide and recommendations

- Report the PI value and whether it is normal or abnormal for each Doppler performed.
- Report the MoM for MCA PSV, if performed.

Reporting alerts

- Critically abnormal Doppler, eg, umbilical artery absent or reversed end-diastolic flow
- MCA PSV >1.5 MoM
- Mildly abnormal Doppler, requiring follow-up.

Twin pregnancy

Assessment of **chorionicity and amnionicity** (see below) is vital (first-trimester assessment is optimal).

Label the leading fetus 'twin A' and the following fetus 'twin B' and record position as left and right and upper and lower, by the relationship of each sac to the cervix, and assign gender if discordant.

Twins frequently change position: the description of fetal position must be clear, and state if the previously leading twin is no longer presenting; however, the labelling of twins A and B must not be changed during the pregnancy.

For further information, see **Multiple Pregnancy** (NZMFMN 2015f).

Ultrasound screening in twins

Dichorionic twins

- **12–13+6 week scan** (see above) for each fetus as per singleton pregnancy. The **NT** is used for screening for aneuploidy in twins and is combined with biochemistry to provide a risk assessment.
- **Anatomy scan** (see above) at 19+ weeks.
- **Third-trimester scan** (growth scans) every four weeks, with the addition of Doppler and fortnightly growth as per the **SGA guideline** (NZMFMN 2014a) if either twin meets SGA criteria.

Monochorionic twins

- **12–13+6 week scan** (see above) for each fetus as per singleton pregnancy. The **NT** is used for screening for aneuploidy in twins and is combined with biochemistry to provide a risk assessment.

Discordant CRL in monochorionic twins is associated with an increased risk of subsequent development of selective fetal growth restriction (sFGR).

Discordant NT in monochorionic twins may be associated with an increased risk of subsequent development of TTTS.

Because of the potential **complications of monochorionic twinning** (see below), including **TTTS, TAPS** and **sFGR**, **fortnightly scans** are advised **from 16 weeks gestation to delivery**.

Every scan must include:

- biometry for both twins including EFW from 20 weeks, amniotic fluid deepest vertical pool for both sacs, presence/absence of bladder and stomach filling
- document UA Doppler from 20 weeks, or before if signs of TTTS or sFGR; assess for normal, absent or reversed end-diastolic flow
- **anatomy scan** (see above) at approximately 20 weeks
- from 24 weeks, MCA PSV in both twins.

In the case of fetal demise of one fetus, there is a significant risk of ischemic brain damage in the surviving co-twin. A Fetal Medicine referral is needed. Consideration should be given to magnetic resonance imaging (MRI) 6 weeks after the event, or longer depending on the gestation and parental wishes. Note: MRI is a tertiary-level decision.

Diagnosis of TTTS

- Oligohydramnios of one twin with deepest pocket <2 cm and polyhydramnios of the other, deepest pocket >10 cm. If there is discordancy that does not meet these criteria, but the sonographer/radiologist has concerns, recommend referral to local Fetal Medicine unit for a decision on the next scanning or review required.
- Quintero staging (based on discrepancy of amniotic fluid):

Quintero staging

Stage 1:

- <20 weeks twin 1 DVP <2 cm; twin 2 >8 cm
- >20 weeks twin 1 DVP <2 cm; twin 2 >10 cm

Stage 2:

- Absent bladder in twin with oligohydramnios

Stage 3:

- Critically abnormal Doppler in either twin (absent or reversed umbilical artery Doppler)

Stage 4:

- Hydrops in either twin

There may be associated growth discrepancy and abnormal Doppler.

See **Staging of twin-twin transfusion syndrome** (Quintero et al 1999).

Diagnosis of TAPS

Raised MCA PSV (>1.5 MoM) indicating fetal anaemia in one twin **and** MCA PSV <1.0 MoM in the other.

Note: If only one MCA can be ascertained but it is between 1.0 and 1.5 MoM, then there is less concern to achieve the assessment of the second twin.

Diagnosis of sFGR

EFW discordance of >25 percent or EFW of one twin <10th centile.

Weight discordance is calculated as: (EFW larger twin – EFW smaller twin) / EFW larger twin.

Gratacos staging is used for sFGR (types I–III) (**Bennasar et al 2017; Gratacos et al 2007**).

Referral recommendations

Under the **Guidelines for Consultation with Obstetric and Related Medical Services (Referral Guidelines)** (Ministry of Health 2012), women with a multiple pregnancy should be under the care of a specialist obstetrician, though in many cases, care is shared with a midwifery LMC.

A specialist with an interest in high-risk pregnancy should be involved in the following situations:

- high-risk first-trimester screening or anomaly on anatomy scan
- amniotic fluid discordancy
- growth discordancy of >20 percent EFW.

Where there are ultrasound signs of TTTS, early referral within 24 hours to the regional Fetal Medicine unit is recommended for further assessment. This condition can deteriorate quickly, and treatment for severe cases is available only in Auckland.

Reporting alerts

- Open cervix

- New diagnosis of TTTS
- New diagnosis of significant fetal abnormality
- Critically abnormal Doppler

- New diagnosis of TAPS
- New diagnosis of sFGR.

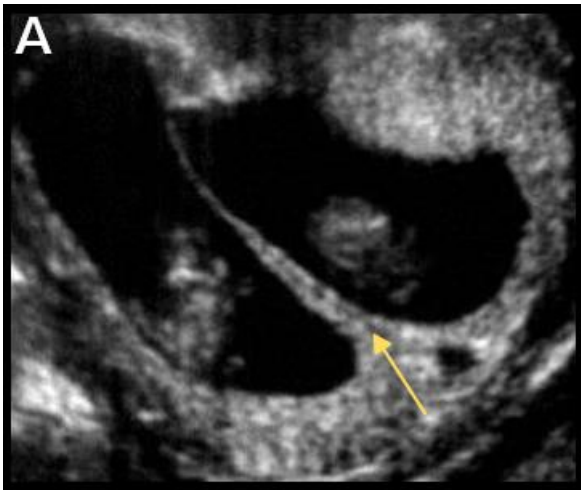
Determining chorionicity and amnionicity in twins

Chorionicity should be ascertained and clearly imaged for future reference at the earliest scan possible (ideally ≤ 14 weeks). If it is too early or not clear, a follow-up scan should be offered.

Dichorionic twins

- Lambda sign (λ) indicates dichorionic diamniotic (DCDA) pregnancy.
- Identification of two separate placentas has a specificity of 100 percent but may not be evident after the first trimester because the placentas often fuse later in gestation.
- Fetuses with different genders are always dizygous and therefore dichorionic.

Image 45

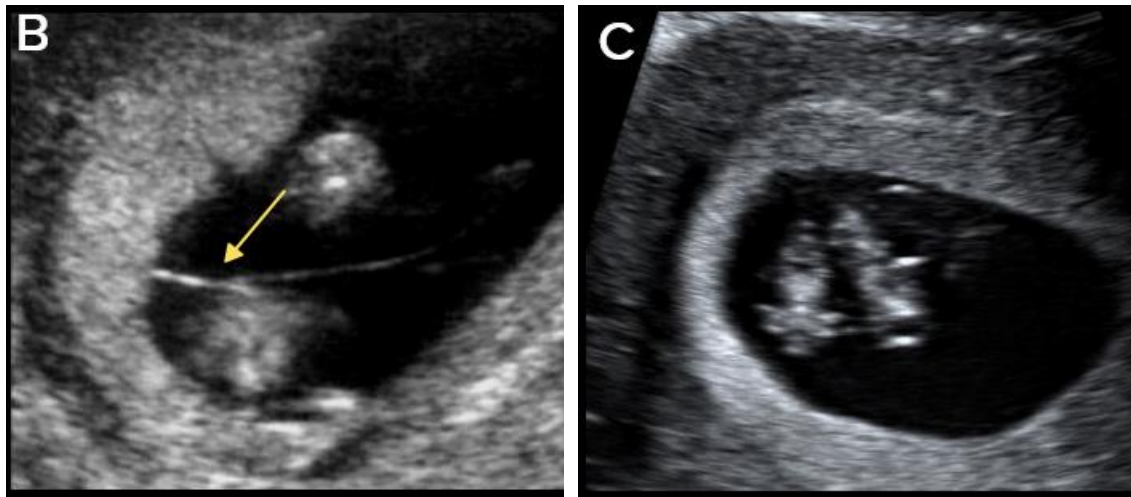


Lambda sign (arrow) indicating DCDA twin pregnancy.

Monochorionic twins

- Tau sign (τ) has a sensitivity of 100 percent and specificity of 98 percent for monochorionic diamniotic (MCDA) pregnancy.
- Thickness of membranes < 1.5 mm or lack of Lambda sign suggests MCDA pregnancy.
- Absence of membranes indicates monochorionic monoamniotic (MCMA) pregnancy (confirm with TV scan if possible).

Image 46



T sign (arrow) indicating MCDA twin pregnancy (B) and absent intertwin membrane (C) in a MCMA twin pregnancy.

Dating

- The largest CRL should be used for dating in twin pregnancy, unless IVF / assisted reproduction, in which case the IVF dates (date of intrauterine insemination or ovum pick-up) should be used.
- Ideally, the pregnancy should be dated by CRL between 10+0 and 12+6 weeks gestation.
- After 13 weeks, dating may be performed using mean HC.

Complications in monochorionic twin pregnancies

All twin pregnancies have increased rates of anomaly, preterm birth (both spontaneous and iatrogenic), pre-eclampsia, sFGR, GDM and complicated delivery, but the rate of complications is significantly increased in monochorionic (MC) twinning, due to placental anastomoses.

Twin-to-twin transfusion syndrome

- Occurs in 10–15 percent of MC twin pregnancies.
- Most commonly occurs between 16–26 weeks gestation and if untreated has a perinatal mortality rate of 80–90 percent.
- Due to placental anastomoses, which cause unidirectional flow along connecting vessels – one twin receives more blood flow than the other.
- Has a poor prognosis, leading to up to 20 percent of all perinatal deaths in twins.
- Discordant amniotic fluid volumes are the initial findings.

Twin anaemia-polycythaemia sequence

- Also due to placental anastomoses
- Usually occurs later in pregnancy
- Has a better prognosis
- Characterised by one twin being anaemic and the other polycythaemic, without the discordant amniotic fluid associated with TTTS.

Selective fetal growth restriction

- Common complication of a MC twin pregnancy
- Due to unequal placental sharing
- Can be associated with a poor outcome if it occurs early in pregnancy
- May occur in combination with TTTS and contributes to difficulties in diagnosis and treatment.

Demise of one twin

- Depending on the gestational age at demise, the surviving twin may be affected by increased rates of:
 - death of co-twin
 - neurologic abnormality (due to ischaemic brain damage)
 - preterm delivery.
- Consider MRI for surviving co-twin (this is a tertiary-level decision).

Monoamniotic twins

- Identical twins that share the same sac.
- Very high-risk pregnancy due to:
 - cord entanglement
 - cord compression
 - TTTS – which is difficult to diagnose due to the single sac.

Twin reversed arterial perfusion (TRAP) sequence

- Also known as acardiac twinning.
- Rare, occurring in 1 percent of MC twin pregnancies.
- One twin is usually structurally normal (the 'pump twin'); the other ('acardiac twin') is abnormal, often consisting of a lower body and lower limbs with absent or rudimentary upper body, head and heart.
- Due to abnormal vascular connections between the twins with arterial flow from the umbilical artery of the pump twin into the acardiac twin – illustrated on colour

Doppler or pulsed wave ultrasound as reversed arterial perfusion within the abnormal twin.

- The pump/normal twin may develop high output cardiac failure.
- Untreated, mortality of the normal/pump twin approaches 50 percent.

Conjoined twins

- Rare
- Occurs in monoamniotic twins
- Classified by the anatomic site at which the twins' bodies are joined, most commonly:
 - thoraco-omphalopagus – fused from upper chest to lower chest
 - thoracopagus – fused from upper thorax to lower abdomen
 - omphalopagus – fused at lower abdomen
 - craniopagus – fused skulls and separate bodies.

References

Abramowicz J, Brezinka C, Salvesen K, et al. 2009. ISUOG statement on the non-medical use of ultrasound, 2009. *Ultrasound Obstet Gynecol* 33: 617. DOI: 10.1002/uog.6389 (accessed 16 May 2019).

Abuhamad A, Chaoui R. 2015. *A Practical Guide to Fetal Echocardiography: Normal and abnormal hearts (3rd edition)*. Philadelphia: Wolters Kluwer.

Agathokleous M, Chaveeva P, Poon LCY, et al. 2013. Meta-analysis of second-trimester markers for trisomy 21. *Ultrasound Obstet Gynecol* 41: 247–61. DOI: 10.1002/uog.12364 (accessed 18 December 2018).

Alfirevic Z, Tang A-W, Collins SL, et al. 2016. Pro forma for ultrasound reporting in suspected abnormally invasive placenta (AIP): an international consensus. *Ultrasound Obstet Gynecol* 47: 276–78. DOI: 10.1002/uog.15810 (accessed 18 December 2018).

ASUM. 2017. *Policies, Standards, and Guidelines: Guidelines for the performance of first trimester ultrasound G02*. Chatswood: Australian Society for Ultrasound in Medicine (ASUM). URL: www.asum.com.au/files/public/SoP/Uploads/OG-SoP.pdf (accessed 16 October 2019).

Bennasar M, Eixarch E, Martinez JM, et al. 2017. Selective intrauterine growth restriction in monochorionic diamniotic twin pregnancies. *Semin Fetal Neonatal Med* 22(6): 376–82. DOI: <https://doi.org/10.1016/j.siny.2017.05.001> (accessed 15 July 2019).

Collins SL, Ashcroft A, Braun T, et al. 2016. Proposal for standardized ultrasound descriptors of abnormally invasive placenta (AIP). *Ultrasound Obstet Gynecol* 47: 271–75. DOI: 10.1002/uog.14952 (accessed 18 December 2018).

Department of Internal Affairs. 2007. *Maternity Services, Notice Pursuant to Section 88 of the New Zealand Public Health and Disability Act 2000: Primary Maternity Services Notice 2007*. Wellington: Department of Internal Affairs. URL: www.health.govt.nz/publication/primary-maternity-services-notice-2007 (accessed 15 January 2019).

Doubilet PM, Benson CB, Bourne T, et al. 2013. Diagnostic criteria for nonviable pregnancy early in the first trimester. Society of Radiologists in Ultrasound Multispecialty Panel on Early First Trimester Diagnosis of Miscarriage and Exclusion of a Viable Intrauterine Pregnancy. *N Engl J Med* 369: 1443–51. DOI: 10.1056/NEJMra1302417 (accessed 28 August 2019).

Gratacos E, Lewi L, Munoz B, et al. 2007. A classification system for selective intrauterine growth restriction in monochorionic pregnancies according to umbilical artery Doppler flow in the smaller twin. *Ultrasound Obstet Gynecol* 30: 28–34. DOI: <http://doi.org/10.1002/uog.4046> (accessed 15 July 2019).

Jauniaux E, Bhide A, Kennedy A, et al. 2018. FIGO consensus guidelines on placenta accreta spectrum disorders: Prenatal diagnosis and screening. FIGO Guidelines. *International Journal of Gynecology and Obstetrics* 140(3): 274–80. DOI: 10.1002/ijgo.12408 (accessed 18 December 2018).

- Matsui H, Mellander M, Roughton M, et al. 2008. Morphological and physiological predictors of fetal aortic coarctation. *Circulation* 118: 1793–801. DOI: 10.1161/CIRCULATIONAHA.108.787598 (accessed 19 December 2018).
- Ministry of Health. 2012. *Guidelines for Consultation with Obstetric and Related Medical Services (Referral Guidelines)*. Wellington: Ministry of Health. URL: www.health.govt.nz/system/files/documents/publications/referral-guidelines-jan12.pdf (accessed 16 May 2019)
- Ministry of Health. 2013. *Antenatal Screening for Down Syndrome and Other Conditions: Guidelines for health practitioners*. Wellington: Ministry of Health. URL: www.nsu.govt.nz/system/files/page/antenatal_screening_for_down_syndrome_and_other_conditions_guidelines_for_health_practitioners.pdf (accessed 16 May 2019).
- Ministry of Health. 2014. *Screening, Diagnosis and Management of Gestational Diabetes in New Zealand: A clinical practice guideline*. Wellington: Ministry of Health. URL: www.health.govt.nz/system/files/documents/publications/screening-diagnosis-management-of-gestational-diabetes-in-nz-clinical-practice-guideline-dec14-v2.pdf (accessed 16 May 2019).
- Ministry of Health. 2015. *Antenatal Screening for Down Syndrome and Other Conditions: Guidelines for nuchal translucency (NT) and crown rump length (CRL) measurements*. Wellington: Ministry of Health. URL: www.nsu.govt.nz/system/files/resources/antenatal_screening_for_down_syndrome_and_other_conditions_-_guidelines_for_nt_and_crl_measurements.pdf (accessed 18 December 2018).
- Ministry of Health. 2018. *Removal of Measurement of Nasal Bone*. Wellington: Ministry of Health. URL: www.nsu.govt.nz/system/files/page/removal-measurements-nasal-bone-mar18.pdf (accessed 15 October 2019).
- Morrison ML, McMahan CJ. 2018. *Congenital Heart Disease in Down Syndrome*. DOI: 10.5772/intechopen.71060 (accessed 12 December 2018).
- National Antenatally Detected Asymptomatic Renal Dilation consensus group. 2017. *Guideline for the Management of Fetal Renal Tract Dilatation: Both antenatal and postnatal*. Auckland: Starship Foundation. URL: www.starship.org.nz/guidelines/renal-national-antenatal-renal-dilation-guideline/ (accessed 22 August 2019).
- Necas M, Bagnall C. 2014. *Fetal Heart Assessment during the 18–20 Week Anatomy Scan*. Wellington: NZMFMN and ASUMNZ. URL: www.healthpoint.co.nz/downloadinfo,138318,otherList,3p0cq1vh8y11qwe1gp0j.do (accessed 16 October 2019).
- Nicolaides KH, Sebire NJ, Snijders RJM, et al. 2001. The 11–14 weeks scan: Chapter 1. *Diploma in Fetal Medicine & ISUOG Educational Series*. The Fetal Medicine Foundation URL: www.sonoworld.com/client/fetus/html/11-14week/chapter-01/images/fig01-09.gif (accessed 15 January 2019).

Nicolaides K, Rizzo G, Hecher K, et al. 2002. Doppler in Obstetrics. *Diploma in Fetal Medicine & ISUOG Educational Series*. London: The Fetal Medicine Foundation. URL: www.fetalmedicine.org/var/uploads/Doppler-in-Obstetrics.pdf (accessed 19 December 2018).

NSU. 2019. *Position Statement on Non-Invasive Prenatal Screening (NIPS)*. Wellington: National Screening Unit. URL: www.nsu.govt.nz/health-professionals/antenatal-screening-down-syndrome-and-other-conditions/procedures-guidelines-2 (accessed 11 September 2019).

NZMFMN. 2010. *Fetal Ventriculomegaly*. New Zealand Maternal Fetal Medicine Network. URL: www.healthpoint.co.nz/downloadinfo,138318,otherList,pl6j8hw0se7gva812dft.do (accessed 12 December 2018).

NZMFMN. 2011a. *Cleft Lip/Palate*. New Zealand Maternal Fetal Medicine Network. URL: www.healthpoint.co.nz/downloadinfo,138318,otherList,648s8oyefmcex84qwoffv.do (accessed 12 December 2018).

NZMFMN. 2011b. Routine measurement of cervical length at time of mid trimester anomaly scan in all women. *Statement from the New Zealand Maternal Fetal Medicine Network*. New Zealand Maternal Fetal Medicine Network. URL: www.healthpoint.co.nz/downloadinfo,138318,otherList,uhiiaajlrqq3pwc9ku1x0.do (accessed 12 December 2018).

NZMFMN. 2012. *Nonimmune Hydrops Fetalis*. New Zealand Maternal Fetal Medicine Network. URL: www.healthpoint.co.nz/downloadinfo,138318,otherList,o3n9v6qvvvf8x79jo1ro.do (accessed 12 December 2018).

NZMFMN. 2014a. *Guideline for the Management of Suspected Small for Gestational Age Singleton Pregnancies and Infants after 34 Weeks' Gestation*. New Zealand Maternal Fetal Medicine Network. URL: www.healthpoint.co.nz/downloadinfo,138318,otherList,qrxtiaam6ix6f02q5yd3.do (accessed 12 December 2018).

NZMFMN. 2014b. *New Zealand Obstetric Doppler Guideline*. New Zealand Maternal Fetal Medicine Network. URL: www.healthpoint.co.nz/downloadinfo,138318,otherList,x76zlpuxt1wvlbkynmo2.do (accessed 19 December 2018).

NZMFMN. 2015a. *Congenital Diaphragmatic Hernia*. New Zealand Maternal Fetal Medicine Network. URL: www.healthpoint.co.nz/downloadinfo,138318,otherList,pk01uxz2jj1fgqcyn2bj.do (accessed 12 December 2018).

NZMFMN. 2015b. *Fetal Arrhythmia*. New Zealand Maternal Fetal Medicine Network. URL: www.healthpoint.co.nz/downloadinfo,138318,otherList,1k9mhd7793sp3619pppw.do (accessed 12 December 2018).

- NZMFMN. 2015c. *Fetal Echogenic Bowel*. New Zealand Maternal Fetal Medicine Network. URL: www.healthpoint.co.nz/downloadinfo,138318,otherList,ptz6kym3w4i9fyaac9f.do (accessed 12 December 2018).
- NZMFMN. 2015d. *Gastroschisis*. New Zealand Maternal Fetal Medicine Network. URL: www.healthpoint.co.nz/downloadinfo,138318,otherList,fhqovi83pp1hc6kqdfxf.do (accessed 12 December 2018).
- NZMFMN. 2015e. *Lethal Skeletal Dysplasia*. New Zealand Maternal Fetal Medicine Network. URL: www.healthpoint.co.nz/downloadinfo,138318,otherList,mnfa7ptpwu2aafchjggj.do (accessed 12 December 2018).
- NZMFMN. 2015f. *Multiple Pregnancy*. New Zealand Maternal Fetal Medicine Network. URL: www.healthpoint.co.nz/downloadinfo,138318,otherList,bsvybr0apiyuturkcrf3.do (accessed 12 December 2018).
- NZMFMN. 2016. *NZMFMN Statement on the Use of Non-Invasive Prenatal Testing (NIPT)*. New Zealand Maternal Fetal Medicine Network. URL: www.healthpoint.co.nz/downloadinfo,138318,otherList,qsn460mw291tn3q3pi35.do (accessed 17 December 2018).
- NZMFMN. 2017. *Umbilical Vein Varix*. New Zealand Maternal Fetal Medicine Network. URL: www.healthpoint.co.nz/downloadinfo,138318,otherList,fwg10vzis6f7il7k628s.do (accessed 12 December 2018).
- Preisler J, Kopeika J, Ismail L, et al. 2015. Defining safe criteria to diagnose miscarriage: prospective observational multicentre study. *BMJ* 351:h4579. DOI: 10.1136/bmj.h4579 (accessed 22 July 2019).
- Quintero RA, Morales WJ, Allen MH, et al. 1999. Staging of twin-twin transfusion syndrome. *J Perinatol* 19(8 Pt 1): 550–55. DOI: 10.1038/sj.jp.7200292 (accessed 16 October 2019).
- RANZCOG. 2016. *Vasa Praevia*. Melbourne: The Royal Australian and New Zealand College of Obstetricians and Gynaecologists. URL: [https://ranzcoг.edu.au/RANZCOG_SITE/media/RANZCOG-MEDIA/Women%27s%20Health/Statement%20and%20guidelines/Clinical-Obstetrics/Vasa-praevia-\(C-Obs-47\)-Review-July-2016_3.pdf?ext=.pdf](https://ranzcoг.edu.au/RANZCOG_SITE/media/RANZCOG-MEDIA/Women%27s%20Health/Statement%20and%20guidelines/Clinical-Obstetrics/Vasa-praevia-(C-Obs-47)-Review-July-2016_3.pdf?ext=.pdf) (accessed 15 October 2019).
- Tan J, Silverman NH, Hoffman JI, et al. 1992. Cardiac dimensions determined by cross-sectional echocardiography in the normal human fetus from 18 weeks to term. *Am J Cardiol* 70(18):1459–67. DOI: 10.1016/0002-9149(92)90300-n (accessed 15 July 2019).
- Westerway SC, Davison A, Cowell S. 2000. Ultrasonic fetal measurements: new Australian standards for the new millennium. *Aust NZ J Obstet Gynaecol* 40(3): 297–302. DOI: 10.1111/j.1479-828X.2000.tb03338.x (accessed 15 July 2019).

Appendix 1:

Ultrasound scan codes and indications

Current codes for claiming for ultrasound scans through the New Zealand Public Health and Disability Act 2000 Primary Maternity Services Notice 2007.

Code	Clinical indication	Comment
TA	Threatened abortion	Scan at time of bleeding. Serial scans may be necessary if bleeding persists.
EP	Suspected ectopic pregnancy	For example, previous tubal surgery, PID or ectopic. Suggestive symptoms (for example, abdominal pain).
PM	Pelvic mass in pregnancy	Any palpable abnormality in early pregnancy.
UD	Uterus not equal to dates	If discrepancy >4 weeks, or discrepancy in amniotic fluid.
BA	Before booking chorionic villus sampling (CVS) or amniocentesis or Nuchal Translucency	When unsure dates.
CT	Consideration of termination	
NT	Dating and early evaluation for chromosomal abnormality	Nuchal translucency assessment at 11–13+6 weeks, assessment for gestational age, diagnosis of multiple pregnancy.
NF	Early evaluation for chromosomal abnormality follow-up	In cases where the first scan was technically unsuccessful.
AN	Anatomy	Scan to confirm dates, assess foetal anatomy and placental position. Performed at 18–20 weeks ideally.
AF	Anatomy follow-up	In cases where the first scan was technically unsuccessful.
GR	Suspected growth abnormality (IUGR or macrosomia)	Clinical suspicion of abnormal growth of foetus (IUGR or macrosomia) or abnormal volume of amniotic fluid.
GF	Suspected growth abnormality (IUGR or macrosomia) follow-up	To assess growth trend (2 weeks after GR scan).
PL	Check placenta	To check placental site at around 36 weeks.
AH	Antepartum haemorrhage	Bleeding in pregnancy. If serial scans are required, refer to secondary maternity services.

Code	Clinical indication	Comment
AP	Abdominal pain	Abdominal pain in pregnancy.
MP	Malpresentation	To assess fetal position and size after 36 weeks.
FC	Suspected foetal compromise	Significant reduction in foetal movements.
FD	Suspected intrauterine foetal death	
PP	Maternal postpartum	For suspected retained products or postpartum bleeding.

Source: Department of Internal Affairs 2007

Appendix 2:

Low gestational sac in the first trimester with previous caesarean section

The presence of a sac located in an abnormally low position within the uterus in the first trimester in a woman who has had one or more caesarean sections should prompt careful further review, including transvaginal (TV) scanning, if possible.

The differential diagnosis includes a normally developing but low sac that shows normal subsequent development on follow-up scans, an inevitable miscarriage (which appears avascular), scar ectopic or abnormally adherent trophoblast/placenta (early evidence of placenta accreta/abnormally implanted placenta).

Early placenta accreta / abnormally implanted trophoblast / placenta

The trophoblast is directly implanted over the scar. These cases may be very difficult to differentiate from scar ectopic pregnancies.

A TV ultrasound scan is recommended to assess location of the pregnancy.

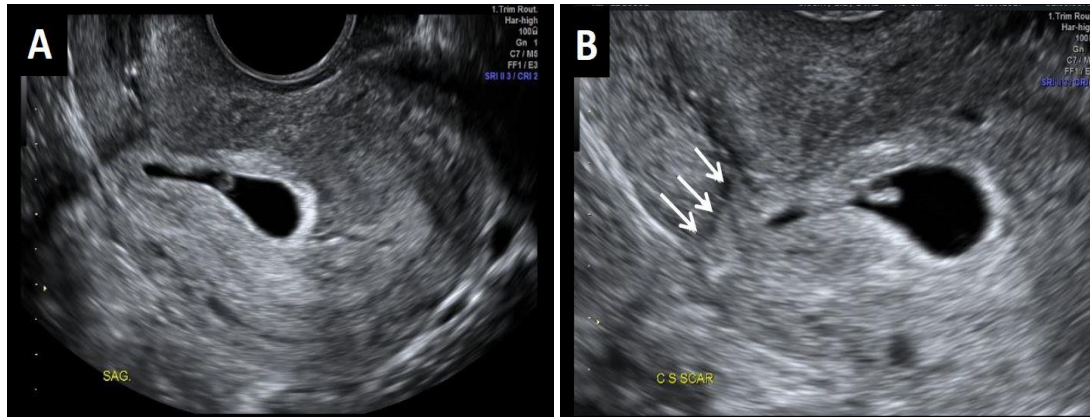
Implantation into the previous caesarean section scar can be diagnosed when:

1. the gestational sac is low lying and located anteriorly or deviated towards the scar, within the lower uterus, at the level of the internal os
2. there is increased peritrophoblastic or periplacental vascularity on colour Doppler examination and high-velocity (peak velocity >20 cm/s), low-impedance (pulsatility index <1) flow velocity waveforms on pulsed Doppler, in keeping with functional trophoblastic/placental circulation
3. there is negative 'sliding organs sign', in the first trimester defined as the inability to displace the gestational sac from its position at the level of the internal os using gentle pressure applied by the TV probe.

The scar may be thin, or deficient, with a visible gap in the myometrium of the anterior uterine wall. The gestational sac may bulge towards the bladder in these cases.

From about 16 weeks, irregular vascular sinuses appear, with turbulent flow. The bladder wall may appear interrupted or have small bulges of the placenta into the bladder space. Absence of the normal retroplacental 'clear zone' (the echolucent space between the placenta and myometrium) may be unreliable. Colour Doppler may show placental bed hypervascularity and that some of the placental sinuses traverse the uterine wall.

Image A2.1



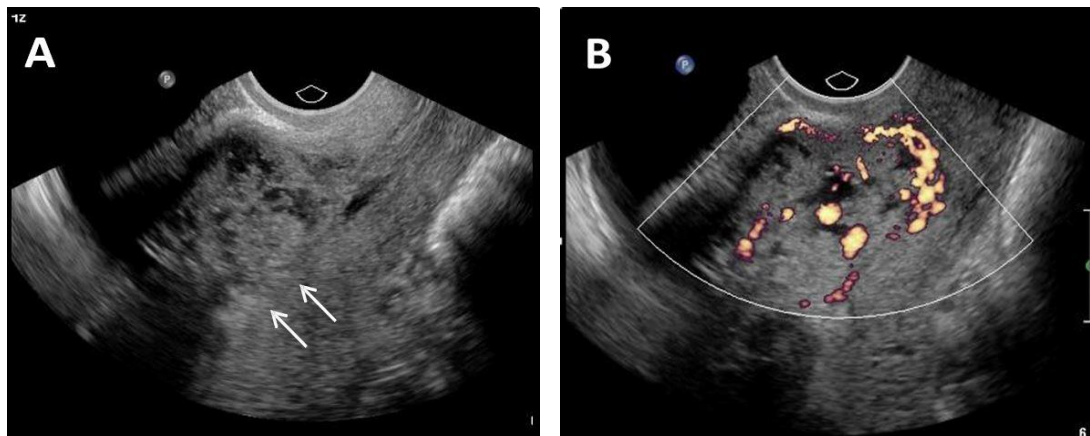
Low implantation of the gestational sac in a retroverted uterus (TV scan) **(A)**, with the sac deviated anteriorly into the scar, arrows **(B)**, suspicious for early accreta / abnormal trophoblast implantation.

Scans later in pregnancy showed complete placenta previa and accreta.

Caesarean scar ectopic pregnancy

The pregnancy is entirely contained within the myometrial confines of the scar, with no part within the cavity itself, unlike in first-trimester cases of abnormally implanted trophoblast/placenta accreta.

Image A2.2



Abnormal trophoblastic tissue implanted entirely within the confines of the caesarean section scar, separate from the endometrial cavity (arrows), in greyscale **(A)**, and colour Doppler **(B)**.

Appendix 3: Ectopic pregnancy location

Tubal ectopic

- Most common
- Adnexal mass ± gestational sac
- May demonstrate peripheral vascularity
- Ectopic angle is the most common site (between the uterus and ovary).

Non-tubal ectopic pregnancy

- Interstitial/cornual ectopic: mass or gestational sac in the cornual region of the uterus, outside the endometrial cavity
- Scar ectopic: mass or gestational sac related to the caesarean section scar
- Cervical ectopic: mass or gestational sac within the endocervical canal
- Ovarian ectopic: mass or gestational sac within the ovary. This is a rare condition (less than 1 percent of ectopics) and needs to be differentiated from the much more common **corpus luteum** (see below)
- Abdominal and intramural ectopics are rare.

Heterotopic pregnancy

- A rare condition of co-existing intrauterine and ectopic pregnancy
- Rare (0.6–2.5 per 10,000 pregnancies)
- Increased incidence in women undergoing IVF or ovulation induction
- If suspected sonographically, then specialist opinion is required.

Corpus luteum of pregnancy

- Seen within the ovary in early pregnancy
- May be single or multiple
- Appearances may be those of a thin- or thick-walled cyst or solid isoechoic nodule with peripheral ring vascularity
- An exophytic corpus luteum on the periphery or surface of the ovary may mimic an ectopic pregnancy. It may be difficult to differentiate a corpus luteum from an ectopic pregnancy.

Helpful sonographic features include:

- no internal yolk sac or embryo
- isoechoic to the ovary
- moves with the ovary on probe pressure.

If there is an empty uterus and indeterminate ultrasound findings, a follow-up scan should be recommended (in 5–7 days, or earlier if there is interval clinical concern regarding ectopic pregnancy). An ectopic pregnancy or a normal intrauterine pregnancy may often become visible on the follow-up scan.

Appendix 4: Findings in ectopic pregnancy

Pseudogestational sac

- Occurs in 5 percent of ectopic pregnancies
- Irregular fluid collection, centrally within endometrial cavity
- Irregular shape
- No double decidual reaction
- No yolk sac
- May be difficult to differentiate from early intrauterine pregnancy or decidual cyst
- A decidual cyst and early gestational sac are usually eccentric
- A pseudosac is central and often contains blood clot or mobile debris.

Free fluid or haemoperitoneum

- Describe free fluid as simple or complex.
- Quantify the amount, that is, small, moderate, large, deepest pocket, confined to pelvis, present in upper abdomen, etc. Document fluid at or above the uterine fundus.
- If small amount of simple fluid, ectopic is likely not ruptured.
- A small amount of complex fluid does not always indicate rupture. This can be due to leak from the end of the tube, but early rupture is not excluded.
- A moderate to large amount of complex fluid / haemoperitoneum is suggestive of rupture.

Appendix 5:

Non-invasive prenatal screening

Non-invasive prenatal screening (NIPS) is a way of determining the risk of the fetus having certain chromosomal abnormalities. Small fragments of circulating DNA in a pregnant woman's blood are analysed. These fragments are free floating and not within cells, unlike most DNA, which is found inside a cell's nucleus. They are therefore known as cell-free DNA (cfDNA). During pregnancy, a mixture of cfDNA from the woman's cells and cells from the placenta are found in the maternal blood. Evaluation of the cfDNA from the placenta allows screening for certain genetic abnormalities. NIPS can be performed from the 10th week of pregnancy.

NIPS can be used to screen for chromosomal disorders such as **trisomy 21** (Down syndrome), **trisomy 18** (Edwards syndrome) and **trisomy 13** (Patau syndrome). The accuracy of the test changes depending on the disorder in question.

NIPS is not appropriate when there is fetal abnormality or significantly raised nuchal translucency (NT).

Note: NIPS is not part of the publicly funded antenatal screening for Down syndrome and other conditions. NIPS is currently a user pays, non-scheduled test. If this changes, this section will be updated as appropriate.

- If a woman chooses to have NIPS (non-funded) as their primary screening test, knowledge of dates is required.
- The woman should still proceed with a scan at 12 to 14 weeks gestation for assessment of fetal anatomy and for other benefits. However, NT measurement (and combined screening assessment) is not recommended in women with a previous NIPS result (Note: The NT should still be measured if it appears increased, and Fetal Medicine or other local equivalent specialist referral should be offered if NT is ≥ 3.5 mm.).
- A woman may choose to have NIPS (non-funded) following combined screening assessment.

For further information, see:

- the NSU's ***Position Statement on Non-Invasive Prenatal Screening (NIPS)*** (NSU 2019)
- the ***NZMFMN Statement on the use of Non-Invasive Prenatal Testing (NIPT)*** (NZMFMN 2016)
- the webpage for the United States Department of Health and Human Services, National Institutes of Health (NIH): **Genetics Home Reference: What is noninvasive prenatal testing (NIPT) and what disorders can it screen for?**

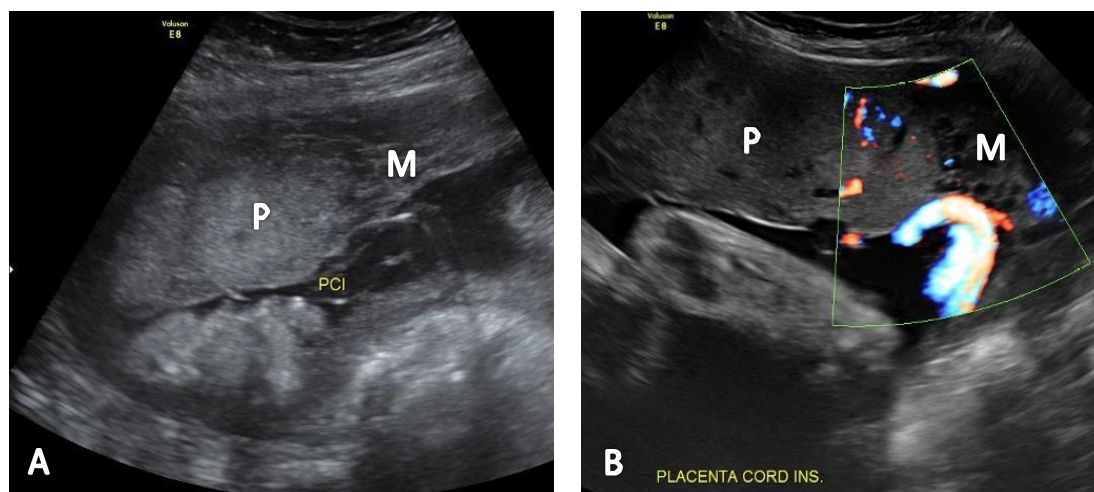
Appendix 6:

Placental anomalies

Marginal cord insertion

- The umbilical cord inserts into the margin of the placenta, usually defined as within 20 mm of the placental edge (although sometimes defined as < 10 mm).
- Occurs in approximately 7 percent of singleton pregnancies but about 25 percent of twin pregnancies (particularly monochorionic twins).
- Occasionally a marginal cord insertion may progress into velamentous due to trophotropism later in the pregnancy.
- It may be associated with complications, such as fetal growth restriction and preterm birth.
- Follow-up growth assessment may be required.

Image A6.1



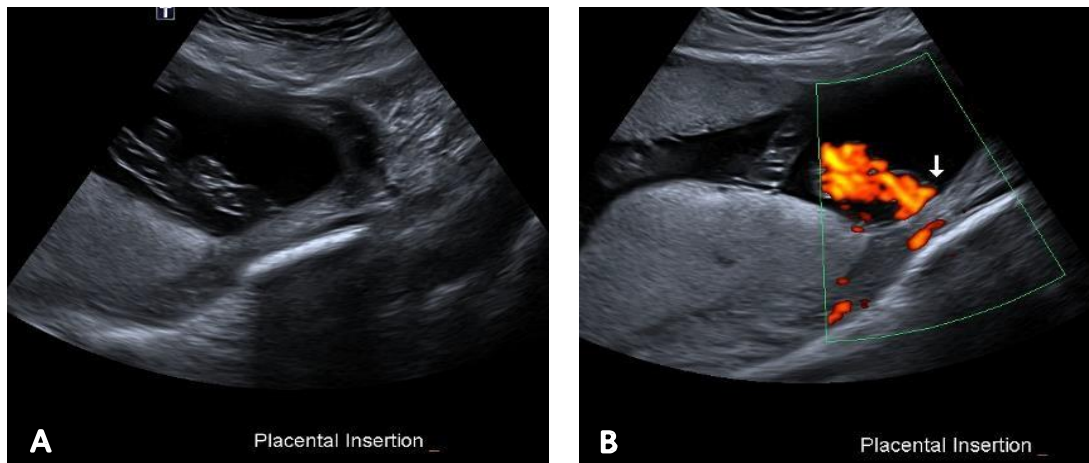
Marginal cord insertion on greyscale **(A)** and colour Doppler **(B)** imaging.

Placenta **(P)**, myometrium **(M)**.

Velamentous cord insertion

- In this condition, the umbilical cord inserts into the fetal (chorioamniotic) membranes, coursing within the membranes to the placenta (between the amnion and the chorion). The exposed vessels are not protected by Wharton's jelly and are vulnerable to rupture.
- Velamentous cord insertion has been associated with an increased risk of adverse perinatal outcomes and is associated with vasa previa (where fetal vessels traverse the internal os in front of the leading fetal part); a condition that is associated with high perinatal mortality when not diagnosed prenatally.
- It may also be associated with placenta previa earlier in pregnancy.
- Abnormal cord insertion may be associated with fetal growth restriction and intrauterine fetal demise.
- There is an increased incidence in twin pregnancies, particularly monochorionic twins.
- Growth surveillance is recommended.

Image A6.2



Velamentous cord insertion on greyscale imaging (A) and with colour Doppler (B).

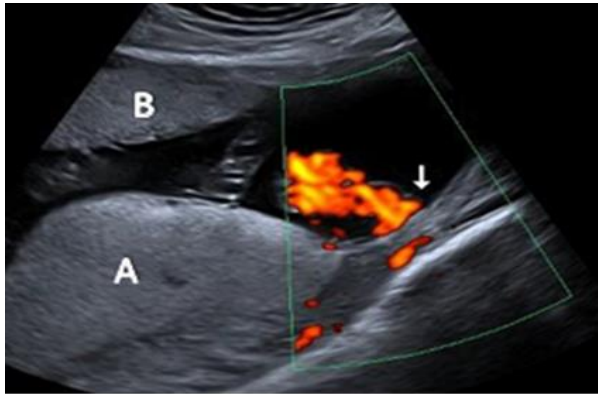
Succenturiate lobe

- A variant in placental morphology, when there is one or more smaller accessory placental lobe separate from the main disc of the placenta.
- Occurs in approximately 2 in every 1,000 pregnancies.
- When a succenturiate lobe is identified, it is important to assess for the location of connecting vessels, and particularly, vasa previa.
- In a bilobed placenta, the two lobes are of similar size.

Associations/complications

- Type II vasa previa
- Increased incidence of postpartum haemorrhage due to retained placental tissue.

Image A6.3

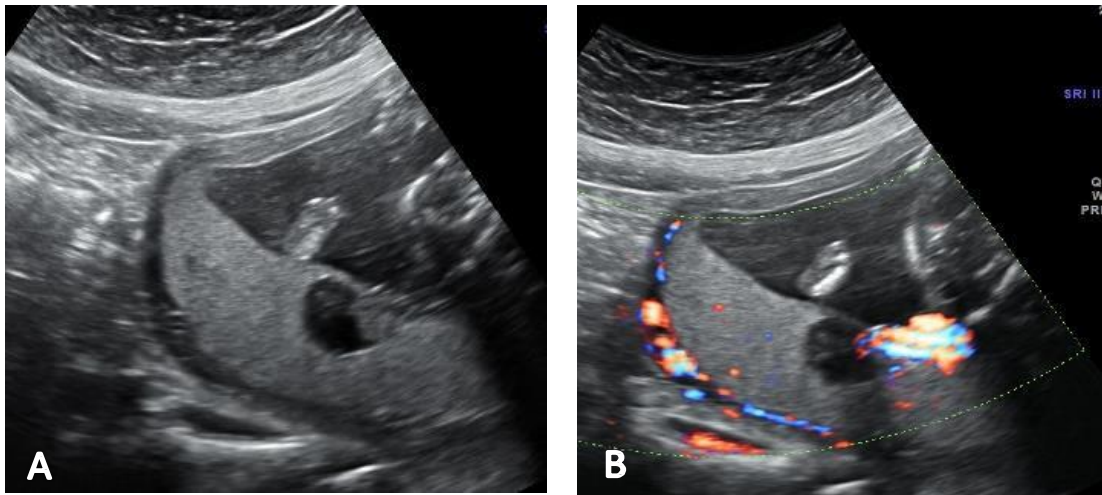


Main placental lobe posteriorly (**A**) and smaller anterior succenturiate lobe (**B**), associated with a velamentous cord insertion.

Chorioangioma

- Benign tumour within the placenta
- Occurs in approximately 0.5–1 percent of pregnancies
- Most commonly diagnosed in the second trimester
- Usually asymptomatic, unless large
- On ultrasound, the lesion is a relatively well-defined hypo- or hyperechoic mass distinct from adjacent placenta, typically near the cord insertion. Internal vascularity may be evident on colour Doppler examination
- Large lesions (>5 cm), may be associated with complications such as polyhydramnios, preterm labour, fetal cardiomegaly, growth restriction, pre-eclampsia or abruption.

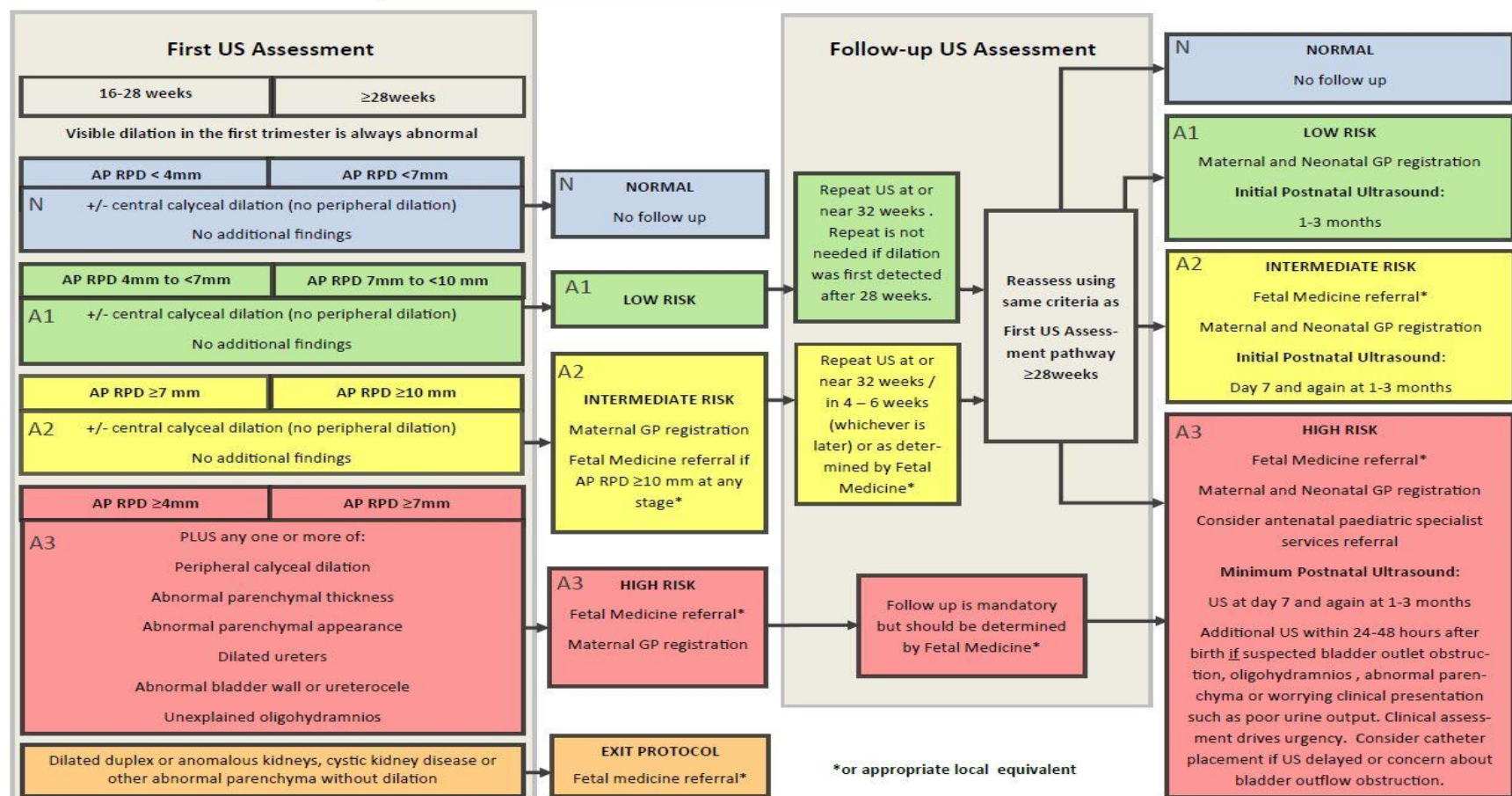
Image A6.4



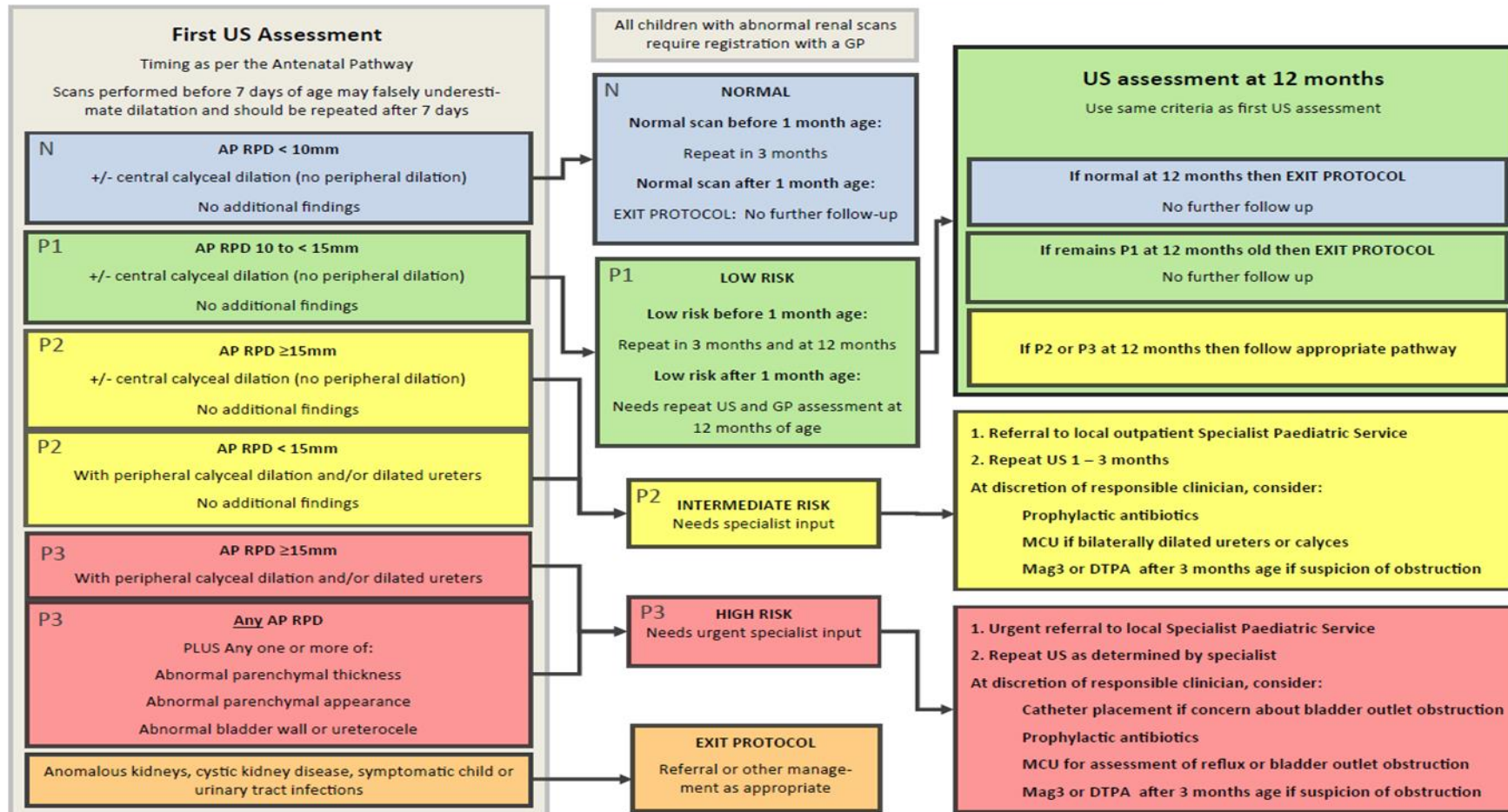
Heterogeneous hypoechoic lesion within the posterior placenta on greyscale imaging (**A**) and with colour Doppler (**B**), showing its location adjacent to the placental cord insertion.

Appendix 7: Fetal renal tract dilation charts

Management of Fetal Renal Tract Dilation: Antenatal v1.0 Feb 2017



Management of Fetal Renal Tract Dilatation: Postnatal v1.0 Feb 2017



Source: National Antenatally Detected Asymptomatic Renal Dilatation Consensus Group 2017.

Appendix 8: Anatomic locations of ventricular septal defects

The **inlet septum** separates the two atrioventricular (AV) valves.

The **outlet septum** includes the conal and infundibular septum and is the region below the arterial valves and above the crista supraventricularis.

The **membranous septum** is the thin portion in the left ventricular outflow tract (LVOT) just beneath the aortic valve and under the crista supraventricularis.

The **muscular** septum is the thickest portion of the septum, extending from the tricuspid valve attachments to the apex.

Perimembranous ventricular septal defects

Located in the outflow tract beneath the aortic valve and under the supraventricular crest. May be sub-classified as:

- perimembranous inlet
- perimembranous outlet
- perimembranous muscular.

Outlet ventricular septal defects

Located under the pulmonary valve and above the supraventricular crest.

Muscular ventricular septal defects

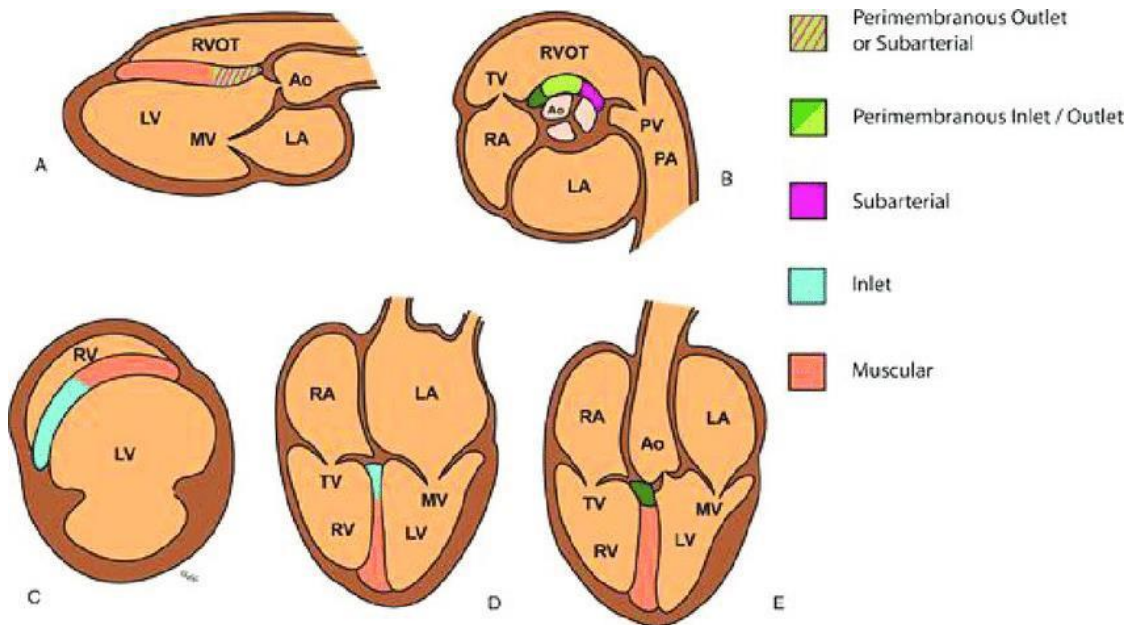
Located in the muscular septum, may be mid-muscular, apical or multiple ('Swiss cheese' septum).

Inlet ventricular septal defects

Located posterior to the septal leaflet of the tricuspid valve. Visualised in four-chamber (4Ch) view near the AV valves. May be difficult to differentiate from a mild complete or partial atrioventricular septal defect (AVSD).

Drop-out artefact on apex up greyscale imaging and colour Doppler 'bleeding' artefact can simulate an inlet ventricular septal defect (VSD). The diagnosis can be aided by assessing in a lateral or transverse plane.

Figure A8.1: Diagrammatic representation of possible VSD locations on standard echo views



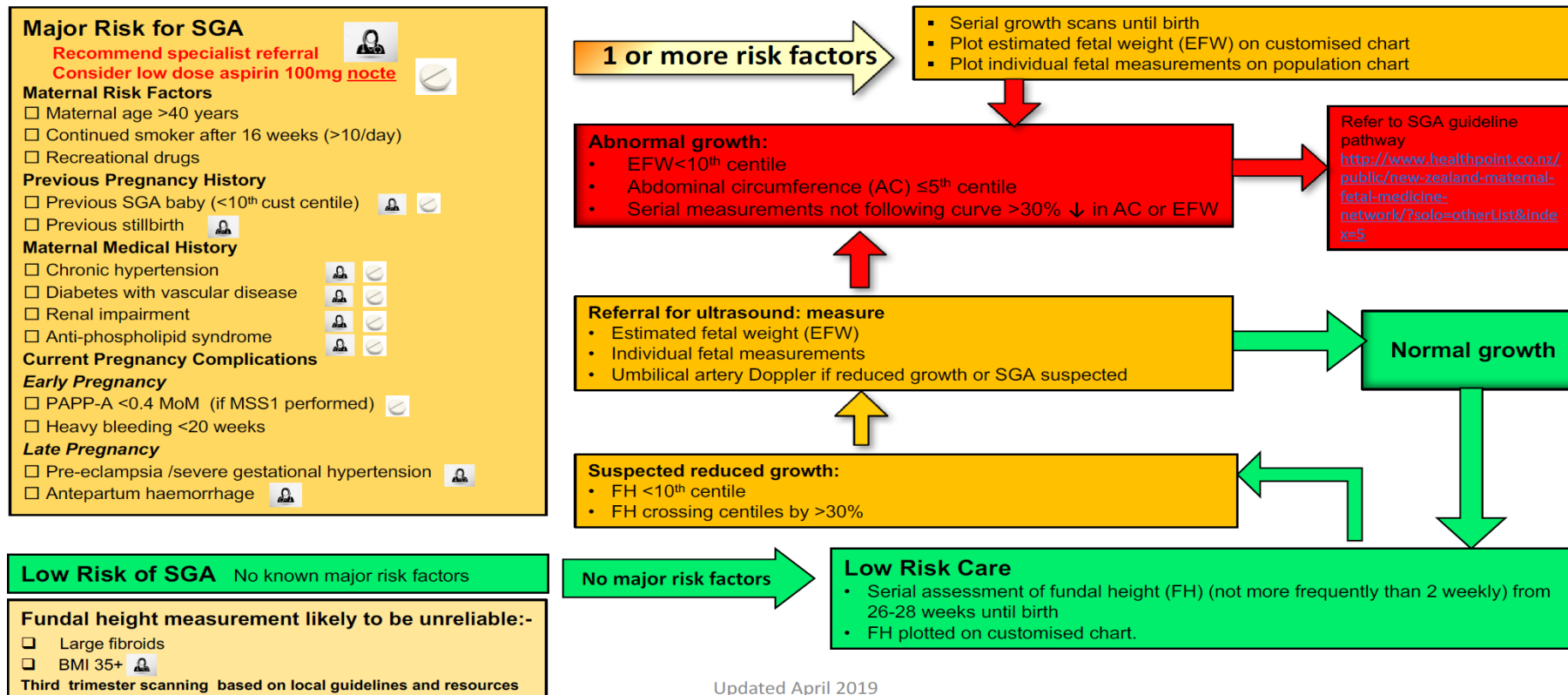
(A) long-axis view, (B) short-axis view at aortic valve level, (C) short-axis view through ventricles, (D) 4Ch view, (E) LVOT view.

Source: Morrison and McMahon 2018.

Appendix 9: SGA scanning schedule

Algorithm & SGA Risk Assessment Tool for New Zealand: Screening and assessment of fetal growth in singleton pregnancies

Adapted from NHS England stillbirth 'care bundle' and based on NZ MFM SGA Guideline



Suggested Schedule of Growth Scans Depending on Local Resources / Guidelines

High risk early onset SGA* e.g. severe medical, previous SGA birth <34wk or stillbirth, ↓ PAPP-A	High risk late onset SGA * e.g. previous SGA born ≥ 34 wk, mild chronic hypertension, age >40	Moderate risk late onset SGA* e.g. smoke >10/day or FH measurement likely to be unreliable (BMI 35+, fibroids)
Monthly growth scans from 24 weeks' to birth Consider uterine artery Doppler at 20 or 24wks	Monthly growth scans from 28-30 weeks' to birth e.g. 30, 34, 38 weeks	Scan 30-32 & 36-38 weeks'
SGA or poor interval growth EFW < 10 th centile Abdominal circumference (AC) ≤ 5 th centile Serial measurements (AC or EFW) cross centiles by > 30%		
Fortnightly scans until birth. Plot individual measurements and estimated fetal weight (EFW) on customised chart. Manage as per NZMFM SGA Guideline http://www.healthpoint.co.nz/public/new-zealand-maternal-fetal-medicine-network/?solo=otherList&index=5		
* Early onset SGA=SGA baby born <34 weeks, late onset SGA = SGA baby born ≥34 weeks Updated April 2019		

Source: Reproduced with permission from Professor Lesley McCowan. URL: www.gestation.net/NewZealandalgorithm.htm