



Key Surgically Relevant Anatomy of the Medial and Lateral Aspects of the Knee

Suhas P. Dasari, MD, Benjamin Kerzner, BS, Luc M. Fortier, BA, Safa GURSOY, MD, PhD, and Jorge Chahla, MD, PhD

Understanding the relationships of the medial and lateral aspects of the knee has a critical clinical role for patient care. These anatomical relationships are put into biomechanical and surgical context as an improved understanding of these relationships can guide surgeons in choosing the optimal reconstructive and/or repair technique for a given injury to the knee. The purpose of this review is to qualitatively and quantitatively describe the bony, soft tissue, and neurovascular anatomy in relation to surrounding anatomical structures and outline their clinical significance as it relates to surgical intervention for complex lateral and medial sided injuries of the knee.

Oper Tech Sports Med 30:150908 © 2022 The Author(s). Published by Elsevier Inc. This is an open access article under the CC BY-NC-ND license (<http://creativecommons.org/licenses/by-nc-nd/4.0/>)

KEYWORDS Posterolateral corner, posteromedial corner, medial collateral ligament, fibular collateral ligament, posterior oblique ligament, popliteal tendon, politeofibular ligament

Introduction

A strong understanding of the key surgical anatomy around the knee is critical. Both the medial and lateral aspects of the knee have received interest in the orthopaedic community due to the high incidence of medial collateral ligament injuries as well as the growing understanding of posterolateral corner injuries.^{1,2} A broad and deep appreciation of the anatomical relationships of bony, soft tissue, and neurovascular structures of the medial and lateral side of the knee is invaluable for surgeons attempting to restore native anatomy and return patients to work, sport, and an improved quality of life. In the following review, we quantitatively and qualitatively describe the anatomy in relation to surrounding anatomical structures and outline their clinical significance as it relates to surgical intervention for complex lateral and medial sided injuries of the knee.

Medial Aspect of the Knee

The medial aspect of the knee and its associated stabilizing structures play an important role in knee joint stability (Fig. 1). These structures are commonly injured during multiligament knee injuries and may require surgical repair or reconstruction to adequately restore proper knee kinematics.³⁻⁵ Consequently, to ensure successful outcomes, a strong understanding of the anatomic landmarks and attachment points are crucial in optimizing the surgical approach, tunnel preparation, and anatomic placement of grafts.^{6,7}

Historically, the capsuloligamentous complex of the medial knee was divided into 3 distinct layers: superficial, middle, and deep.⁸ The superficial layer is comprised of the sartorius muscle and deep fascia; the middle layer is comprised of the superficial medial collateral ligament (sMCL), posterior oblique ligament (POL), medial patellofemoral ligament, medial patellar retinaculum, and the semimembranosus; and the deep layer is comprised of the deep MCL (dMCL), knee joint capsule, and the coronary ligaments.¹

Bony Landmarks

There are 3 key bony prominences about the medial aspect of the knee that are helpful in identifying surgical landmarks for

Department of Orthopaedic Surgery, Rush University Medical Center, Chicago, IL.

Address reprint requests to Jorge Chahla, Division of Sports Medicine, Rush University Medical Center, Midwest Orthopaedics at Rush, Chicago, IL
E-mail: Jorge.Chahla@rushortho.com

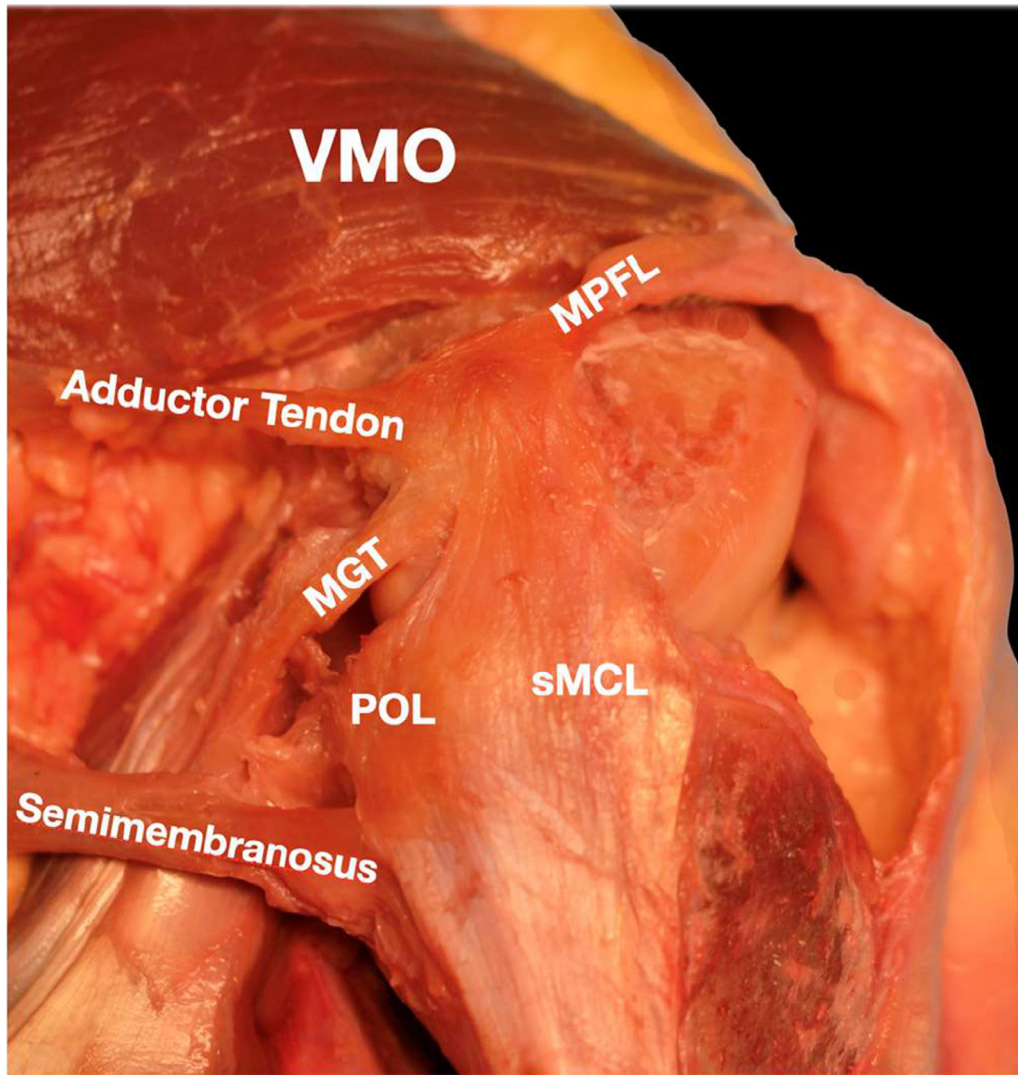


Figure 1 An illustration demonstrating the key surgically relevant anatomy of the medial aspect of the knee. VMO, vastus medialis obliquus; sMCL, superficial medial collateral ligament; MPFL- medial patellofemoral ligament; MGT, medial gastrocnemius tendon; POL, posterior oblique ligament.

medial soft tissue injuries: the medial epicondyle, the adductor tubercle, and the gastrocnemius tubercle.⁵ The medial femoral epicondyle is the most anterior and distal bony prominence over the medial femoral condyle.¹ The second bony prominence, the adductor tubercle, is located along a bony ridge termed the medial supracondylar line and it is approximately 12.6 mm proximal and 8.3 mm posterior to the medial epicondyle.¹ The adductor tubercle is in close relation to where the distal attachment of the adductor magnus tendon is found and represents the “lighthouse” of the medial side of the knee.⁹ The gastrocnemius tubercle is the third tubercle. It is located slightly distal and posterior to the adductor tubercle and is adjacent to an osseous depression where the medial gastrocnemius tendon originates from.¹ More specifically, the gastrocnemius tubercle is located 6.0 mm proximal and 13.7 mm posterior to the medial epicondyle, and 9.4 mm distal and 8.7 mm posterior to the adductor tubercle.¹

Pes Anserinus

The sartorius, gracilis, and semitendinosus tendons are collectively known as the pes anserinus and coalesce together to insert on the anteromedial aspect of the proximal tibia (Fig. 2).^{1,10,11} The sartorius inserts most proximally and anteriorly, followed by the gracilis tendon in the middle, and the semitendinosus tendon most distally and posteriorly.^{5,12} On average, the width of the sartorius at the tibial attachment point is 8.0 mm (range, 5.7-9.3 mm), 8.4 mm (range, 6.2-11.4 mm) for the gracilis, and 11.3 mm (range, 7.5-15.8 mm) for the semitendinosus.¹ The semitendinosus tendon was measured to be the longest in length at 146.49 ± 12.83 mm, followed by the gracilis tendon at 124.62 ± 8.86 mm, and the sartorius tendon at 44.09 ± 4.29 mm.¹²

These 3 tendons make up the roof of the pes anserine bursa. Despite the gracilis and semitendinosus tendons being

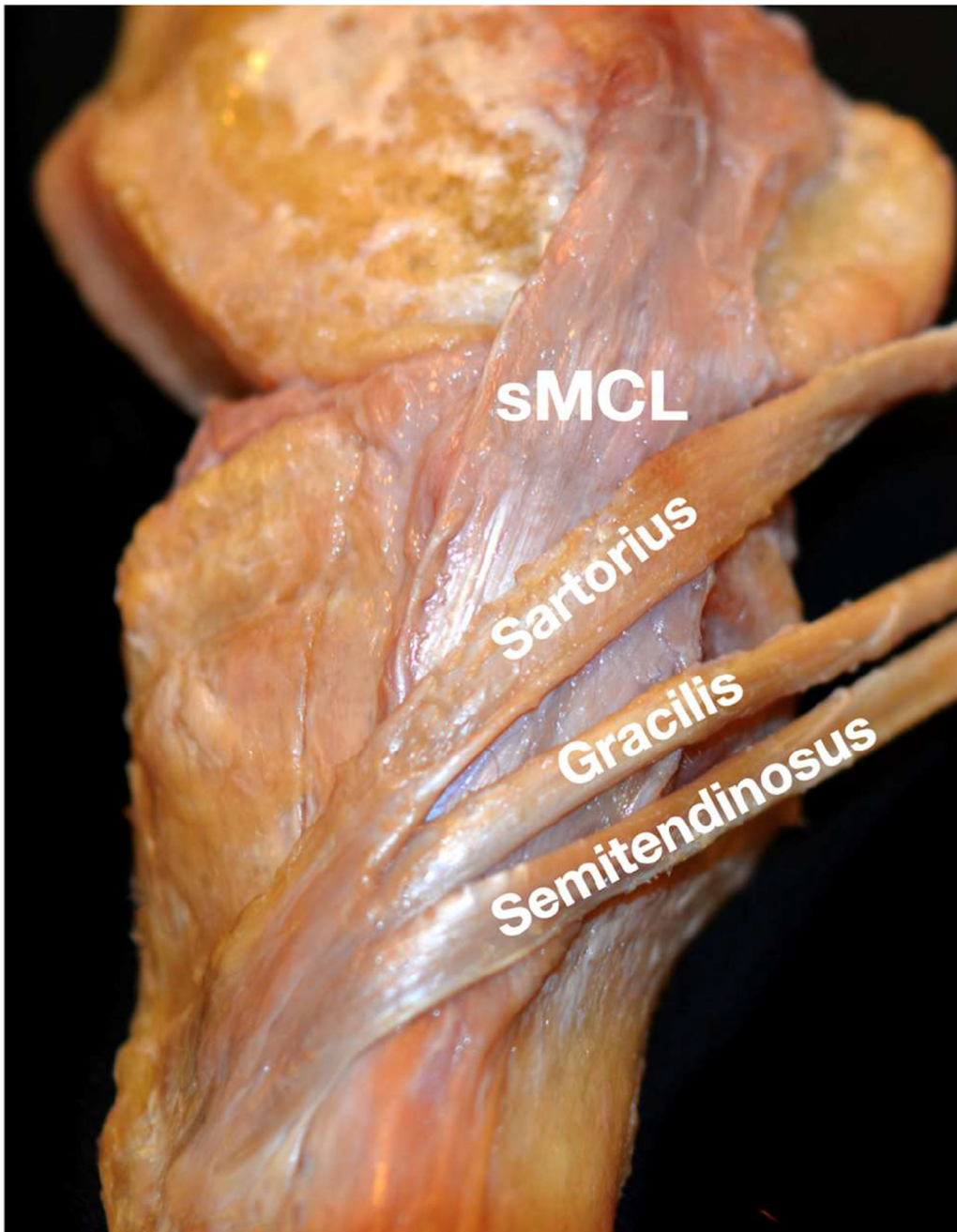


Figure 2 A photograph of the medial aspect of a knee demonstrating the distal sartorius, gracilis, and semitendinosus tendons coalescing into the pes anserine as the 3 tendons form a common insertion on the medial aspect of the proximal tibia. Deep to these tendons lies the superficial medial collateral ligament (sMCL).

the most common autografts for reconstructions of the knee, they are both covered by a thin fibrotic cap formed by the sartorius tendon, which makes surgical access to these 2 tendons more restricted.¹⁰ Contrarily, the sartorius tendon fascia is intimately attached to the superficial fascial layer.¹

Superficial Medial Collateral Ligament (sMCL)

The sMCL, commonly known as the tibial collateral ligament, is the largest structure of the medial aspect of the knee

and measures approximately 10-12 cm in length (Figs. 1-4).^{1,8,13} It is located in the middle layer of the medial side of the knee.⁷ The single attachment site on the femur is oval-shaped and located within a small depression about 3.2 mm proximal and 4.8 mm posterior to the medial epicondyle.¹ Moreover, as the sMCL courses distally, it attaches to the tibia just posterior to the pes anserinus insertion in 2 different locations: a proximal and distal site.^{1,6} The distal insertion site attaches directly to the tibia approximately 61.2 mm distal to the joint line and anterior to the posteromedial crest of the tibia; whereas, the proximal site attaches to soft tissues directly over the anterior arm of the semimembranosus,

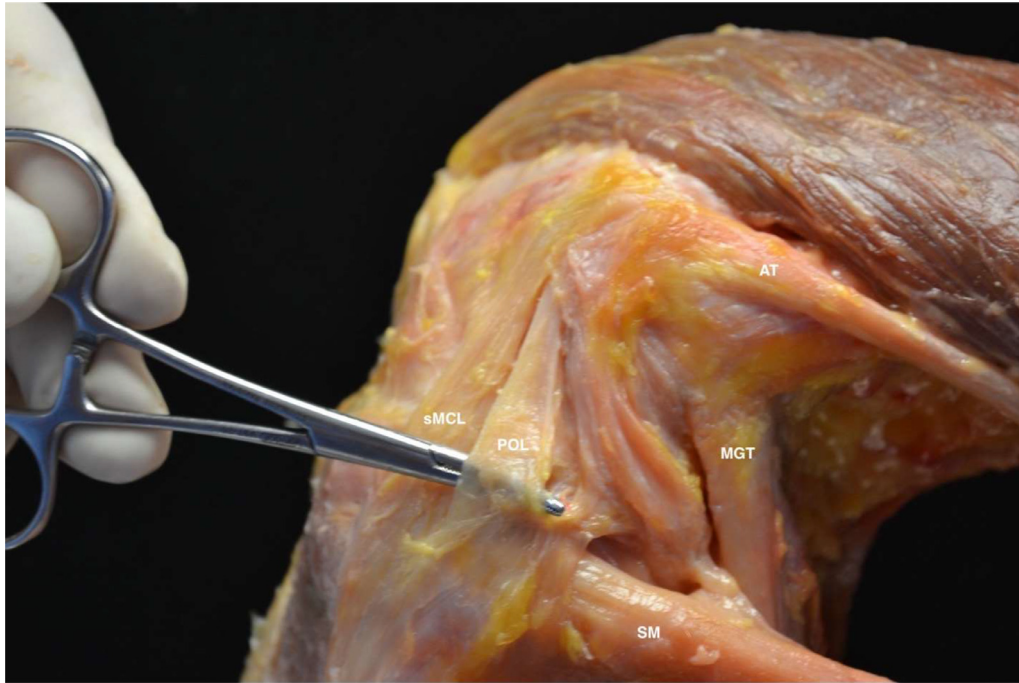


Figure 3 A photograph of a cadaveric dissection demonstrating key surgical anatomy of the middle and deep layers of the medial aspect of the knee. This included the adductor magnus tendon (AT), the medial gastrocnemius tendon (MGT), the semimembranosus tendon (SM), the superficial medial collateral ligament (sMCL), and the posterior oblique ligament (POL).

which is approximately 11.2 mm distal to the joint line.^{1,14,15} These 2 attachment sites on the tibia result in 2 distinct functioning structures of the sMCL.¹⁶

The sMCL is innervated by the medial articular nerve, a branch of the saphenous nerve.⁷ Innervation is most pronounced in the epiligament tissue surrounding the sMCL and the insertion sites, indicating that the ligament can perceive pain and process proprioception.⁷ Consequently, complete grade III injuries to the MCL will disrupt these nerve fibers and cause pain. The blood supply to the MCL comes from branches of the superior and inferior genicular arteries.⁷

Deep Medial Collateral Ligament (dMCL)

The dMCL is located in the deep layer of the knee, specifically deep and parallel to the anterior aspect of the sMCL.^{1,6,15} It is often considered a thickening of the anterior aspect of the medial joint capsule and is comprised of 2 components: the meniscotibial and menisiofemoral components (Fig. 5).^{1,6} The menisiofemoral component is longer and thinner than the meniscotibial component and attaches the meniscus to a point approximately 15.7 mm proximal to the femoral joint line in a slightly curved fashion.¹ This attachment is just deep to the sMCL attachment on the femur and has also been described as located at a point 1 mm distal and posterior to the medial femoral epicondyle.^{7,15} Contrarily, the meniscotibial component is much shorter and thicker and attaches the meniscus to a point approximately 3.2 mm distal to the tibial joint line, which is typically 9.0 mm proximal to the proximal tibial attachment of the sMCL.^{1,5}

In comparison to the sMCL, there are not as many studies reporting on the isolated function of the dMCL. However, in the few biomechanical studies that exist, the authors demonstrated that the dMCL functions as a secondary restraint to valgus forces.¹⁷⁻¹⁹ Specifically, the meniscotibial component provides valgus stabilization at 60° of knee flexion, while the menisiofemoral component provides stabilization at all degrees of knee flexion.¹⁷⁻¹⁹ In addition, between 30° and 90° of flexion, the dMCL also provided stabilization against external rotation of the tibia in relation to the femur.^{17,19}

Just like the sMCL, the dMCL is innervated by the medial articular nerve and receives its blood supply from the branches of the superior and inferior genicular arteries.⁷

Adductor Magnus Tendon (AMT)

The AMT is not commonly injured and, therefore, serves as an essential surgical landmark when treating injuries to the medial aspect of the knee (Fig. 3).¹ The insertion of the AMT on the distal aspect of the femur is in a small depression 3.0 mm posterior and 2.7 mm proximal to the adductor tubercle.¹ Importantly, it does not insert onto the apex of the adductor tubercle.¹ There is a thick posteromedial fascia layer that expands from the distal aspect of the AMT proximally to the medial gastrocnemius tendon (MGT) and posteromedial joint capsule.¹ Along the lateral aspect of the AMT, 2 attachments of the vastus medialis longus muscle can be identified.¹

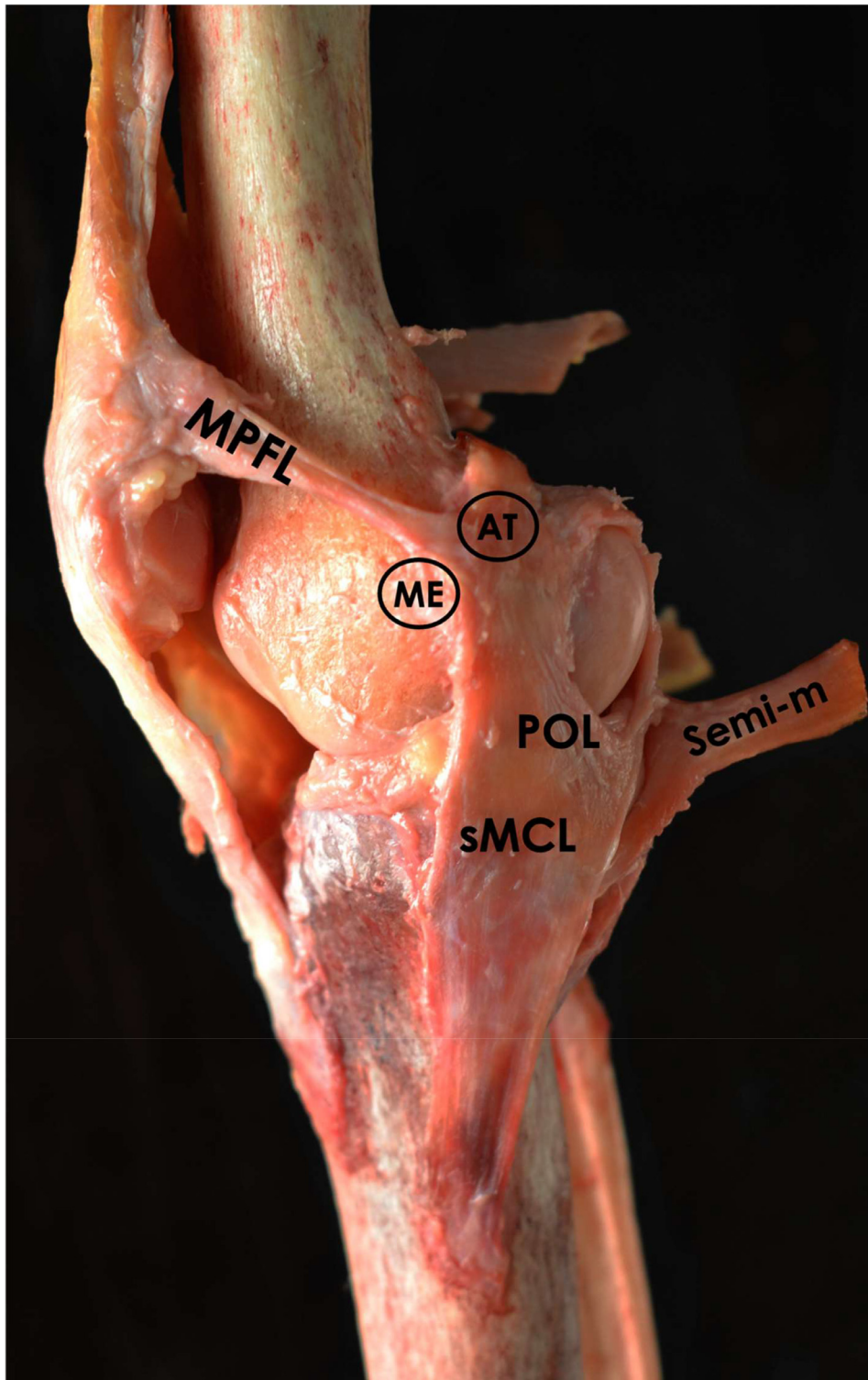


Figure 4 A right knee dissection demonstrating the posterior oblique ligament (POL), superficial medial collateral ligament (sMCL), adductor tendon (AT), medial epicondyle (ME), medial patellofemoral ligament (MPFL), and semimembranosus tendon (Semi-m).

Posterior Oblique Ligament (POL)

Despite early studies describing the POL as a posterior expansion of the sMCL, most recent reports describe the POL as an anatomically and functionally distinct structure located in the middle layer of the knee (Figs. 1,3, and 4).^{5,20} The POL is comprised of 3 fascial attachments known as the

capsular, superficial, and central (tibial) arms that all originate from the distal aspect of the semimembranosus tendon and blend into the posteromedial joint capsule.^{1,5,15,21}

The central arm of the POL is considered the most important attachment arm and is the largest and thickest of the 3.²⁰ Distally, it originates from the distal aspect of the

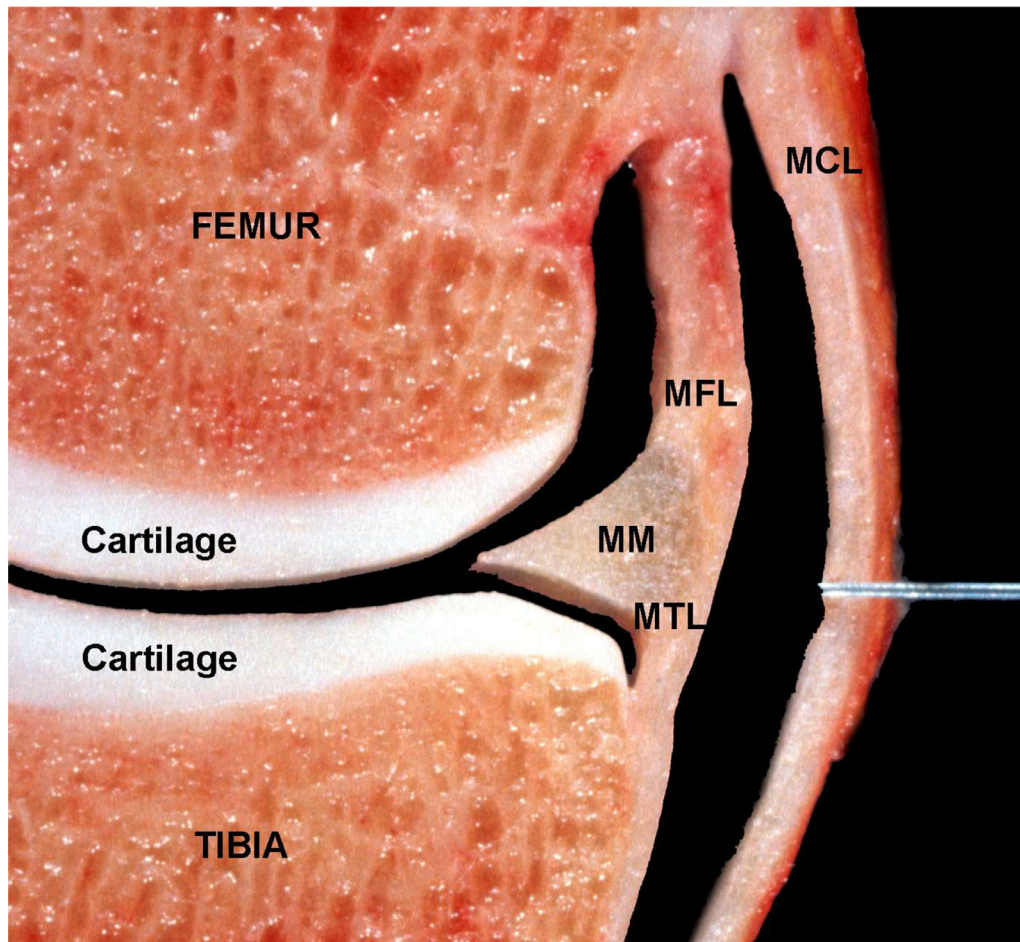


Figure 5 A coronal cross-section of a right knee demonstrating the medial meniscus (MM), the menisofemoral ligament (MFL), the meniscotibial ligament (MTL), and the medial collateral ligament (MCL).

semimembranosus tendon and blends into the posterior joint capsule and posterior medial meniscus, reinforcing the dMCL.^{5,21} The fan-like fibers of the central arm continue to track proximally and attach to a point on the femur 1.4 mm distal and 2.9 mm anterior to the gastrocnemius tubercle, and 7.7 mm distal and 6.4 mm posterior to the adductor tubercle.^{1,21} The fan-like projections allow it to be differentiated from the sMCL.¹

The capsular arm of the POL is a thin fascial layer that originates from the anterior and distal aspect of the semimembranosus tendon.^{1,21} It inserts into the soft tissue covering the MGT, femoral attachment of the AMT, and AMT extension to the medial gastrocnemius.^{1,22}

Finally, the superficial arm of the POL is also a thin fascial layer that proximally extends medial to the anterior arm of the semimembranosus until it blends into the central POL arm.¹ Distally, it courses along the posterior border of the sMCL until it blends into the distal tibial expansion of the semimembranosus and its tibial attachment.^{1,22}

In general, the POL functions as an internal rotator and valgus stabilizer of the knee joint between 0° and 30° of flexion.¹⁵ More specifically, biomechanical studies have demonstrated that the sMCL exhibits the largest load response to applied valgus and external rotation torque, whereas the POL demonstrated the highest load response to internal

rotation close to extension.^{15,16} As such, a reconstruction technique that restores the anatomic function of the POL, as well as the sMCL, is recommended to restore normal stability to the knee.¹⁵

Medial Patellofemoral Ligament (MPFL)

The MPFL courses from the medial epicondyle of the femur to the proximal part of the medial border of the patella and is an important fascial band of the medial knee that ensures patellar stability throughout the knee's range of motion (Fig. 6).^{23,24} It is approximately 53 mm long but can range anywhere between 45 and 64 mm long depending on the age and size and sex of the patient.²⁵ On the femur, it attaches in a relatively compact location, specifically 1.9 mm anterior and 3.8 mm distal to the adductor tubercle at the same region as the sMCL and AMT insertions on the femur.¹ The MPFL is thickest at its femoral insertion point and begins to fan out and thin before it inserts into a wider attachment point on the medial patella.^{24,26} It has been described to extend distally from the proximal medial corner of the patella over approximately half the length of the medial patella border (~20 mm); however, some reports have shown that it can insert over the entire medial aspect.²⁴ Furthermore, there are fibers from the MPFL that merge into the vastus medialis

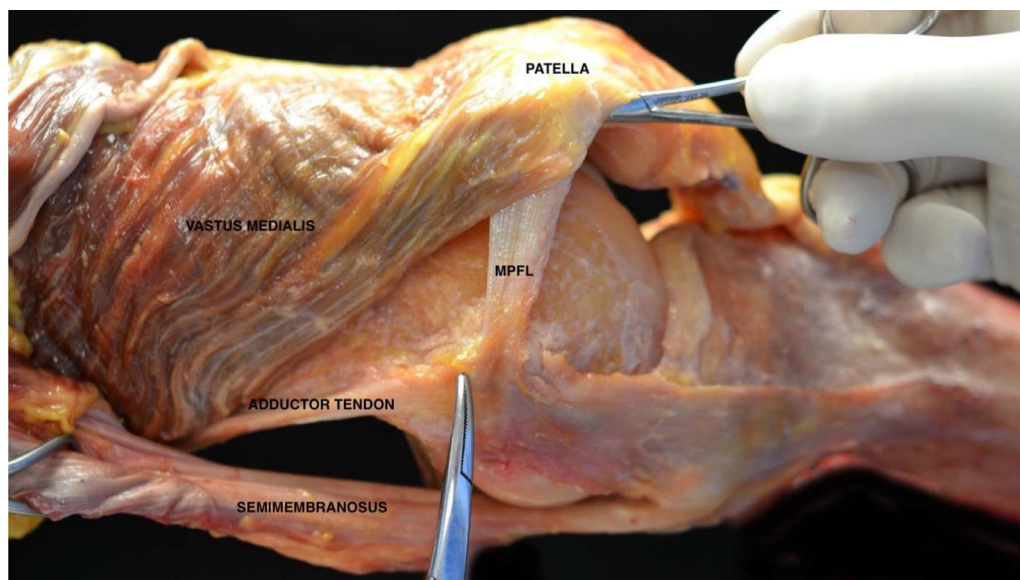


Figure 6 A photograph of a dissection along the medial aspect of a left knee demonstrating the MPFL (medial patellofemoral ligament), the patella, the adductor tendon, the semimembranosus, and the vastus medialis.

obliquus medially to help maintain the patella within the trochlear groove.^{1,24}

From a functional standpoint, the MPFL provides primarily passive restraint against lateral translation of the patella.²⁴ As such, injuries to the MPFL should be treated with reconstruction to restore the normal patellar kinematics. Evidence has demonstrated that correct placement at the native femoral attachment is most critical in the length change pattern of a reconstructed MPFL.²⁴

Medial Gastrocnemius Tendon (MGT)

The proximal medial gastrocnemius tendon (MGT) is a useful anatomic landmark to assist in identification of key anatomical structures along the medial aspect of the knee (Fig. 3). It is formed at the medial edge of the medial gastrocnemius tendon before passing deep to the semimembranosus tendon and inserting into its origin on the posteromedial edge of the medial femoral condyle.¹ It is important to note that the MGT does not attach to either the gastrocnemius tubercle or the adductor tubercle, but instead attaches adjacent to these osseous prominences in a small depression on the condyle. A quantitative anatomic study by LaPrade et al. demonstrated that the MGT attached at an average of 2.6 mm (range, 1.4-4.4 mm) proximal and 3.1 mm (range, 2.6-3.6 mm) posterior to the gastrocnemius tubercle.¹ In the same study, the authors also reported the MGT inserted 5.3 mm (range, 4.0-7.2 mm) distal and 8.1 mm (range, 6.1-10.3 mm) posterior to the adductor tubercle. The MGT also has 2 fascial attachments to the surrounding connective tissues.¹ On the lateral aspect of the tendon, the MGT has a thick fascial attachment to the adductor magnus tendon. On the posteromedial aspect, the MGT has a thin fascial attachment to the capsular arm of the posterior oblique ligament. The MGT has clinical relevance as it can be utilized in identification of the gastrocnemius tubercle as well as the posterior

oblique ligament. For example, in a medial knee anatomic reconstruction technique described by LaPrade et al., the MGT can be identified, and followed to its femoral attachment site to identify the gastrocnemius tubercle in settings where the posteromedial capsule was completely torn from the femur.²⁷

Neurovascular Structures

Along the medial aspect of the knee, there are 3 major neurovascular structures that must be consistently considered during any surgical procedure. These are the saphenous nerve as well as the superior and inferior medial genicular arteries.

The saphenous nerve originates from the L2, L3, and L4 lumbar roots and can lead to a spectrum of neurologic sequelae when injured. It divides from the posterior division of the femoral nerve in the proximal thigh before entering the adductor canal, where it courses medial to the femoral artery.²⁸ It exits the canal at the lower portion of the adductor magnus and promptly divides into the main sartorial branch and the infrapatellar branch.²⁹ The proximity of the saphenous nerve to the medial musculoskeletal structures of the knee has made it vulnerable to iatrogenic injury from a variety of procedures including arthroscopy, medial knee injections, hamstring tendon harvesting, saphenous vein harvesting, and fasciotomies.³⁰ Injury to either branch is not uncommon and can occur at a relatively high rate in minimally invasive procedures like arthroscopic meniscal repair.²⁸ As a result, understanding the course of these branches is crucial.

The infrapatellar branch travels anteriorly and courses inferior to the patella.³¹ It innervates the anteromedial aspect of the knee and is the primary articular afferent branch of the saphenous nerve.³² It provides innervation to the inferomedial capsule, patellar tendon, and overlying skin. It also innervates the anterior medial ligaments of the knee and is

thought to be important for proprioception, stability, and balance.³³ After dividing from the femoral nerve, it pierces the sartorius muscle, and follows a distal anterior trajectory toward the medial patellar tendon.⁵ As it traverses across the patellar tendon it forms the infrapatellar plexus, which is at high risk for injury during surgical procedures.³³ Along the patellar tendon, there has been variation in the number of branches that course over the tendon; this value has ranged from 1 to 3 branches with 2 branches being most common.³³⁻³⁵ Due to the high variation in topographic anatomy of the infrapatellar branch of the saphenous nerve, no true safe zone could be defined in prior anatomic studies.³³

The location of the infrapatellar branch of the saphenous nerve as it travels distally is closely related to the pes anserinus as it travels between the gracilis and sartorius tendons before it dives through the deep fascia.¹² The infrapatellar branch of the saphenous nerve runs almost parallel to the upper edge of the pes anserinus tendon approximately 0.95 cm (ranged -0.52 to 2.55 cm) from the tendon, which is why infrapatellar branch damage is a common complication following anterior cruciate ligament reconstruction that harvests hamstring or patellar tendon autografts.^{12,28,36}

The sartorial branch has a vertical course and travels deep to the sartorius before piercing the fascia between the sartorius and gracilis muscles, becoming subcutaneous, and continuing distally with the greater saphenous vein to provide sensation to the medial leg, knee, calf, and ankle.^{28,30} A study by Dunaway et al. demonstrated that the nerve is on average 16.0 mm (range, 0-25 mm) from the anterior aspect of the sartorius and was posterior to the sartorius in 41 of 42 specimens.²⁸ The authors also demonstrated the nerve is superficial to the pes tendons in 43% of specimens at the level of the meniscus. In all 42 specimens, the nerve became superficial between the sartorius and gracilis tendons.

The safe zone to avoid the sartorial branch of the saphenous nerve has been quantified by Wijdicks et al. in a 2009 anatomic study.³⁰ The distance of the nerve to the adductor tubercle was 5.0 ± 1.1 cm. This distance to the medial epicondyle was 6.1 ± 1.0 cm. Moving distally, the nerve was 4.8 ± 0.9 cm from the anterior border of the superficial MCL at 2 cm from the joint line, 4.1 ± 0.8 cm at 4 cm distal to the joint line, and 3.8 ± 0.8 cm at 6 cm distal to the joint. Taken together, this study defined a safe zone for medial knee reconstruction that protects the sartorial branch of the saphenous nerve during an anteromedial knee incision. The authors demonstrated that the nerve courses slightly posterior to the medial knee structures, suggesting an incision that is anterior to the posteromedial aspect of the tibia will usually avoid this major branch of the saphenous nerve. Providing knee flexion during this approach will bring the sartorial branch of the nerve further posterior to better protect the nerve.²⁸

There are 2 genicular arteries that contribute to the neurovascular structures of the medial aspect of the knee. These are the superior and inferior genicular arteries. A cadaveric study by Lazaro et al. demonstrated that the superior medial genicular artery originates from the either the superficial femoral artery or the popliteal artery.³⁷ This same study demonstrated that the inferior medial genicular artery branches more distally

and originates solely from the popliteal artery. The superior and inferior medial genicular arteries form an anastomosis with their respective lateral counterpart. The superior medial genicular artery will combine with the superior lateral genicular artery at a location that is slightly superior to the patella and anterior to the quadriceps tendon.³⁸ The inferior medial genicular artery will run between the 2 tibial insertion sites of the MCL, deep to the MCL, and below the medial border of the tibial plateau before joining the peripatellar anastomotic ring on the anterior aspect of the tibial plateau.³⁷

Lateral Aspect of the Knee

The lateral aspect of the knee, and more specifically the posterolateral corner, once thought of as the “dark side” of the knee, has undergone significant exploration to improve the understanding of the biomechanical and anatomical properties of these structures.³⁹ Injuries to the lateral side of the knee can have a significant impact on rotational stability, patellar tracking, and patient quality of life.⁴⁰⁻⁴² As a result, understanding the anatomical components of the lateral side of the knee has implications for posterolateral corner reconstruction, anterolateral corner reconstruction, lateral opening wedge femoral osteotomies, lateral closing wedge high tibial osteotomies, inside-out meniscus repair, anterolateral ligament reconstruction, and lateral extra-articular tenodesis.⁴³⁻⁴⁶

The lateral aspect of the knee has many unique structures. The primary static stabilizers, comprising the posterolateral corner, include the fibular (lateral) collateral ligament (FCL), popliteus tendon (PLT), and the popliteofibular ligament (PFL) (Fig. 7).² Other important structures to consider include the long and short heads of the biceps femoris muscle, the proximal tendon of the lateral gastrocnemius, the anterolateral ligament, the iliotibial band, the fabellofibular ligament, the proximal tibiofibular ligaments, and the coronary ligament of the lateral meniscus. It is also important to understand the anatomy of the lateral meniscus as well as the key neurovascular structures of the region. For example, the common peroneal nerve and lateral inferior genicular artery are crucial to assess and treat for posterolateral corner injuries.⁴⁷

Similarly, to the medial side of the knee, the lateral knee was historically divided into 3 distinct layers: the superficial, middle, and deep layers. The superficial layer consists of the iliotibial band (ITB) and biceps femoris complex; the middle layer consists of the lateral patellofemoral ligament and lateral patellar retinaculum; the deep layer consists of the fibular collateral ligament (FCL), popliteus tendon (PLT), popliteofibular ligament (PFL), fabellofibular ligament, and anterolateral ligament (ALL). In the following section, we describe the anatomical landmarks and considerations for the lateral aspect of the knee.

Bony Landmarks

There are several bony anatomical landmarks that are important when considering surgical intervention to the lateral side

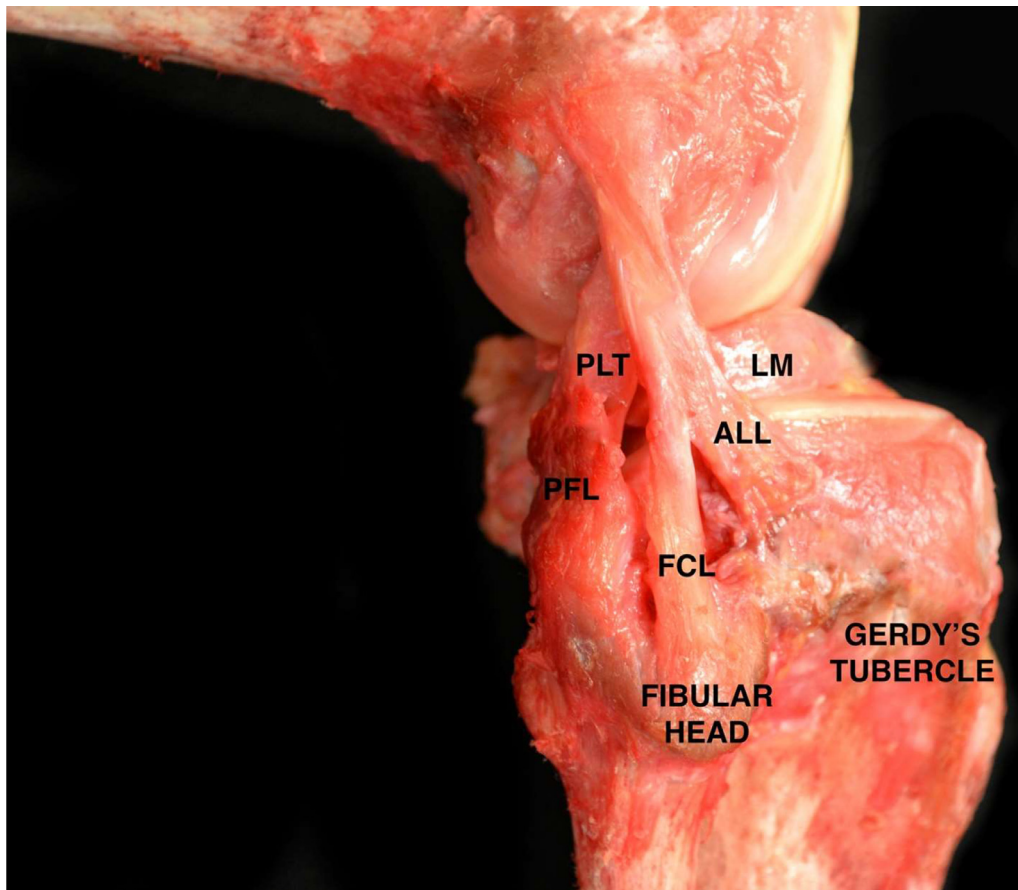


Figure 7 Key surgical anatomy on the lateral aspect of the knee depicted in a photograph of a cadaveric dissection. In the image, the popliteal tendon (PLT), the popliteofibular ligament (PFL), and the fibular collateral ligament (FCL) can be seen forming the 3 primary stabilizers of the posterolateral corner. The anterolateral ligament (ALL), lateral meniscus (LM), Gerdy's tubercle, and fibular head are also seen.

of the knee, including the lateral femoral epicondyle, proximal and distal ridges for the Kaplan fibers, Gerdy's tubercle, popliteus musculotendinous junction, and the fibular head (Fig. 8). On the femur, the lateral femoral epicondyle sits 23.6 ± 2.33 mm proximal from the joint line.⁴⁸ The distal iliotibial band has an associated proximal bony ridge which lays 53.6 mm proximal from the lateral epicondyle and a distal ridge 31.4 mm proximal from the lateral epicondyle.^{49,50} On the tibia, Gerdy's tubercle is located 17.1 mm distal to the tibial plateau line along the anterolateral tibia, and the popliteus musculotendinous junction is 11.1 mm distal to the tibial plateau line.⁵¹ The fibular head and its associated fibular styloid process has a multitude of attachments with lateral knee stabilizers and acts as a key landmark for the common peroneal nerve as it traverses beneath the biceps femoris 45.3 mm from the posterior border of the fibula.⁵²

Iliotibial Band

The iliotibial band, part of the superficial layer of the lateral side of the knee, is an extensive fascial sheath originating at the iliac crest, and extending over the tensor fasciae latae distally until it inserts into the anterolateral

tibia at Gerdy's tubercle (Fig. 9).⁵³ More recently, extensive biomechanical and cadaveric analysis has focused on the additional expansions of the distal iliotibial band insertion. Two distinct deep fiber bundles off the iliotibial band, known as the Kaplan fibers, extend to 2 bony ridges. The proximal Kaplan fiber bundle inserts on the distal femur at the proximal ridge 53.6 mm from the lateral epicondyle, while the distal bundle inserts on the distal ridge 31.4 mm from the lateral epicondyle.^{49,50} Additionally, a capsulo-osseous layer of the distal iliotibial band exists in close relation to the lateral joint capsule. The origin of this capsulo-osseous layer is found at the lateral gastrocnemius tubercle on the distal ridge, 19.1 mm proximal to the lateral epicondyle and inserts on the tibia at the lateral tibial tubercle between Gerdy's tubercle and the fibular head.⁵⁰ The superior lateral genicular artery can be routinely found to course distal to the distal Kaplan fibers insertion on the femur and is proximal to the capsulo-osseous layer.⁵⁰ During an isolated reconstruction of the FCL or in posterolateral corner reconstruction, a vertical incision can be made into the distal iliotibial band to expose the femoral attachment of the FCL.⁴²

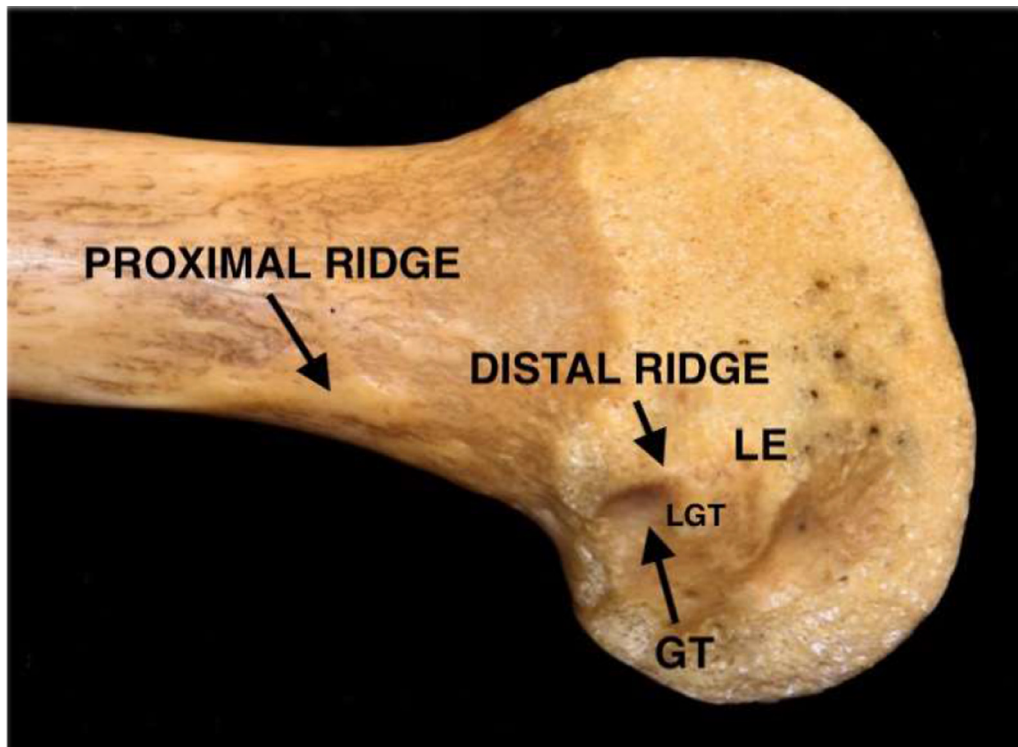


Figure 8 Cadaveric right distal femur demonstrating the proximal ridge where the proximal Kaplan fibers from the iliotibial band insert and the distal ridge where the distal Kaplan fibers from the iliotibial band insert. The lateral epicondyle (LE), the lateral gastrocnemius sulcus (GT), and the insertion site for the lateral gastrocnemius tendon (LGT).

Long and Short Head of Biceps Femoris

The biceps femoris is composed of both a short and long head with 2 different origin sites. The long head of the biceps femoris is found originating at the ischial tuberosity as well as origin sites along the lateral aspect of the thigh.⁵⁴ The long head of the biceps femoris is part of the larger hamstring complex which originates at the ischial tuberosity. Distally, the long head has 2 tendinous attachments, direct and anterior arms, as well as 3 fascial connections: anterior aponeurosis, lateral aponeurosis, and the reflected arm.⁵⁵ The direct arm attaches along the lateral part of the fibular styloid while the anterior arm extends lateral to the FCL and inserts on the lateral aspect of the fibular head.⁵⁵ The bursa of the long head of the biceps femoris separates the anterior and direct arms from the FCL. The bursa has a mean width of 8.4 mm and mean height of 18 mm and forms a “J” shape around the anteromedial portion of the FCL distally.⁵⁶ This bursa becomes a key surgical landmark and is incised to identify the fibular attachment of the FCL during either isolated FCL reconstruction or in the setting of posterolateral corner reconstruction procedures.⁵⁶

The short head of the biceps femoris originates more distally on the femur beginning at the medial aspect of the linea aspera.⁵⁷ There are numerous insertion sites of the short head with 3 tendinous arms: direct, anterior, and capsular. The direct arm is the most prominent tendinous attachment and is found at the fibular head situated between the distal FCL attachment and the fibular styloid.⁵³ Comparatively, the anterior arm of the short head of the biceps femoris is found

approximately 10 mm posterior to Gerdy’s tubercle and the capsular attachment can be found between the lateral head of the gastrocnemius and the FCL.⁵⁵ Additionally, 3 other non-tendinous attachments exist, including a lateral aponeurotic expansion attaching the short and long heads posteriorly to the FCL, an insertion forming a confluence with the capsulo-osseous layer of the iliotibial band, as well as a more muscular insertion onto the long head of the biceps femoris tendon.⁵⁵

Fibular Collateral Ligament (FCL)

The FCL, also known as the lateral collateral ligament (LCL), is the primary stabilizer to varus forces on the knee from 0° to 30° of flexion with a decreased role past 30° due to increased ligamentous laxity (Fig. 7).⁴⁷ The FCL is approximately 70 mm in length and originates 1.4 mm proximal and 3.1 posterior to the lateral epicondyle.⁵⁷ The proximal attachment of the FCL on the femur is about 18.5 mm proximal and posterior to the popliteus tendon femoral origin. The insertion lies 8.2 mm posterior to the anterior border of the fibula and 28.4 mm antero-inferior to the proximal portion of the fibular styloid.^{47,58} The blood supply of the FCL comes from both the inferior lateral genicular artery and the anterior tibial recurrent arteries.⁵⁹ Additionally, the innervation has been well studied with the proximal portion receiving innervation from the muscular branch of the tibial nerve, and the middle and distal portions receiving innervation from the common fibular nerve.⁶⁰

After a hockey stick incision is made through the skin layer laterally, the proximal FCL attachment can be located

just deep through a longitudinal incision in the iliotibial band. This can be assessed preoperatively by palpating the bony depression between the lateral epicondyle and supracondylar process. Comparatively, the distal insertion on the anterolateral fibula can be accessed through an incision in the bursa of the long head of the biceps femoris further described in the biceps femoris section above.⁶¹

Popliteus Tendon (PLT)

The PLT is considered the fifth ligament of the knee and acts in a primary role in restraining against external rotation of the tibia and as a secondary stabilizer to internal rotation and posterior and anterior translation (Fig. 7).^{62,63} The popliteus muscle courses proximal and laterally giving rise to the PLT that rests at the anterior fifth and proximal half of the popliteal fossa.² When the tendon passes through the popliteal hiatus, it becomes intra-articular, and attaches to the anteroinferior, posterosuperior, and posteroinferior fascicles which act as stabilizers for the lateral meniscus. These fascicles have attachments along the meniscofemoral portion of the posterior capsule as well as directly to the lateral meniscus.^{64,65} The popliteus tendon lies 18.5 mm anterior and distal to the insertion of the FCL on the femur with a broad attachment of 0.59 cm². The length of the PLT from the femoral attachment to its musculotendinous junction is 54.5 mm (range, 50.5-61.2).² Furthermore, the relationship of the PLT to the proximal FCL insertion is critical during posterolateral corner reconstruction because improved outcomes and patient satisfaction is observed when reconstruction recreates the native anatomy.⁶³

Popliteofibular Ligament (PFL)

In addition to the PLT and FCL, the PFL is the third anatomic component of the main primary static stabilizers of the posterolateral corner. In the past, the PFL has been incorrectly categorized as the arcuate ligament (Figs. 7 and 10).⁵³ The PFL has 2 distinct divisions that originate at the musculotendinous junction of the PLT and form a “Y” configuration.⁵⁷ The anterior division of the PFL lies medial to the FCL at the proximal-lateral musculotendinous junction of the PLT and is approximately 2.6 mm in width. Distally, the anterior division attaches on the fibula 2.8 mm distal to the anteromedial aspect of the styloid process tip.⁴⁷ Comparatively, the posterior division of the PFL begins from the popliteus tendon and extends distally to insert 1.6 mm distal to the apex of the fibular styloid process.² The width of the posterior division is larger with a width of 5.8 mm.² The intersection of the overlapping PFL and PLT forms an 83° angle at the junction. During surgical reconstruction of the posterolateral corner of the knee, one must be careful of the inferior lateral genicular artery that courses immediately posterior to the PFL. The artery travels along the posterior capsule along the superior aspect of the lateral meniscus bisecting the popliteofibular and fabellofibular ligaments.⁶⁶ A recent cadaveric and MRI imaging study found that the PFL was found to be constant or rarely absent on cadaveric evaluation although its presence on MRI showed a lower prevalence though non-significant.⁶⁷

Anterolateral Ligament (ALL)

The ALL was first described by the French surgeon Segond as a fibrous band along the anterolateral aspect of the knee

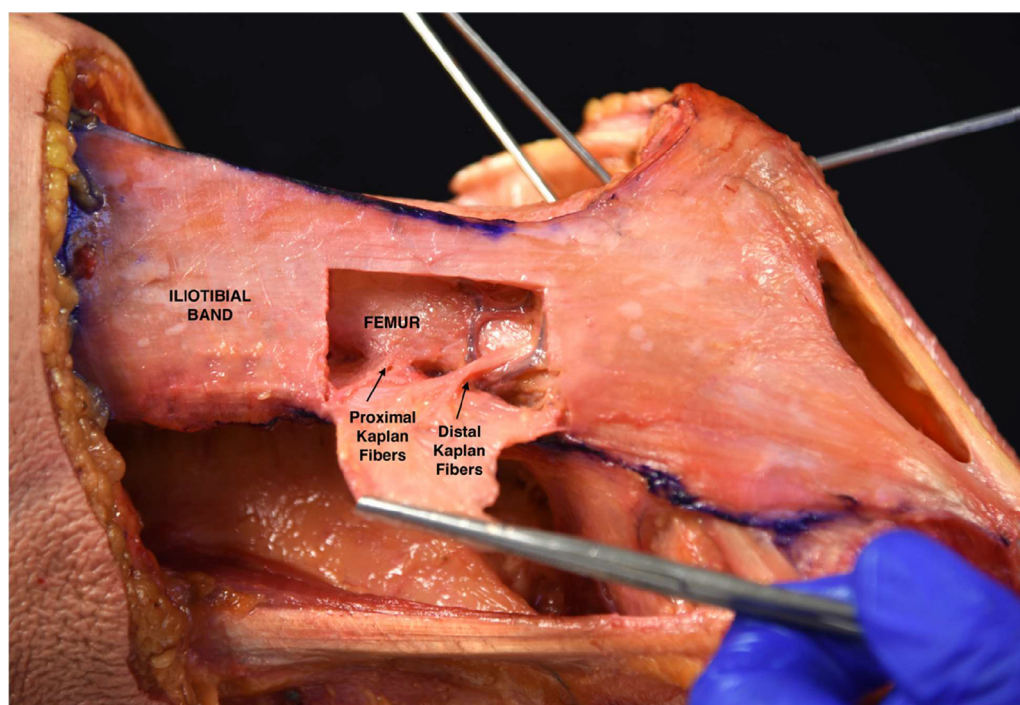


Figure 9 Photograph in a right knee demonstrating the distal and proximal Kaplan fibers from the iliotibial band (ITB).

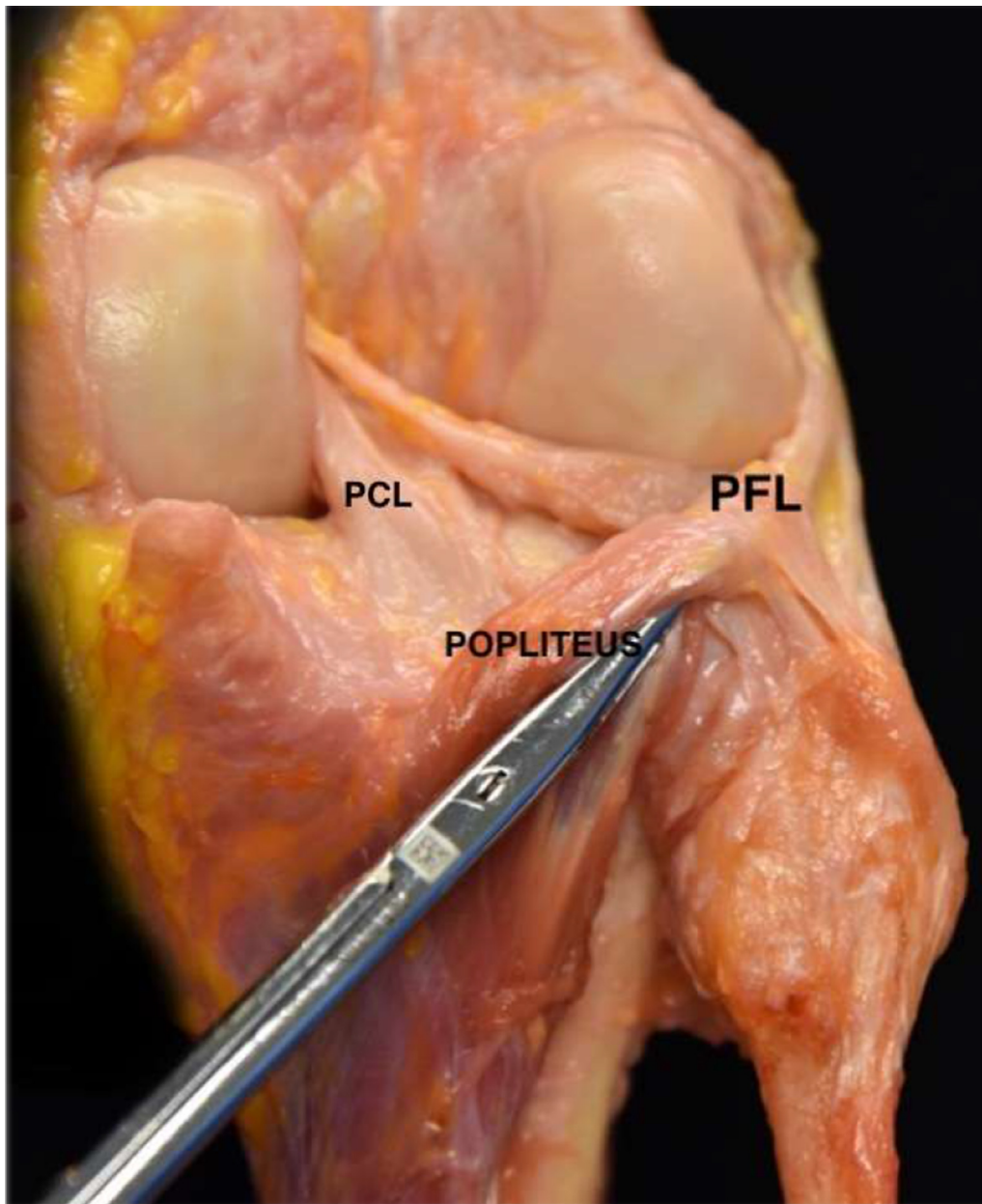


Figure 10 Key surgical anatomy of the lateral aspect of a right knee demonstrating the popliteus and popliteofibular ligament (PFL). The posterior cruciate ligament (PCL) is also seen.

(Figs. 7 and 11).⁶⁶ The ALL originates directly on the lateral epicondyle of the distal femur and inserts distally on the tibia near Gerdy's tubercle.⁶⁸ The femoral attachment is located 4.7 mm posterior and proximal to the FCL.⁶⁹ Furthermore, the ligament has a mean length of 33-37.9 mm and a mean width of 7.4 mm and has a femoral origin attachment area of 67.7 mm².^{70,71} As the ALL courses distally, the central portion of the ALL inserts on the external surface of the lateral meniscus with an attachment length of 5.6 mm.⁷² The ALL encases the lateral inferior genicular artery during its course distally. The distal attachment of the ALL on the tibia is 24.7 mm posterior to Gerdy's tubercle and 26.1 mm proximal to the anterior margin of the fibular head.⁶⁹ The distal site of attachment of the ALL inserts on the tibia 13.1 mm

distal to the lateral tibial plateau.⁶⁹ The area of the distal attachment has an average area of 53.0-64.9 mm² and is just proximal to the tibial insertion of the biceps femoris.⁶⁹ Given its role in rotatory stability of the knee, the ALL has been shown to act as a secondary stabilizer to the anterior cruciate ligament, and to help in resisting internal knee rotation as well as anterior tibial translation of the knee.⁷³

Lateral Gastrocnemius Tendon (LGT)

The LGT anchors the gastrocnemius laterally and proximally.⁴⁷ It emerges from the lateral-most aspect of the muscle belly in the region of the posterior fibular head.⁴⁷ It then

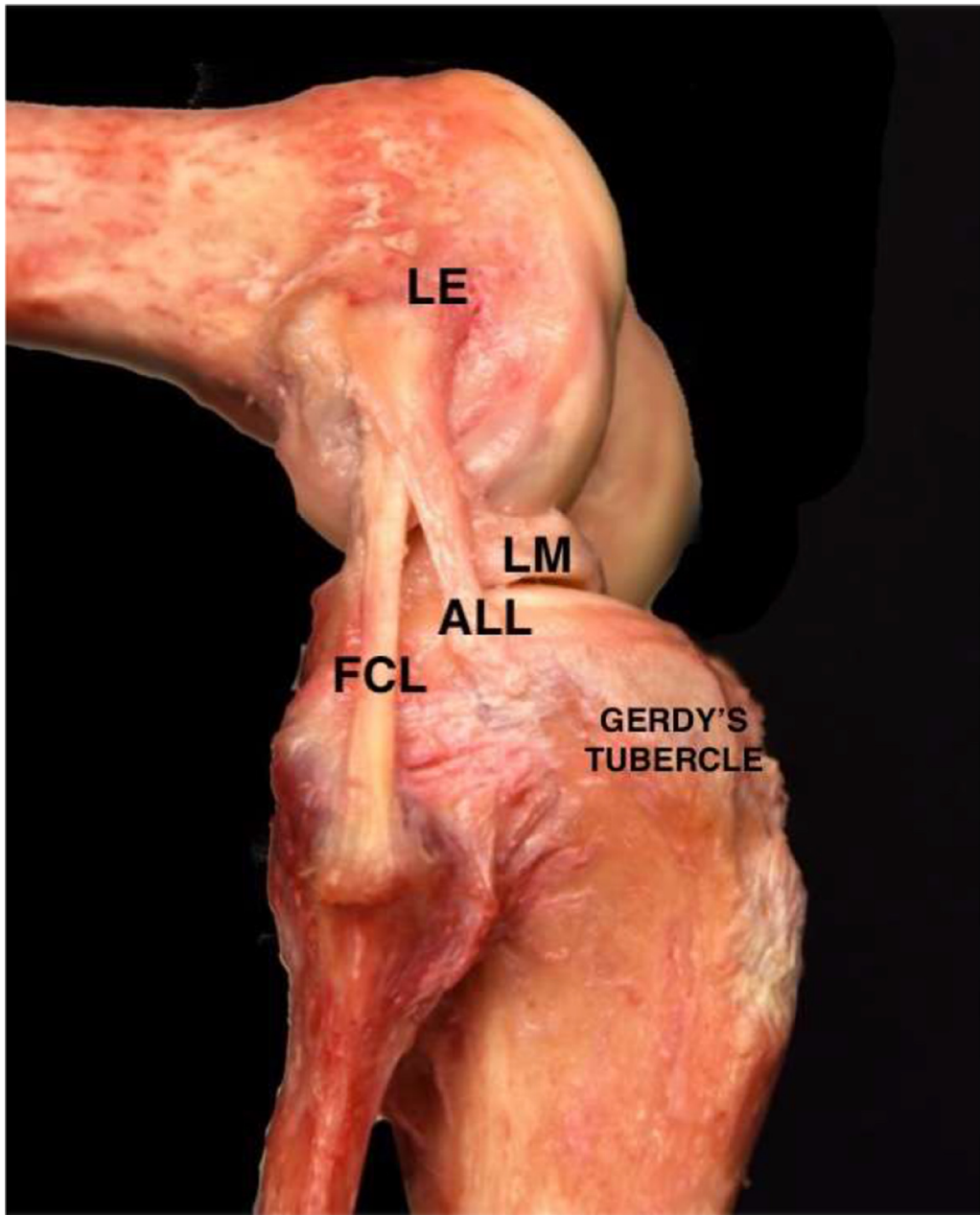


Figure 11 Dissection of a cadaveric specimen viewed from anterolateral position. The anterolateral ligament (ALL), fibular collateral ligament (FCL), lateral meniscus (LM), lateral epicondyle (LE), and Gerdy's tubercle are all depicted.

attaches to either the bony or a cartilaginous fabella-analogue and continues to attach to the femur.⁵³ An anatomic study by LaPrade et al. quantified the relationship of the key surgical anatomy of the lateral aspect of the knee.² The authors noted that the LGT attached to the supracondylar process in approximately 8 of the 10 cadaveric specimens included in their study, while it originated slightly distal, and posterior to the supracondylar process in the remaining 2 knees. LaPrade et al. noted that the femoral attachment was 13.8 mm (range, 11.3-16.4 mm) posterior to the proximal FCL attachment and 28.4 mm (range, 23.1-36.3 mm) from the PLT attachment.² A portion of the LGT is not attached to the fabella or the femur. This section of the tendon attaches

to the meniscomfemoral portion of the posterolateral joint capsule at the level of the fabella.⁴⁷

The LGT has extensive clinical importance for posterolateral corner injuries. Unlike the surrounding stabilizers, it is rarely avulsed in posterolateral knee injuries, and can be used as a reference for identifying other key posterolateral knee structural attachment sites.² For procedures that require the LGT to be separated from the posterior capsule, the section that adheres to the posterolateral joint capsule can be sharply dissected.⁴⁷ For isolated PLT and total posterolateral corner reconstructions, the LGT can be used to identify the interval between the lateral gastrocnemius and soleus which can be expanded with blunt dissection to find the

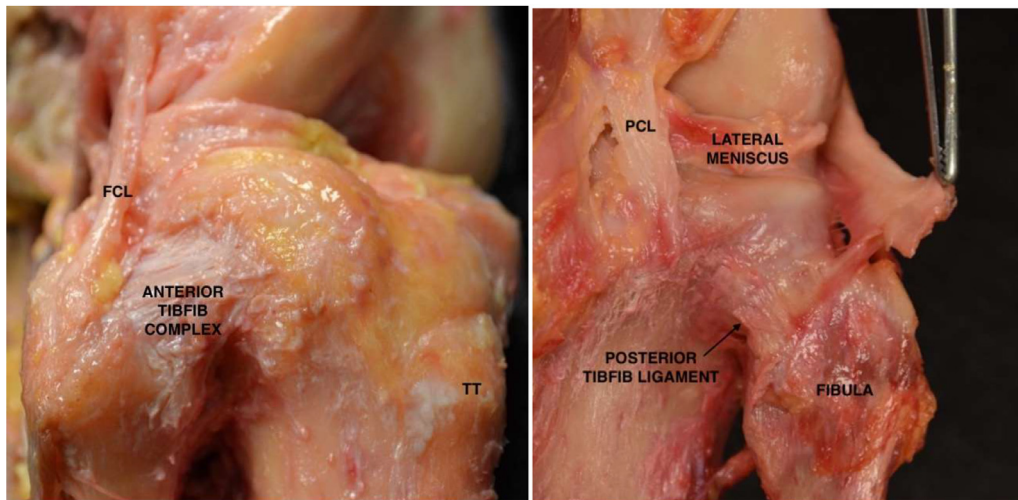


Figure 12 Cadaveric dissection demonstrating the anterior and posterior tibiofibular joint ligaments (TibFib Complex) as well as the fibular collateral ligament (FCL). The tibial tubercle (TT), lateral meniscus, and posterior cruciate ligament (PCL) are also seen.

musculotendinous junction of the popliteus muscle after common peroneal nerve neurolysis is performed.⁷⁴

Fabellofibular Ligament

The fabellofibular ligament is the distal edge of the capsular arm of the short head of the biceps femoris.² It is a static stabilizer of the knee and functions to resist external rotation, varus angulation, and posterior translation of the knee.⁷⁵ The fabella is a sesamoid structure that is located in the lateral head of the gastrocnemius.⁴⁷ It is found in 30% of individuals and can be composed of either bone or a cartilaginous analogue.^{74,76} Typically, the cartilaginous analogue is more common.⁷⁴ The fabellofibular ligament has been reported to occur in individuals regardless of whether they have a fabella or not.⁴⁷ For individuals with a fabella, the ligament originates from the fabella proximally, and inserts slightly lateral to the lateral-most aspect of the fibular styloid process.^{75,77} In individuals without a fabella, the fabellofibular ligament is less prominent, originates from the posterolateral femoral condyle, and inserts slightly lateral to the lateral-most aspect of the fibular styloid process.⁷⁵

Proximal Tibiofibular Joint Ligaments

There are 2 proximal tibiofibular joint ligaments. These are the anterior and posterior tibiofibular joint ligaments (Fig. 12). These ligaments provide stability to the joint by connecting the proximal aspect of the medial fibular head with the lateral aspect of the proximal tibia.⁴⁷ A study by Anavian et al. described the quantitative and qualitative anatomical relationships of these ligaments using ten cadaveric specimens.⁷⁸ The anterior ligament complex is composed of a maximum of 4 bundles: this includes a superior bundle, 2 middle bundles, and an inferior bundle. The center of the anterior superior bundle tibial footprint is 12.5 mm distal to the tibial plateau, while the center of the fibular footprint is

11.3 mm distal to the apex of the fibular styloid process. The center of the anterior inferior bundle footprint is 25.3 mm distal to the tibial plateau, and the center of the fibular footprint is 27.0 mm distal to the fibular styloid process apex. The anterior ligament complex tibial footprint surface area ranged from 8.7 to 19.4 mm², while the fibular footprint surface area ranged from 7.5 to 14.6 mm². The orientation of these bundles relative to the tibial plateau on an anteroposterior radiograph ranged from 46.9° to 56.1°.

Anavian et al. identified 2 distinct posterior bundles in all ten specimens.⁷⁸ These were the superior and middle bundles. The tibial and fibular superior bundle centers of attachments were 13.4 mm distal to the tibial plateau and 8.0 mm distal to the apex of the fibular styloid process, respectively. The middle bundle center of tibial attachment was 21.0 mm distal to the tibial plateau, and the fibular center of attachment was 20.1 mm distal to the apex of the fibular styloid process. On an anteroposterior radiograph, the mean orientation of the superior bundle was 41.9° relative to the tibial plateau, while it was 38.2° for the medial bundle. Two of the ten specimens demonstrated an inferior posterior bundle, which had a tibial footprint 38.8 mm distal to the tibial plateau, and a fibular footprint 29.3 mm distal to the apex of the styloid process of the fibula. There was no difference in length or width between the anterior or posterior ligament complexes; however, the anterior complex was thicker, and had a mean surface area of 761 ± 174 mm² compared to 565 ± 103 mm² for the posterior complex.⁷⁹ Biomechanically, this translated to the anterior ligamentous complex being a stronger structure that could withstand a higher ultimate tensile load (517 ± 144 N) relative to the posterior ligament complex (322 ± 160 N).⁷⁹

The structure has clinical importance due to its role as a joint stabilizer. As a result, tibiofibular ligament reconstructive techniques have been developed to manage acute or chronic tibiofibular joint instability.⁸⁰ A study by Marchetti et al. quantified the radiographic landmarks of these ligament

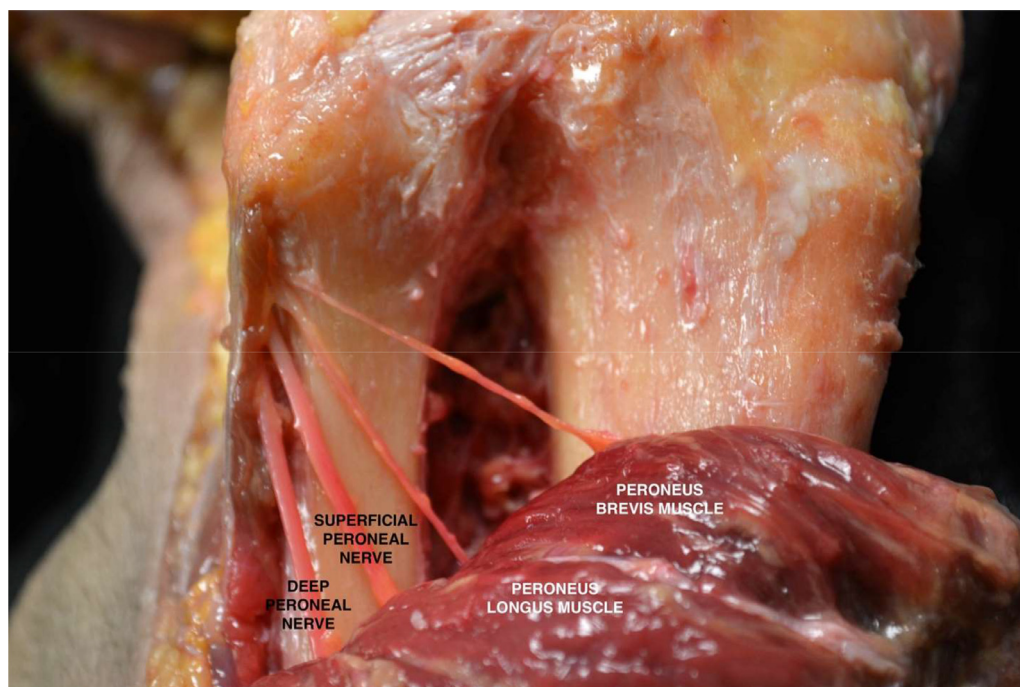


Figure 13 Dissection demonstrating the common peroneal nerve branching into the deep peroneal nerve and the superficial peroneal nerve. Branches from the superficial peroneal nerve are shown innervating the peroneus longus and brevis muscles in the lateral compartment of the lower leg.

complexes in an attempt to help improve surgical technique and guide tunnel placement for reconstructive procedures involving the proximal tibiofibular joint.⁸¹ The authors used the tibial plateau and the apex of the fibular head as radiographic anatomic landmarks and calculated proximodistal distances of the footprints relative to these structures. The authors noted excellent interrater agreement across specimens when utilizing this technique. The anterior ligamentous complex had a proximodistal distance of 12.8 ± 3.9 mm relative to the tibial plateau on anteroposterior views and 13.7 ± 3.2 mm on lateral radiographs. Relative to the fibular head, the fibular insertion site had a proximodistal distance of 11.6 ± 6.8 mm on anteroposterior views, and 14.6 ± 7.1 mm on lateral views. Relative to the tibial plateau, the posterior ligament complex had a proximodistal distance of 11.7 ± 8.4 mm on anteroposterior views and 12.9 ± 9.1 mm on lateral views. Relative to the fibular head, the complex had a proximodistal distance of 11.8 ± 7.9 mm on anteroposterior views and 10.9 ± 7.5 mm on lateral views. Understanding the quantitative and qualitative anatomical relationships of the anterior and posterior tibiofibular joint ligaments is critical in diagnosing injuries to these structures and for developing anatomic reconstructive techniques.

Neurovascular Structures

For procedures involving the lateral aspect of the knee, there are 2 major neurovascular structures that must be considered. These are the common peroneal nerve and the lateral inferior genicular artery. The common peroneal nerve

originates from spinal roots L4-S2. It bifurcates from the sciatic nerve in the posterior compartment of the thigh prior to traveling distally along the biceps femoris.⁴⁷ It wraps around the fibular head before splitting into the superficial and deep peroneal nerves (Fig. 13). The nerve provides motor innervation to the anterior compartment of the lower leg (tibialis anterior, extensor digitorum longus, and extensor hallucis longus) to facilitate foot dorsiflexion and toe extension. It innervates the lateral compartment of the lower leg (peroneus longus and brevis) to facilitate foot eversion and contribute to plantar flexion. It also provides motor innervation to intrinsic musculature of the foot. With regard to its sensory branches, the nerve has 2 articular branches, 1 recurrent articular nerve, and a lateral sural cutaneous branch.⁴⁷ The nerve is injured in up to 16.7% of PLC injuries and is believed to be injured from the initial traction injury as well as subsequent hematoma formation and associated nerve compression.^{40,82,83} A common peroneal nerve neurolysis is performed to minimize compression on the nerve related to the initial injury or postoperative swelling.⁴⁷

The lateral inferior genicular artery emerges from the popliteal artery and courses extra-articularly along the joint capsule.⁴⁷ At the lateral aspect of the knee, the artery exists anterior to the fabellofibular ligament and posterior to the PFL.⁴⁷ At the anterior aspect of the knee, the artery travels within or adjacent to the anterolateral ligament.⁴⁷ During procedures, identification of the artery allows for differentiation of the fabellofibular ligament from the PFL, and it allows for appropriate hemostasis prior to closing to minimize peroneal nerve neuropathia.⁴⁷

Conclusion

In this study, the quantitative and qualitative relationships of the key surgical anatomy along the medial and lateral aspects of the knee were summarized. These relationships were put into context of their biomechanical and clinical functions to better understand their surgical relevance. An improved understanding of these relationships can guide a surgeon in choosing the optimal approach and reconstructive and/or repair technique for a given injury to the knee.

Disclosure

Suhas P. Dasari MD: None; Benjamin Kerzner BS: None; Luc M. Fortier BA: None; Safa Gursoy MD PhD: None; Jorge Chahla MD PhD: Paid consultant for Arthrex, CONMED Linvatec, Ossur, Smith & Nephew; Board and/or Committee Member: American Orthopaedic Society for Sports Medicine, Arthroscopy Association of North America, International Society of Arthroscopy, Knee Surgery, and Orthopaedic Sports Medicine.

References

1. LaPrade RF, Engebretsen AH, Ly TV, et al: The anatomy of the medial part of the knee. *J Bone Joint Surg Am* 89:2000-2010, 2007
2. LaPrade RF, Ly TV, Wentorf FA, et al: The posterolateral attachments of the knee: a qualitative and quantitative morphologic analysis of the fibular collateral ligament, popliteus tendon, popliteofibular ligament, and lateral gastrocnemius tendon. *Am J Sports Med* 31:854-860, 2003
3. Groot ES, Noyes FR, Butler DL, et al: Ligamentous and capsular restraints preventing straight medial and lateral laxity in intact human cadaver knees. *J Bone Joint Surg Am* 63:1257-1269, 1981
4. Phisitkul P, James SL, Wolf BR, et al: MCL injuries of the knee: current concepts review. *Iowa Orthop J* 26:77-90, 2006
5. LaPrade MD, Kennedy MI, Wijdicks CA, et al: Anatomy and biomechanics of the medial side of the knee and their surgical implications. *Sports Med Arthrosc Rev* 23:63-70, 2015
6. Wijdicks CA, Ewart DT, Nuckley DJ, et al: Structural properties of the primary medial knee ligaments. *Am J Sports Med* 38:1638-1646, 2010
7. Hassebrock JD, Gulbrandsen MT, Asprey WL, et al: Knee ligament anatomy and biomechanics. *Sports Med Arthrosc Rev* 28:80-86, 2020
8. Warren LF, Marshall JL: The supporting structures and layers on the medial side of the knee: an anatomical analysis. *J Bone Joint Surg Am* 61:56-62, 1979
9. Serra Cruz R, Olivetto J, Dean CS, et al: Superficial medial collateral ligament of the knee: anatomic augmentation with semitendinosus and gracilis tendon autografts. *Arthrosc Tech* 5:e347-e352, 2016
10. Grassi CA, Fruheling VM, Abdo JC, et al: Hamstring tendons insertion - an anatomical study. *Rev Bras Ortop* 48:417-420, 2013
11. Reina N, Abbo O, Gomez-Brouchet A, et al: Anatomy of the bands of the hamstring tendon: how can we improve harvest quality? *Knee* 20:90-95, 2013
12. Zhong S, Wu B, Wang M, et al: The anatomical and imaging study of pes anserinus and its clinical application. *Medicine (Baltimore)* 97:e0352, 2018
13. Loredi R, Hodler J, Pedowitz R, et al: Posteromedial corner of the knee: MR imaging with gross anatomic correlation. *Skeletal Radiol* 28:305-311, 1999
14. Wijdicks CA, Griffith CJ, LaPrade RF, et al: Radiographic identification of the primary medial knee structures. *J Bone Joint Surg Am* 91:521-529, 2009
15. Wijdicks CA, Griffith CJ, Johansen S, et al: Injuries to the medial collateral ligament and associated medial structures of the knee. *J Bone Joint Surg Am* 92:1266-1280, 2010
16. Griffith CJ, Wijdicks CA, LaPrade RF, et al: Force measurements on the posterior oblique ligament and superficial medial collateral ligament proximal and distal divisions to applied loads. *Am J Sports Med* 37:140-148, 2009
17. Griffith CJ, LaPrade RF, Johansen S, et al: Medial knee injury: Part 1, static function of the individual components of the main medial knee structures. *Am J Sports Med* 37:1762-1770, 2009
18. Wijdicks CA, Griffith CJ, LaPrade RF, et al: Medial knee injury: Part 2, load sharing between the posterior oblique ligament and superficial medial collateral ligament. *Am J Sports Med* 37:1771-1776, 2009
19. Robinson JR, Bull AM, Thomas RR, et al: The role of the medial collateral ligament and posteromedial capsule in controlling knee laxity. *Am J Sports Med* 34:1815-1823, 2006
20. Hughston JC, Eilers AF: The role of the posterior oblique ligament in repairs of acute medial (collateral) ligament tears of the knee. *J Bone Joint Surg Am* 55:923-940, 1973
21. Tibor LM, Marchant MH Jr., Taylor DC, et al: Management of medial-sided knee injuries, part 2: posteromedial corner. *Am J Sports Med* 39:1332-1340, 2011
22. Weimann A, Schatka I, Herbort M, et al: Reconstruction of the posterior oblique ligament and the posterior cruciate ligament in knees with posteromedial instability. *Arthroscopy* 28:1283-1289, 2012
23. Tom A, Fulkerson JP: Restoration of native medial patellofemoral ligament support after patella dislocation. *Sports Med Arthrosc Rev* 15:68-71, 2007
24. Amis AA, Firer P, Mountney J, et al: Anatomy and biomechanics of the medial patellofemoral ligament. *Knee* 10:215-220, 2003
25. Tuxøe JI, Teir M, Winge S, et al: The medial patellofemoral ligament: a dissection study. *Knee Surg Sports Traumatol Arthrosc* 10:138-140, 2002
26. Steensen RN, Dopirak RM, McDonald WG: The anatomy and isometry of the medial patellofemoral ligament: implications for reconstruction. *Am J Sports Med* 32:1509-1513, 2004
27. LaPrade RF, Wijdicks CA: Surgical technique: development of an anatomic medial knee reconstruction. *Clin Orthop Relat Res* 470:806-814, 2012
28. Dunaway DJ, Steensen RN, Wiand W, et al: The sartorial branch of the saphenous nerve: its anatomy at the joint line of the knee. *Arthroscopy* 21:547-551, 2005
29. Tennent TD, Birch NC, Holmes MJ, et al: Knee pain and the infrapatellar branch of the saphenous nerve. *J R Soc Med* 91:573-575, 1998
30. Wijdicks CA, Westerhaus BD, Brand EJ, et al: Sartorial branch of the saphenous nerve in relation to a medial knee ligament repair or reconstruction. *Knee Surg Sports Traumatol Arthrosc* 18:1105-1109, 2010
31. Ebraheim NA, Mekhail AO: The infrapatellar branch of the saphenous nerve: an anatomic study. *J Orthop Trauma* 11:195-199, 1997
32. Kennedy JC, Alexander IJ, Hayes KC: Nerve supply of the human knee and its functional importance. *Am J Sports Med* 10:329-335, 1982
33. Kerver AL, Leliveld MS, den Hartog D, et al: The surgical anatomy of the infrapatellar branch of the saphenous nerve in relation to incisions for anteromedial knee surgery. *J Bone Joint Surg Am* 95:2119-2125, 2013
34. Kartus J, Ejerhed L, Eriksson BI, et al: The localization of the infrapatellar nerves in the anterior knee region with special emphasis on central third patellar tendon harvest: a dissection study on cadaver and amputated specimens. *Arthroscopy* 15:577-586, 1999
35. Kalthur SG, Sumalatha S, Nair N, et al: Anatomic study of infrapatellar branch of saphenous nerve in male cadavers. *Ir J Med Sci* 184:201-206, 2015
36. Dellon AL, Muse VL, Scott ND, et al: A positive Tinel sign as predictor of pain relief or sensory recovery after decompression of chronic tibial nerve compression in patients with diabetic neuropathy. *J Reconstr Microsurg* 28:235-240, 2012
37. Lazaro LE, Cross MB, Lorch DG: Vascular anatomy of the patella: implications for total knee arthroplasty surgical approaches. *Knee* 21:655-660, 2014
38. Fox AJ, Wanivenhaus F, Rodeo SA: The basic science of the patella: structure, composition, and function. *J Knee Surg* 25:127-141, 2012
39. Chahla J, Murray IR, Robinson J, et al: Posterolateral corner of the knee: an expert consensus statement on diagnosis, classification, treatment,

- and rehabilitation. *Knee Surg Sports Traumatol Arthrosc* 27:2520-2529, 2019
40. LaPrade RF, Terry GC: Injuries to the posterolateral aspect of the knee. Association of anatomic injury patterns with clinical instability. *Am J Sports Med* 25:433-438, 1997
 41. Kennedy MI, Akamefula R, DePhillipo NN, et al: Fibular collateral ligament reconstruction in adolescent patients. *Arthrosc Tech* 8:e141-e145, 2019
 42. Grawe B, Schroeder AJ, Kakazu R, et al: Lateral collateral ligament injury about the knee: anatomy, evaluation, and management. *J Am Acad Orthop Surg* 26:e120-e127, 2018
 43. Kwapisz A, Mollison S, Cholewiński J, et al: Lateral extra-articular tenodesis with iliotibial band strip - a solution for anterolateral instability? *Ortop Traumatol Rehabil* 21:397-406, 2019
 44. DePhillipo NN, Cinque ME, Kennedy NI, et al: Inside-out repair of meniscal ramp lesions. *Arthrosc Tech* 6:e1315-e1320, 2017
 45. Dean RS, LaPrade RF: ACL and posterolateral corner injuries. *Curr Rev Musculoskelet Med* 13:123-132, 2020
 46. Mitchell JJ, Dean CS, Chahla J, et al: Varus-producing lateral distal femoral opening-wedge osteotomy. *Arthrosc Tech* 5:e799-e807, 2016
 47. James EW, LaPrade CM, LaPrade RF: Anatomy and biomechanics of the lateral side of the knee and surgical implications. *Sports Med Arthrosc Rev* 23:2-9, 2015
 48. Pereira GC, von Kaeppler E, Alaia MJ, et al: Calculating the position of the joint line of the knee using anatomical landmarks. *Orthopedics* 39:381-386, 2016
 49. Geeslin AG, Chahla J, Moatshe G, et al: Anterolateral knee extra-articular stabilizers: a robotic sectioning study of the anterolateral ligament and distal iliotibial band kaplan fibers. *Am J Sports Med* 46:1352-1361, 2018
 50. Godin JA, Chahla J, Moatshe G, et al: A comprehensive reanalysis of the distal iliotibial band: quantitative anatomy, radiographic markers, and biomechanical properties. *Am J Sports Med* 45:2595-2603, 2017
 51. Pietrini SD, LaPrade RF, Griffith CJ, et al: Radiographic identification of the primary posterolateral knee structures. *Am J Sports Med* 37:542-551, 2009
 52. Hildebrand G, Tompkins M, Macalena J: Fibular head as a landmark for identification of the common peroneal nerve: a cadaveric study. *Arthroscopy* 31:99-103, 2015
 53. Terry GC, LaPrade RF: The posterolateral aspect of the knee. Anatomy and surgical approach. *Am J Sports Med* 24:732-739, 1996
 54. Philippon MJ, Ferro FP, Campbell KJ, et al: A qualitative and quantitative analysis of the attachment sites of the proximal hamstrings. *Knee Surg Sports Traumatol Arthrosc* 23:2554-2561, 2015
 55. Terry GC, LaPrade RF: The biceps femoris muscle complex at the knee. Its anatomy and injury patterns associated with acute anterolateral-antemedial rotatory instability. *Am J Sports Med* 24:2-8, 1996
 56. LaPrade RF, Hamilton CD: The fibular collateral ligament-biceps femoris bursa. An anatomic study. *Am J Sports Med* 25:439-443, 1997
 57. Sanchez AR 2nd, Sugalski MT, LaPrade RF: Anatomy and biomechanics of the lateral side of the knee. *Sports Med Arthrosc Rev* 14:2-11, 2006
 58. LaPrade RF, Bollom TS, Wentorf FA, et al: Mechanical properties of the posterolateral structures of the knee. *Am J Sports Med* 33:1386-1391, 2005
 59. Hannouche D, Duparc F, Beaufile P: The arterial vascularization of the lateral tibial condyle: anatomy and surgical applications. *Surg Radiol Anat* 28:38-45, 2006
 60. Yan J, Sasaki W, Hitomi J: Anatomical study of the lateral collateral ligament and its circumferential structures in the human knee joint. *Surg Radiol Anat* 32:99-106, 2010
 61. LaPrade RF, Spiridonov SI, Coobs BR, et al: Fibular collateral ligament anatomical reconstructions: a prospective outcomes study. *Am J Sports Med* 38:2005-2011, 2010
 62. Ferrari DA, Wilson DR, Hayes WC: The effect of release of the popliteus and quadriceps force on rotation of the knee. *Clin Orthop Relat Res*: 225-233, 2003
 63. Chahla J, James EW, Cinque ME, et al: Midterm outcomes following anatomic-based popliteus tendon reconstructions. *Knee Surg Sports Traumatol Arthrosc* 26:812-818, 2018
 64. Simonian PT, Sussmann PS, van Trommel M, et al: Popliteomeniscal fasciculi and lateral meniscal stability. *Am J Sports Med* 25:849-853, 1997
 65. Stäubli HU, Birrer S: The popliteus tendon and its fascicles at the popliteal hiatus: gross anatomy and functional arthroscopic evaluation with and without anterior cruciate ligament deficiency. *Arthroscopy* 6:209-220, 1990
 66. Claes S, Vereecke E, Maes M, et al: Anatomy of the anterolateral ligament of the knee. *J Anat* 223:321-328, 2013
 67. Pękala PA, Mann MR, Pękala JR, et al: Evidence-based clinical anatomy of the popliteofibular ligament and its importance in orthopaedic surgery: cadaveric versus magnetic resonance imaging meta-analysis and radiological study. *Am J Sports Med* 49:1659-1668, 2021
 68. Musahl V, Herbst E, Burnham JM, et al: The anterolateral complex and anterolateral ligament of the knee. *J Am Acad Orthop Surg* 26:261-267, 2018
 69. Kennedy MI, Claes S, Fuso FA, et al: The anterolateral ligament: an anatomic, radiographic, and biomechanical analysis. *Am J Sports Med* 43:1606-1615, 2015
 70. Daggett M, Ockuly AC, Cullen M, et al: Femoral origin of the anterolateral ligament: an anatomic analysis. *Arthroscopy* 32:835-841, 2016
 71. Kraeutler MJ, Welton KL, Chahla J, et al: Current concepts of the anterolateral ligament of the knee: anatomy, biomechanics, and reconstruction. *Am J Sports Med* 46:1235-1242, 2018
 72. Helito CP, Bonadio MB, Soares TQ, et al: The meniscal insertion of the knee anterolateral ligament. *Surg Radiol Anat* 38:223-228, 2016
 73. Littlefield CP, Belk JW, Houck DA, et al: The anterolateral ligament of the knee: an updated systematic review of anatomy, biomechanics, and clinical outcomes. *Arthroscopy* 37:1654-1666, 2021
 74. LaPrade RF, Chahla J: Evidence-based management of complex knee injuries: restoring the anatomy to achieve best outcomes. (1st edition). St. Louis, MO: Elsevier, 2021
 75. Bolog N, Hodler J: MR imaging of the posterolateral corner of the knee. *Skeletal Radiol* 36:715-728, 2007
 76. Chahla J, Moatshe G, Dean CS, et al: Posterolateral corner of the knee: current concepts. *Arch Bone Jt Surg* 4:97-103, 2016
 77. Moorman CT 3rd, LaPrade RF: Anatomy and biomechanics of the posterolateral corner of the knee. *J Knee Surg* 18:137-145, 2005
 78. Anavian J, Marchetti DC, Moatshe G, et al: The forgotten joint: quantifying the anatomy of the proximal tibiofibular joint. *Knee Surg Sports Traumatol Arthrosc* 26(4):1096-1103, 2018
 79. Marchetti DC, Moatshe G, Phelps BM, et al: The proximal tibiofibular joint: a biomechanical analysis of the anterior and posterior ligamentous complexes. *Am J Sports Med* 45:1888-1892, 2017
 80. Horst PK, LaPrade RF: Anatomic reconstruction of chronic symptomatic anterolateral proximal tibiofibular joint instability. *Knee Surg Sports Traumatol Arthrosc* 18:1452-1455, 2010
 81. Marchetti DC, Chahla J, Moatshe G, et al: Quantitative radiographic assessment of the anatomic attachment sites of the anterior and posterior complexes of the proximal tibiofibular joint. *Knee Surg Sports Traumatol Arthrosc* 26:1104-1109, 2018
 82. DeLee JC, Riley MB, Rockwood CA Jr.: Acute posterolateral rotatory instability of the knee. *Am J Sports Med* 11:199-207, 1983
 83. Girolami M, Galletti S, Montanari G, et al: Common peroneal nerve palsy due to hematoma at the fibular neck. *J Knee Surg* 26(S 01):S132-S135, 2013