

EGLS: Echo-guided life support

An algorithmic approach to undifferentiated shock

Jean-François Lanctôt · Maxime Valois ·
Yanick Beaulieu

Received: 2 June 2011 / Accepted: 1 November 2011 / Published online: 17 November 2011
© The Author(s) 2011. This article is published with open access at Springerlink.com

Abstract

Introduction The primary challenge in the initial assessment of a patient with undifferentiated shock is to quickly identify and treat any reversible causes of shock. Bedside ultrasound provides real-time information that can assist with the achievement of this goal; as a result, it has gained widespread popularity in the field of critical care and emergency medicine. Many researchers have suggested that the use of a simple ultrasound approach to guide the management of these patients would reduce the morbidity associated with delayed or inappropriate treatment and would result in better outcomes.

Purpose With the goal of optimizing early management of critically ill patients, we describe in this article an algorithm based on simple clinical questions that combines the information provided by lung, cardiac and inferior vena cava ultrasonography.

Conclusions The advantages of this approach, in addition to efficiency, include easy reproducibility and standardization for teaching purposes and clinical trials.

Keywords Shock · Bedside ultrasound · Point-of-care ultrasound · Algorithm · Emergency · Critical care

Introduction

Point-of-care ultrasound is rapidly changing the way we assess critically ill shock patients and has become a fundamental tool in the emergency and critical care departments. It provides the real-time information that can otherwise be difficult to obtain with the “traditional” physical examination alone [1–3]. There are some data to suggest that point-of-care ultrasound could have an immediate impact on the management of shock by allowing faster diagnosis [4], which might prove to be invaluable in such a time-sensitive situation. It is therefore not surprising that some authors have proposed protocols for bedside ultrasound in cardiac arrest (FEER, PEA protocol) [5, 6], shock (UHP, Trinity, RUSH, FATE protocols) [7–10] or respiratory failure (BLUE protocol) [11]. Although no scientific evidence yet exists to support the use of one over any other, it is reasonable to assume that an algorithmic approach simplifying the use of ultrasound could lead to better and more efficient management of undifferentiated shock. Such an approach that integrates the concepts of the BLUE protocol, FOCUS cardiac exam and the EFAST protocol will be presented here. We believe that, given the intimate relationship among extra-vascular lung water, left ventricular (LV) function and the volume status in shock states, the combination of lung and cardiac ultrasonography with the EFAST exam has an added

Dr Y. Beaulieu is also the director of Ultrasound Education at CAE Healthcare.

J.-F. Lanctôt · M. Valois
Emergency Department, Charles-Lemoyne Hospital, Montreal,
QC, Canada

J.-F. Lanctôt · M. Valois
Critical Care, Verdun Hospital, Montreal, QC, Canada

J.-F. Lanctôt (✉)
5568 Woodbury, Montreal, QC H3T 1S7, Canada
e-mail: jlanctot75@hotmail.com

Y. Beaulieu
Division of Cardiology and Critical Care, Sacre-Coeur Hospital,
Montreal, QC, Canada

advantage over echocardiography or EFAST alone in undifferentiated shock patients. It may also prove to be a step forward from the “traditional” physical examination done for this condition.

Our approach is meant to complement the history, physical exam and accepted management of these patients. It has the advantage of addressing plausible pathologies in a predetermined specific sequence designed to simplify clinical reasoning. We believe this can facilitate the interpretation of the important ultrasound findings often encountered in this stressful situation. In the next sections, we will present the EGLS algorithm and later discuss its specific ultrasound components.

The EGLS algorithm

We propose, along with the corresponding ultrasound findings and implied management, a sequence of five questions designed to quickly identify and treat pathologies that have a characteristic “ultrasound signature” (Table 1). These questions are as follows (Fig. 1): (1) Is there a pneumothorax? (2) Is tamponade present? (3) Is the patient hypovolemic? (4) If poor LV function is noted, is it the main cause of shock? (5) Are there signs of right ventricular (RV) strain? The EGLS algorithm is designed to answer these questions in that specific order (i.e., specific ultrasound signs are sought in a particular order), which respect the “airway–breathing–circulation” sequence. The questions of the algorithm are organized to generate simple binary (“yes/no”) answers, which we think is essential for point-of-care ultrasound to be clinically relevant to the non-expert sonographer caring for unstable patients.

The examination sequence proposed to answer these questions begins with the lung views to rule out pneumothorax

Table 1 Etiologies of shock and associated ultrasound findings

Diagnosis	Associated ultrasound findings
Tension pneumothorax	Abolished lung sliding, no B-lines
Tamponade	Pericardial effusion with RV and RA diastolic collapse, plethoric IVC, dynamic LV
Hypovolemia	Hyperdynamic LV, IVC collapse, clear lungs
Massive pulmonary embolism	Dilated RV, “D-shape left ventricle, paradoxical septal wall movement, plethoric IVC
Myocardial infarction	Poor LV function associated with B-profile and plethoric IVC if cardiogenic shock
Toxicological, electrolyte abnormalities, acid–base disorders	Could be associated with depressed cardiac function

RV right ventricle, RA right atrium, LV left ventricle, IVC inferior vena cava

and identify the lung profile, followed by the subcostal window (four-chamber view and IVC assessment) to rule out tamponade, estimate fluid status and assess qualitative cardiac function. At this point, the clinician will often be able to confidently estimate the volume status of the shock patient. The next step of the ultrasound examination depends on whether the patient is deemed hypovolemic or not. In cases of hypovolemic shock, one should expect clear lungs (i.e. no B-lines) associated with a hyperdynamic LV and a collapsible IVC. If this is the case, only limited additional crucial information can be gained from a complete cardiac examination and a search for potential etiologies of hypovolemic shock is warranted. Hence, an EFAST examination could be considered at this point.

In cases where cardiac function cannot be clearly determined or where parts of the initial assessment do not clearly suggest hypovolemia (e.g., “discordant” findings such as a hyperdynamic LV coupled with a plethoric IVC would be an example of the latter), a complete focused cardiac examination should be performed. If poor LV function is noted and presumed to be the cause of shock (cardiogenic shock), a B-profile and plethoric IVC should be demonstrated. In cases where poor LV function is not associated with a B-profile, or is associated with a small and collapsible IVC, the clinician should be cautious before assuming that poor LV function is the main cause of shock. Once tension pneumothorax, tamponade, hypovolemic and cardiogenic shock have all been ruled out, pulmonary embolism (PE) remains a plausible cause; the clinician can now look for signs of RV strain suggesting massive pulmonary embolism.

This algorithmic approach could have many advantages. First, priority is given to conditions that can easily be reversed with simple technical or therapeutic interventions, thus assuring adequate efficiency. Second, it emphasizes one necessary feature of point-of-care ultrasound; specific ultrasound signs are sought to answer specific clinical questions. One should always put the images obtained in context and reject them if clinically irrelevant. Hence, a sixth question could be added to the algorithm: is the pathology suggested by ultrasound imaging compatible with the clinical picture?

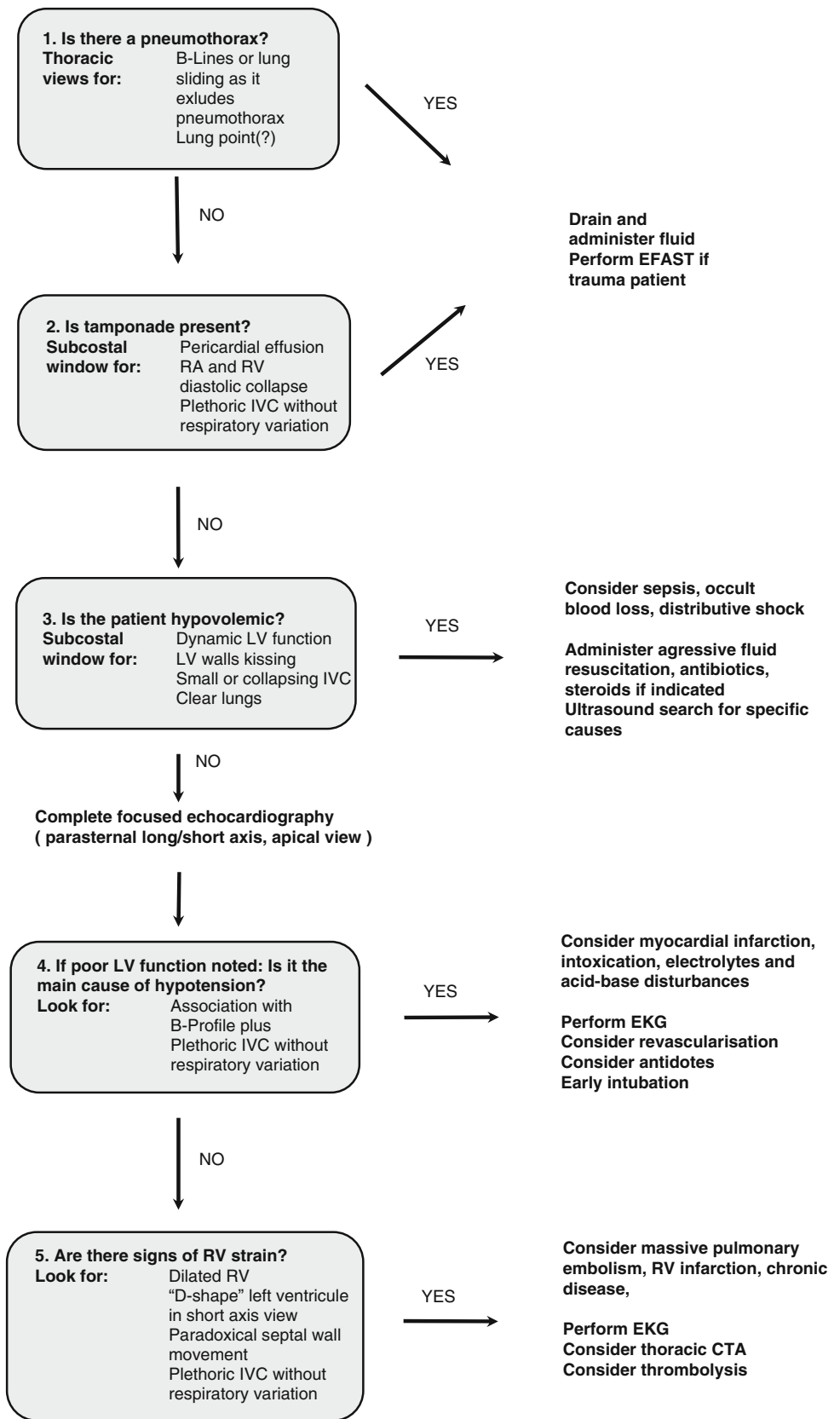
The sonographic components of EGLS

The sonographic components of EGLS are summarized in Table 1 and will be further discussed here.

Lung ultrasound

Lung ultrasound is based primarily on the detection of lung sliding and the interpretation of artifacts generated by ultrasonographic waves.

Fig. 1 The EGLS algorithm



RA=right atrium, RV=right ventricle, IVC=inferior vena cava, LV=left ventricle

Table 2 Potential causes of abolished lung sliding other than pneumothorax

Pneumonia
Acute respiratory distress syndrome (ARDS)
Pleurodesis, pleural scarring
Severe emphysema
Bronchial obstruction
Mainstem intubation
Apnea

The presence of lung sliding excludes a pneumothorax under the probe with certainty and requires a minimal training to recognize [12–15]. While not specific (Table 2), its absence in the appropriate context can be highly suggestive of a pneumothorax. The “lung point”, which is pathognomonic for a pneumothorax, is observed when lung sliding is intermittently absent from the ultrasound field at expiration [16]. A lung point might not be observed in the case of tension pneumothorax because the lung is expected to be completely collapsed.

It is also possible to detect an interstitial syndrome by observing the characteristic and reproducible artifacts called B-lines [17–19]. They represent abnormal extravascular lung water. An interstitial syndrome is defined by the presence of at least three B-lines in the width of an intercostal space (the “B-profile”). A B-profile can represent cardiogenic pulmonary edema [20–22] but is not specific for this pathology. It can also be found with other interstitial diseases, such as pulmonary fibrosis, ARDS and pulmonary contusions. The presence of a B-line also excludes a pneumothorax as it originates from the pleura [23]. Pure cardiogenic shock is unlikely to be the primary cause of hemodynamic instability in the presence of a normal lung pattern on ultrasound [20], suggesting that fluid administration is probably safe.

Focused echocardiography and fluid responsiveness

A focused bedside cardiac ultrasound comprising four views (subcostal view, parasternal long and short axis views, and apical four-chamber view) has been previously described [10, 24, 25]. It provides critical information for patient care, namely information about left/right ventricular size and function, volume status and pericardium assessment. Physicians with limited ultrasound training can correctly estimate the qualitative left ventricular function [26–28]. These qualitative assessments correlate well with quantitative assessments [29, 30].

The cardiac subcostal view is sensitive view for the detection of a pericardial effusion and it often is the only available window in critically ill patients or in the context

of cardio-pulmonary resuscitation. For those reasons, it is the initial cardiac view performed in our algorithm.

Tamponade is a diagnosis that must be considered as a reversible cause of shock in the unstable patient [2]. Bed-side ultrasound has greatly facilitated its detection as pericardial effusion can easily be demonstrated. Tamponade physiology is suggested by a pericardial effusion causing right atrial or ventricular collapse in diastole [31, 32]. It is possible to observe a pendulum movement of the heart in the presence of a massive effusion (a “swinging heart”). Tamponade should be associated with an elevated central venous pressure that can be demonstrated in the subcostal window by a plethoric (>20 mm) inferior vena cava (IVC) without respiratory variation.

Assessing the diameter of the IVC and its respiratory variation will also allow for the estimation of fluid responsiveness. An inferior vena cava diameter of less than 20 mm (measured proximal to the hepatic vein) and respiratory variation of more than 50% are associated with a normal to low central venous pressure (CVP) [33], which is a good predictor of fluid responsiveness. A small (diameter less than 10 mm) IVC has been shown to correlate with hypovolemia in the trauma patients [34]. Thus, significant respiratory variation or collapse of the IVC of patients presenting in shock should always be taken into consideration [35], especially if it is associated with a hyperdynamic left ventricle (LV) because this also suggests hypovolemia. As previously noted, dilation (more than 20 mm) and the loss of respiratory variability in the inferior vena cava suggest an elevated central venous pressure. Respiratory variation of the inferior vena cava is often altered in mechanically ventilated patients, in cirrhosis [36] and in chronic pulmonary diseases, and should be interpreted accordingly. While respiratory variation of the IVC can be a good predictor of fluid responsiveness in hypotensive patients who are mechanically ventilated [37, 38], a plethoric IVC without respiratory variation is not in and of itself a contraindication to fluid administration in this population. The lack of respiratory variation should be closely interpreted within the clinical context because, like high values of CVP, it does not necessarily imply a lack of fluid responsiveness.

The qualitative evaluation of LV function allows for further refinement in the initial evaluation of shock. The expected myocardial response in the presence of hypovolemic, distributive or obstructive shock is left ventricular hyperdynamism because these conditions are associated with poor LV filling. This may be suspected when wall “kissing” occurs in systole. A small inferior vena cava and normal lung pattern are also expected if hypovolemia is the cause of hypotension. Sepsis should be one of the first conditions considered when a hyperdynamic left ventricle is encountered in nontraumatic undifferentiated shock [39].

Another condition that can present with shock and a hyperdynamic left ventricle is severe acute mitral regurgitation as will be seen when a chordae tendinae ruptures. This could potentially be erroneously interpreted as hypovolemia by the non-expert sonologist with limited experience in Doppler technique. However, in contrast to hypovolemia, severe acute mitral regurgitation would likely be associated with a B-profile and less compliant inferior vena cava (as it is associated with higher filling pressures). This constitutes an example where, as stated before, lung ultrasound findings can influence the echocardiographic interpretation.

Focused echocardiography showing left ventricular hypokinesia may be an indicative of cardiogenic shock. If poor cardiac function is the cause of shock, the clinician should usually be able to demonstrate a B-profile on lung ultrasound (along with a plethoric IVC). Indeed, LV dysfunction severe enough to cause cardiogenic shock is expected to be associated with high filling pressures. The foreknowledge of lung pattern may thus help in interpreting the subsequent echocardiography findings because a hypokinetic left ventricle associated with a normal lung pattern suggests cardiac co-morbidity (i.e., chronically depressed LV function) rather than pure cardiogenic shock, more so in the presence of a small IVC. One should also consider other pathologies in this situation and provide adequate fluid resuscitation, with the caveat that resuscitation may be complicated given the limited cardiac reserve. In addition to myocardial ischemia, other potentially reversible conditions causing myocardial dysfunction can be considered and are listed in Table 1.

Pulmonary embolism (PE) is also a cause of undifferentiated shock. Hemodynamically significant PE is consistently associated with acute right ventricular strain [40]. Signs suggesting the right ventricular strain can often be found in the apical four-chamber and parasternal short-axis views. Increased pressure may lead to paradoxical movement of the septum wall [41] and give rise to a “D-shape” left ventricle in the short-axis view. The obstructive shock caused by pulmonary embolism is expected to be associated with a plethoric inferior vena cava without respiratory variation. The sonologist should be aware that smaller PEs not large enough to cause hemodynamic compromise do not consistently cause identifiable cardiac sonographic findings [42].

Discussion

The EGLS algorithm uses lung ultrasound as a point of departure to complement focused echocardiographic and EFAST exams and as such is novel. It comprehensively integrates concepts and parts of protocols already well described in the literature and could provide a general

framework for guiding point-of-care ultrasound use in shock management. Indeed, although ultrasound may not always be necessary to answer the five questions of the EGLS algorithm, the clinician faced with undifferentiated shock will often have to address these issues. Furthermore, physicians already using other protocols (such as FATE or FOCUS) can easily integrate them in the EGLS framework.

An algorithm is well suited for the undifferentiated shock assessment because the initial management of this entity requires efficient decision making and rapid identification of reversible causes. Each step of the EGLS algorithm is designed to achieve these goals. It is structured to identify one type of shock at a time, which allows the sonographer to choose the most pertinent views and focus on the proper findings. This might improve the overall accuracy of the sonographic examination and limit overzealous interpretation. It may also reduce the time needed to perform the examination. EGLS can easily be adapted to scenarios in which only parts of the algorithm are performed because it stems from methodical reasoning and a sonographic approach tailored to the ultrasound findings encountered. All these features could help the physicians with minimal experience integrate point-of-care ultrasound in shock management.

Recommendations regarding training and education in point-of-care ultrasound have been described elsewhere [43–45] and the acquisition of the necessary skills could be facilitated by the addition of new learning modalities, such as simulators, to practical training sessions. Although some studies suggest that ultrasound use can improve the management of shock, randomized controlled trials are needed to evaluate the clinical impact of an algorithmic approach. Managing shock patients with a “sonoscope” might then become the standard of care. It is, at the very least, an exciting prospect.

Acknowledgments The authors would like to thank Dr Pierre Pascual for helpful discussions.

Conflict of interest None.

Open Access This article is distributed under the terms of the Creative Commons Attribution Noncommercial License which permits any noncommercial use, distribution, and reproduction in any medium, provided the original author(s) and source are credited.

References

1. Kaul S, Stratienco AA, Pollock SG, Marieb MA, Keller MW, Sabia PJ (1994) Value of two-dimensional echocardiography for determining the basis of hemodynamic compromise in critically ill patients: a prospective study. *J Am Soc Echocardiogr: Off publication Am Soc Echocardiogr* 7(6):598–606
2. Joseph MX, Disney PJ, Da Costa R, Hutchison SJ (2004) Transthoracic echocardiography to identify or exclude cardiac

- cause of shock. *Chest* 126(5):1592–1597. doi:[10.1378/chest.126.5.1592](https://doi.org/10.1378/chest.126.5.1592)
3. Tayal VS, Kline JA (2003) Emergency echocardiography to detect pericardial effusion in patients in PEA and near-PEA states. *Resuscitation* 59(3):315–318
 4. Jones AE, Tayal VS, Sullivan DM, Kline JA (2004) Randomized, controlled trial of immediate versus delayed goal-directed ultrasound to identify the cause of nontraumatic hypotension in emergency department patients. *Crit Care Med* 32(8):1703–1708
 5. Breitzkreutz R, Walcher F, Seeger FH (2007) Focused echocardiographic evaluation in resuscitation management: concept of an advanced life support-conformed algorithm. *Crit Care Med* 35(5 Suppl):S150–S161. doi:[10.1097/01.CCM.0000260626.23848.FC](https://doi.org/10.1097/01.CCM.0000260626.23848.FC)
 6. Testa A, Cibinel GA, Portale G, Forte P, Giannuzzi R, Pignataro G, Silveri NG (2010) The proposal of an integrated ultrasonographic approach into the ALS algorithm for cardiac arrest: the PEA protocol. *Eur Review Med Pharmacol Sci* 14(2):77–88
 7. Rose JS, Bair AE, Mandavia D, Kinsler DJ (2001) The UHP ultrasound protocol: a novel ultrasound approach to the empiric evaluation of the undifferentiated hypotensive patient. *Am J Emerg Med* 19(4):299–302. doi:[10.1053/ajem.2001.24481](https://doi.org/10.1053/ajem.2001.24481)
 8. Bahner D (2002) Trinity: a hypotensive ultrasound protocol journal of diagnostic medical sonography. *J Diagn Med Sonogr* 18:193–198
 9. Perera P, Mailhot T, Riley D, Mandavia D (2010) The RUSH exam: Rapid Ultrasound in SHock in the evaluation of the critically ill. *Emerg Med Clin North Am* 28(1):29–56. doi:[10.1016/j.emc.2009.09.010](https://doi.org/10.1016/j.emc.2009.09.010)
 10. Jensen MB, Sloth E, Larsen KM, Schmidt MB (2004) Trans-thoracic echocardiography for cardiopulmonary monitoring in intensive care. *Eur J Anaesthesiol* 21(9):700–707
 11. Lichtenstein DA, Meziere GA (2008) Relevance of lung ultrasound in the diagnosis of acute respiratory failure: the BLUE protocol. *Chest* 134(1):117–125. doi:[10.1378/chest.07-2800](https://doi.org/10.1378/chest.07-2800)
 12. Blaivas M, Lyon M, Duggal S (2005) A prospective comparison of supine chest radiography and bedside ultrasound for the diagnosis of traumatic pneumothorax. *Acad Emerg Med: Off J Soc Acad Emerg Med* 12(9):844–849. doi:[10.1197/j.aem.2005.05.005](https://doi.org/10.1197/j.aem.2005.05.005)
 13. Dulchavsky SA, Schwarz KL, Kirkpatrick AW, Billica RD, Williams DR, Diebel LN, Campbell MR, Sargysan AE, Hamilton DR (2001) Prospective evaluation of thoracic ultrasound in the detection of pneumothorax. *J Trauma* 50(2):201–205
 14. Lichtenstein DA, Menu Y (1995) A bedside ultrasound sign ruling out pneumothorax in the critically ill. *Lung sliding*. *Chest* 108(5):1345–1348
 15. Lichtenstein DA, Meziere G, Lascols N, Biderman P, Courret JP, Gepner A, Goldstein I, Tenoudji-Cohen M (2005) Ultrasound diagnosis of occult pneumothorax. *Crit Care Med* 33(6):1231–1238
 16. Lichtenstein D, Meziere G, Biderman P, Gepner A (2000) The “lung point”: an ultrasound sign specific to pneumothorax. *Intensive Care Med* 26(10):1434–1440
 17. Lichtenstein D, Meziere G, Biderman P, Gepner A, Barre O (1997) The comet-tail artifact. An ultrasound sign of alveolar-interstitial syndrome. *Am J Respir Crit Care Med* 156(5):1640–1646
 18. Lichtenstein D, Meziere G (1998) A lung ultrasound sign allowing bedside distinction between pulmonary edema and COPD: the comet-tail artifact. *Intensive Care Med* 24(12):1331–1334
 19. Volpicelli G, Mussa A, Garofalo G, Cardinale L, Casoli G, Perotto F, Fava C, Frascisco M (2006) Bedside lung ultrasound in the assessment of alveolar-interstitial syndrome. *Am J Emerg Med* 24(6):689–696. doi:[10.1016/j.ajem.2006.02.013](https://doi.org/10.1016/j.ajem.2006.02.013)
 20. Lichtenstein DA, Meziere GA, Lagoueyte JF, Biderman P, Goldstein I, Gepner A (2009) A-lines and B-lines: lung ultrasound as a bedside tool for predicting pulmonary artery occlusion pressure in the critically ill. *Chest* 136(4):1014–1020. doi:[10.1378/chest.09-0001](https://doi.org/10.1378/chest.09-0001)
 21. Agricola E, Bove T, Oppizzi M, Marino G, Zangrillo A, Margonato A, Picano E (2005) “Ultrasound comet-tail images”: a marker of pulmonary edema: a comparative study with wedge pressure and extravascular lung water. *Chest* 127(5):1690–1695. doi:[10.1378/chest.127.5.1690](https://doi.org/10.1378/chest.127.5.1690)
 22. Liteplo AS, Marill KA, Villen T, Miller RM, Murray AF, Croft PE, Capp R, Noble VE (2009) Emergency thoracic ultrasound in the differentiation of the etiology of shortness of breath (ETUDES): sonographic B-lines and N-terminal pro-brain-type natriuretic peptide in diagnosing congestive heart failure. *Acad Emerg Med: Off J Soc Acad Emerg Med* 16(3):201–210. doi:[10.1111/j.1553-2712.2008.00347.x](https://doi.org/10.1111/j.1553-2712.2008.00347.x)
 23. Lichtenstein D, Meziere G, Biderman P, Gepner A (1999) The comet-tail artifact: an ultrasound sign ruling out pneumothorax. *Intensive Care Med* 25(4):383–388
 24. Beaulieu Y, Marik PE (2005) Bedside ultrasonography in the ICU: part 1. *Chest* 128(2):881–895. doi:[10.1378/chest.128.2.881](https://doi.org/10.1378/chest.128.2.881)
 25. Beaulieu Y, Marik PE (2005) Bedside ultrasonography in the ICU: part 2. *Chest* 128(3):1766–1781. doi:[10.1378/chest.128.3.1766](https://doi.org/10.1378/chest.128.3.1766)
 26. Moore CL, Rose GA, Tayal VS, Sullivan DM, Arrowood JA, Kline JA (2002) Determination of left ventricular function by emergency physician echocardiography of hypotensive patients. *Acad Emerg Med: Off J Soc Acad Emerg Med* 9(3):186–193
 27. Randazzo MR, Snoey ER, Levitt MA, Binder K (2003) Accuracy of emergency physician assessment of left ventricular ejection fraction and central venous pressure using echocardiography. *Acad Emerg Med: Off J Soc Acad Emerg Med* 10(9):973–977
 28. Alexander JH, Peterson ED, Chen AY, Harding TM, Adams DB, Kisslo JA Jr (2004) Feasibility of point-of-care echocardiography by internal medicine house staff. *Am Heart J* 147(3):476–481. doi:[10.1016/j.ahj.2003.10.010](https://doi.org/10.1016/j.ahj.2003.10.010)
 29. Gudmundsson P, Rydberg E, Winter R, Willenheimer R (2005) Visually estimated left ventricular ejection fraction by echocardiography is closely correlated with formal quantitative methods. *Int J Cardiol* 101(2):209–212. doi:[10.1016/j.ijcard.2004.03.027](https://doi.org/10.1016/j.ijcard.2004.03.027)
 30. Hope MD, de la Pena E, Yang PC, Liang DH, McConnell MV, Rosenthal DN (2003) A visual approach for the accurate determination of echocardiographic left ventricular ejection fraction by medical students. *J Am Soc Echocardiogr: Off Publ Am Soc Echocardiogr* 16(8):824–831. doi:[10.1067/S0894-7317\(03\)00400-0](https://doi.org/10.1067/S0894-7317(03)00400-0)
 31. Armstrong WF, Schilt BF, Helper DJ, Dillon JC, Feigenbaum H (1982) Diastolic collapse of the right ventricle with cardiac tamponade: an echocardiographic study. *Circulation* 65(7):1491–1496
 32. Gillam LD, Guyer DE, Gibson TC, King ME, Marshall JE, Weyman AE (1983) Hydrodynamic compression of the right atrium: a new echocardiographic sign of cardiac tamponade. *Circulation* 68(2):294–301
 33. Kircher BJ, Himelman RB, Schiller NB (1990) Noninvasive estimation of right atrial pressure from the inspiratory collapse of the inferior vena cava. *Am J Cardiol* 66(4):493–496
 34. Yanagawa Y, Nishi K, Sakamoto T, Okada Y (2005) Early diagnosis of hypovolemic shock by sonographic measurement of inferior vena cava in trauma patients. *J Trauma* 58(4):825–829
 35. Charron C, Caille V, Jardin F, Vieillard-Baron A (2006) Echocardiographic measurement of fluid responsiveness. *Curr Opin Crit Care* 12(3):249–254. doi:[10.1097/01.ccx.0000224870.24324.cc](https://doi.org/10.1097/01.ccx.0000224870.24324.cc)

36. Kitamura H, Kobayashi C (2005) Impairment of change in diameter of the hepatic portion of the inferior vena cava: a sonographic sign of liver fibrosis or cirrhosis. *J Ultrasound Med: Off J Am Inst Ultrasound Med* 24(3):355–359; quiz 360–351
37. Feissel M, Michard F, Faller JP, Teboul JL (2004) The respiratory variation in inferior vena cava diameter as a guide to fluid therapy. *Intensive Care Med* 30(9):1834–1837. doi:[10.1007/s00134-004-2233-5](https://doi.org/10.1007/s00134-004-2233-5)
38. Barbier C, Loubieres Y, Schmit C, Hayon J, Ricome JL, Jardin F, Vieillard-Baron A (2004) Respiratory changes in inferior vena cava diameter are helpful in predicting fluid responsiveness in ventilated septic patients. *Intensive Care Med* 30(9):1740–1746. doi:[10.1007/s00134-004-2259-8](https://doi.org/10.1007/s00134-004-2259-8)
39. Jones AE, Craddock PA, Tayal VS, Kline JA (2005) Diagnostic accuracy of left ventricular function for identifying sepsis among emergency department patients with nontraumatic symptomatic undifferentiated hypotension. *Shock* 24(6):513–517
40. Kasper W, Meinertz T, Kersting F, Lollgen H, Limbourg P, Just H (1980) Echocardiography in assessing acute pulmonary hypertension due to pulmonary embolism. *Am J Cardiol* 45(3):567–572
41. Jardin F, Dubourg O, Gueret P, Delorme G, Bourdarias JP (1987) Quantitative two-dimensional echocardiography in massive pulmonary embolism: emphasis on ventricular interdependence and leftward septal displacement. *J Am Coll Cardiol* 10(6):1201–1206
42. Beaulieu Y (2007) Bedside echocardiography in the assessment of the critically ill. *Crit Care Med* 35(5 Suppl):S235–S249. doi:[10.1097/01.CCM.0000260673.66681.AF](https://doi.org/10.1097/01.CCM.0000260673.66681.AF)
43. Mayo PH, Beaulieu Y, Doelken P, Feller-Kopman D, Harrod C, Kaplan A, Oropello J, Vieillard-Baron A, Axler O, Lichtenstein D, Maury E, Slama M, Vignon P (2009) American College of Chest Physicians/La Societe de Reanimation de Langue Francaise statement on competence in critical care ultrasonography. *Chest* 135(4):1050–1060. doi:[10.1378/chest.08-2305](https://doi.org/10.1378/chest.08-2305)
44. Labovitz AJ, Noble VE, Bierig M, Goldstein SA, Jones R, Kort S, Porter TR, Spencer KT, Tayal VS, Wei K (2010) Focused cardiac ultrasound in the emergent setting: a consensus statement of the american society of echocardiography and American College of Emergency Physicians. *J Am Soc Echocardiogr: Off Publ Am Soc Echocardiogr* 23(12):1225–1230. doi:[10.1016/j.echo.2010.10.005](https://doi.org/10.1016/j.echo.2010.10.005)
45. Price S, Via G, Sloth E, Guarracino F, Breitzkreutz R, Catena E, Talmor D (2008) Echocardiography practice, training and accreditation in the intensive care: document for the world interactive network focused on critical ultrasound (WINFOCUS). *Cardiovasc Ultrasound* 6:49. doi:[10.1186/1476-7120-6-49](https://doi.org/10.1186/1476-7120-6-49)