

See discussions, stats, and author profiles for this publication at: <https://www.researchgate.net/publication/338288142>

Erector Spinae Block for Analgesia: A Safe and Novel Technique with Diverse Applications

Article · August 2019

DOI: 10.37080/nmj.32

CITATIONS

2

READS

29

6 authors, including:



Ninadini Shrestha

Institute of Medicine

29 PUBLICATIONS 68 CITATIONS

SEE PROFILE



Bigen Man Shakya

Tribhuvan University Institute of Medicine

19 PUBLICATIONS 28 CITATIONS

SEE PROFILE



Anil Shrestha

Tribhuvan University

27 PUBLICATIONS 35 CITATIONS

SEE PROFILE

Some of the authors of this publication are also working on these related projects:



MD Thesis [View project](#)

Erector Spinae Block for Analgesia : A Safe and Novel Technique with Diverse Applications

Ninadini Shrestha,¹ Bigen Man Shakya,¹ Binita Acharya,¹ Anil Shrestha,¹ Renu Gurung,¹ Utsav Acharya¹

¹Department of Anaesthesiology, Maharajgunj Medical Campus, Tribhuvan University,

ABSTRACT

Erector Spinae Block is a paraspinal musculofascial plane block where we inject local anesthetics superficial to the tip of the transverse processes and deep to the erector spinae muscle. It works at the origin of spinal nerves based on cadaveric and contrast study. It is effective and safe regional anesthetic technique. It has a wide variety of applications ranging from acute postoperative pain treatment to chronic pain management. In this series, we report a series of two cases, which include postoperative pain management in Partial Nephrectomy and chronic pain management in Post Herpetic Neuralgia.

Keywords: Analgesia; erector spinae block; regional.

INTRODUCTION

Erector Spinae Plane Block is a paraspinal musculofascial plane block where we inject local anesthetics superficial to the tip of the transverse processes and deep to the erector spinae muscle with the help of an ultrasound. The erector spinae plane (ESP) block was described as a new regional anesthetic technique for acute and chronic thoracic pain in 2016.¹ Since this description, its use has been expanding to control acute pain as well as chronic pain in thoracic surgery, rib fractures, breast surgery, urosurgery, Gastrointestinal surgery, Renal Transplant donor as well as recipient and many more. The expanding wide application as well as popularity of this block is due to the fact that this block is relatively easy block to learn and apply technically. This block gives wide area of coverage as well as we are far away from spinal cord, pleura and blood vessels making it safer technique of regional anesthesia. The drug is deposited close to costovertebral foramina at the origin of dorsal and ventral rami.² Cadaveric studies have showed that

block at T5 level is sufficient to have unilateral multidermatomal sensory block ranging from T1 to L3.³ It is proposed to work at the origin of spinal nerves in the neural foramina as well as spread is also seen to epidural space, lumbar plexus and sympathetic chain, based on cadaveric and contrast studies.⁴ Continuous Erector Spinae Plane Block has been reported to provide analgesic even in Anticoagulated Patients After Left Ventricular Assist Device Implantation.⁵ We present 2 cases of a single shot and continuous catheter infusion technique.

CASE REPORT I:

A 57 year old gentleman, weight 70kg height 160cm was admitted to undergo Right Partial Nephrectomy for Right renal cystic mass. He was a known case of Bronchial Asthma and was receiving bronchodilator therapy. Right Partial Nephrectomy was performed under general anesthesia in the lateral position. After surgery, in the lateral position, the skin was sterilized. After placing a 5–12 MHz linear ultrasound probe parallel to the vertebral axis at the level of the T12, the probe was moved from medial side to lateral side transversely to identify rectangular shape of the transverse process (TP). A22-gauge Quincke needle was

Correspondance:

Dr. Bigen Man Shakya,

Department of Anaesthesiology, Maharajgunj Medical Campus, Tribhuvan University.

Email: shakya.bigen@gmail.com, Phone: +977-9803517471.

inserted toward the Lattissimus Dorsi, erector spinae and the TP of T12 using the in-plane technique in a cephalad-to-caudal direction. After the needle made contact with the TP, we confirmed the fascial plane with hydrolocation injecting 2 ml of saline. Then, we injected the prepared mixture of 0.125% Bupivacaine 30 ml on right erector spine fascial plane. He had good pain relief postoperatively with the sensory level of T6-L2.

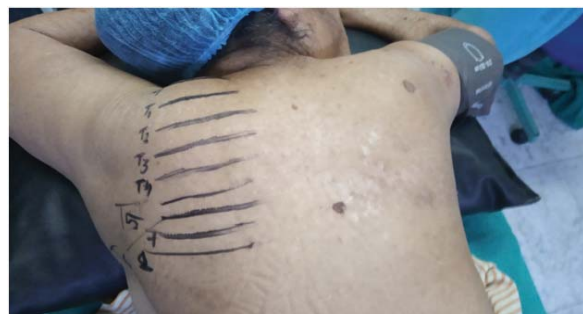CASE REPORT II:

A seventy two year old lady, weight 40 kg and height 148cm (body mass index (BMI), presented to the Pain Management clinic with chief complaints of severe burning pain over right chest wall of one month origin. She had no history of any other co-morbidities. She had suffered from Acute severe episode of Herpes Zoster over her right hemithorax two months back which had left her with scarring and pigmentation over the skin of same area. All her investigations were normal and was referred with the provisional diagnosis of Post Herpetic Neuralgia. She reported constant burning and occasional stabbing neuropathic pain of 10/10 severity on the numerical rating score (NRS), radiating from her axilla to her right breast nipple area , mainly at T5, T6. We used DN4 questionnaire to diagnose her pain score of 8/10 to be of neuropathic origin. There was significant sleep disturbance and impairment of quality of life. Physical examination revealed allodynia and hyperesthesia over the affected dermatomes with a primary trigger point over the T5 T6 dermatome in the mid axillary line. Pain management up to that point had included Gabapentin (900 mg daily at the time of consultation), nonsteroidal anti-inflammatory drugs, Baclofen, Tricyclic Antidepressant, Paracetamol and codeine with no improvement. Several different opioids had been tried but all had to be stopped due to severe nausea and vomiting and dizziness. Non-systemic and non-pharmacologic methods of analgesia had also been attempted without success including trans- cutaneous electrical nerve stimulation, acupuncture, and topical application of

lignocaine, Lignocaine patch application.

The symptoms were refractory to oral pharmacological as well as non-pharmacological techniques. Hence we attempted a regional anesthetic technique in the operation theatre to provide some immediate relief. We did a right sided T4 single shot ultrasound guided paravertebral injection with 15ml 0.2% Bupivacaine with Depot preparation of Methylprednisolone 80mg. She had good relief for 2 days with return of pain to similar intensity within fifth day of intervention. We decided however to use the same principle of local anesthetic spread to Dorsal root ganglion by performing a thoracic epidural steroid injection at T5 spinous process. This also resulted in good relief for two days followed by return of pain to NRS 7/10 with slight improved sleeping habits. She still had impairment of quality of life. Hence we opted for a continuous catheter interfascial plane block, the Erector Spinae Plane block, which was less invasive, with similar coverage of dermatomal spread of local anaesthetics.

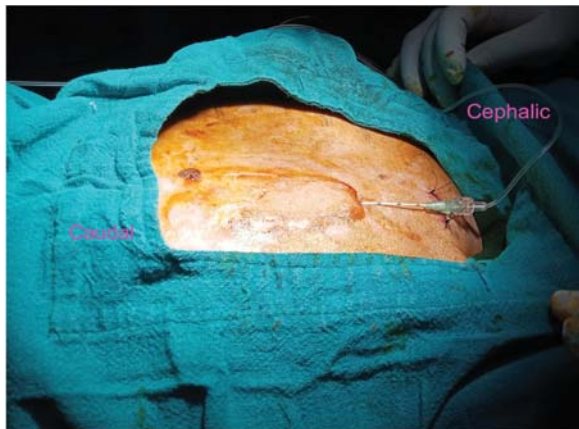
The patient was placed in a prone position and after taking all necessary aseptic precaution, a high-frequency linear ultrasound transducer was placed in an axial orientation first to accurately localise the dermatome level using the spinous processes of thoracic spine (Picture 1).



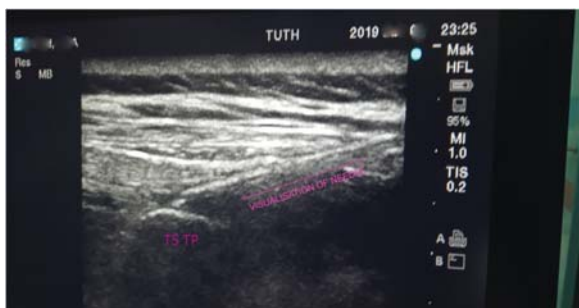
PICTURE 1: Localising the dermatome level with ultrasound using spinous processes of thoracic spine

The transducer was then placed in a longitudinal orientation and moved slightly

laterally till the transverse process was visualized at T5. Three muscles superficial to the transverse process were identified as Trapezius, Rhomboids Major and Erector spinae from superficial to deep. Then using a continuous perineural catheter with catheter over needle technique, it was placed deep to the erector spinae muscle cranial to caudal direction and fixed on the skin with 3.0 silk suture (Picture 2)(Picture3).



Picture 2: Placement of Erector Spinae continuous catheter at T5 level



Picture 3: Ultrasound imaging showing the placement of needle at TP.

Its position was visualized under ultrasonography and confirmed with separation of erector spinae muscle from the transverse process on injecting 2ml of Normal Saline on hydrolocation. 15ml of 0.2% of Ropivacaine was injected as bolus and then attached to a continuous infusion regimen of Ropivacaine 0.2% at 8–10 ml/h6. She had dermatome coverage from T1 to T8 with good pain relief.

DISCUSSION

The single-shot ESP improved the pain but had only few hours of relief despite the use of long-acting local anesthetics due to systemic absorption of local anesthetic. This has led to a better choice of inserting a catheter in patients, which has allowed us to provide prolonged analgesia for acute post operative as well as chronic pain. We conclude that ultrasound-guided ESP block is an safe, novel and excellent regional anaesthesia technique with wide applications.

CONSENT: NMJ Case Report Consent Form has been signed by the patient.

CONFLICT OF INTEREST: None.

REFERENCES

1. Forero M, Adhikary SD, Lopez H, et al. The erector spinae plane block: a novel analgesic technique in thoracic neuropathic pain. *Reg Anesth Pain Med.* 2016;41(5):621–627.
2. Chin KJ, Adhikary S, Sarwani N, Forero M. The analgesic efficacy of preoperative bilateral erector spinae plane (ESP) blocks in patients having ventral hernia repair. *Anaesthesia.* 2017;72:452–60.
3. Adhikary SD, Pruet A, Forero M, Thiruvengatarajan V. Erector spinae plane block as an alternative to epidural analgesia for post-operative analgesia following video-assisted thoracoscopic surgery: A case study and a literature review on the spread of local anaesthetic in the erector spinae plane. *Indian J Anaesth.* 2018 Jan; 62(1):75-78.
4. El-Boghdadly K, Pawa A. The erector spinae plane block: Plane and simple. *Anaesthesia.* 2017;72:427–38.
5. Adhikary, S., Prasad, A., Soleimani, B., & Chin, K. J. Continuous Erector Spinae Plane Block as an Effective Analgesic Option in Anticoagulated Patients After Left Ventricular Assist Device Implantation: A Case Series. *Journal of cardiothoracic and vascular anaesthesia.* 2019;33(4):1063-1067.
6. CRUZ ENGHILLENN, CHINKI JINN, ADHIKARYSANJIB D, How I Do It: Erector Spinae Block for Rib Fractures: ASRA NEWS. *The Penn State Health Experience;* 1 FEBRUARY 2018