



**European Society of
MusculoSkeletal Radiology**

Musculoskeletal Ultrasound Technical Guidelines

V. Knee

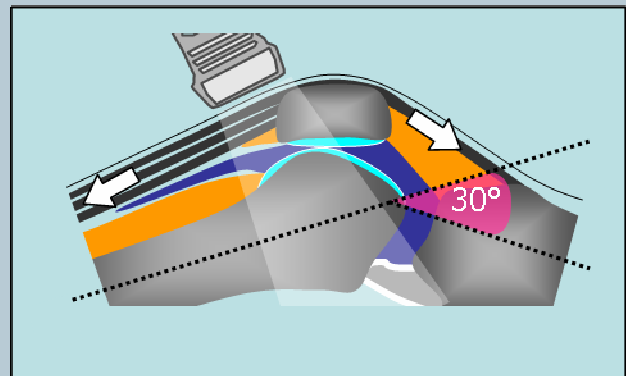
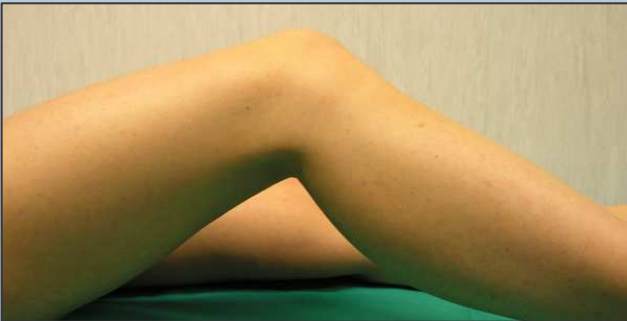Ian Beggs, UK
Stefano Bianchi, Switzerland
Angel Bueno, Spain
Michel Cohen, France
Michel Court-Payen, Denmark
Andrew Grainger, UK
Franz Kainberger, Austria
Andrea Klauser, Austria
Carlo Martinoli, Italy
Eugene McNally, UK
Philip J. O'Connor, UK
Philippe Peetrans, Belgium
Monique Reijnierse, The Netherlands
Philipp Rempik, Germany
Enzo Silvestri, Italy

Note

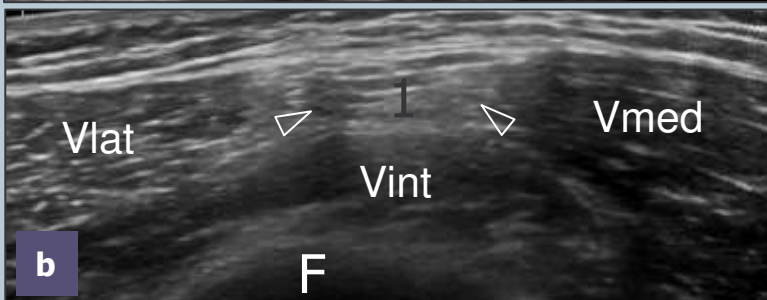
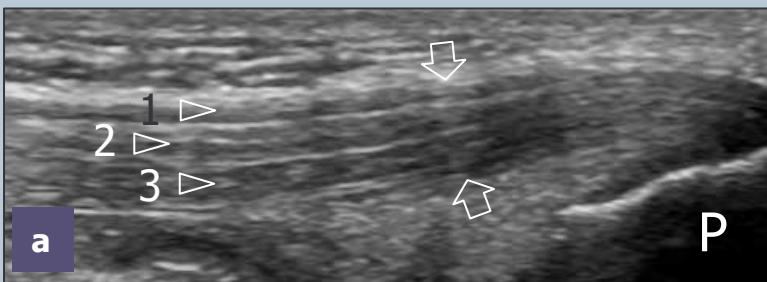
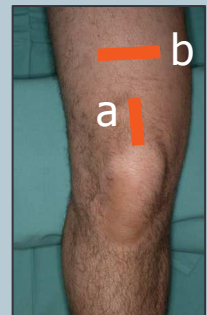The systematic scanning technique described below is only theoretical, considering the fact that the examination of the knee is, for the most, focused to one quadrant only of the joint based on clinical findings.

1 ANTERIOR KNEE: quadriceps tendon

The anterior aspect of the knee is examined with the patient supine. A knee flexion of approximately 20°-30° obtained by placing a small pillow beneath the popliteal space stretches the extensor mechanism and avoids possible anisotropy related to the concave profile that the quadriceps and patellar tendons assume in full extension.



Sagittal US images obtained in the midline while keeping the distal edge of the probe over the patella display the quadriceps tendon. On long-axis and short-axis planes, observe the multilayered appearance of this tendon due to the close apposition and distal union of the three tendon layers arising from the bellies of the quadriceps femoris muscle. The ability to discriminate among the individual tendon components has practical value to allow differentiation between full-thickness (three layers involved) and partial-thickness (one/two layers involved) tears.

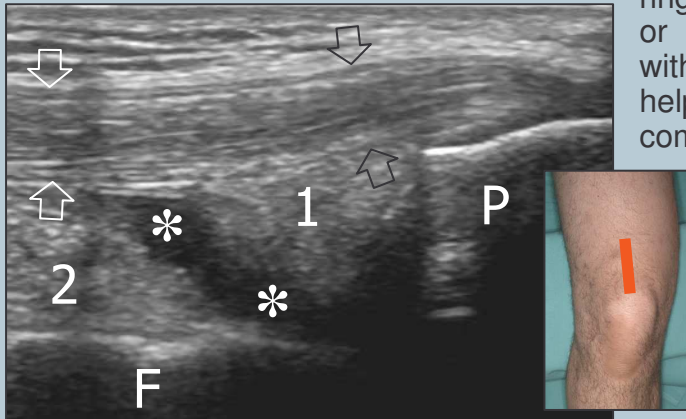


Shifting the transducer cranially on axial planes, the myotendinous junctions of the quadriceps femoris can be appreciated: the one of the rectus femoris is located at a more proximal level compared with those of the vastus muscles.

Legend: arrows, quadriceps tendon; 1, superficial layer (from rectus femoris); 2, intermediate layer (from vastus lateralis and vastus medialis); 3, deep layer (from vastus intermedius); F, femur; P, patella; Vlat, vastus lateralis muscle; Vmed, vastus medialis muscle; Vint, vastus intermedius muscle

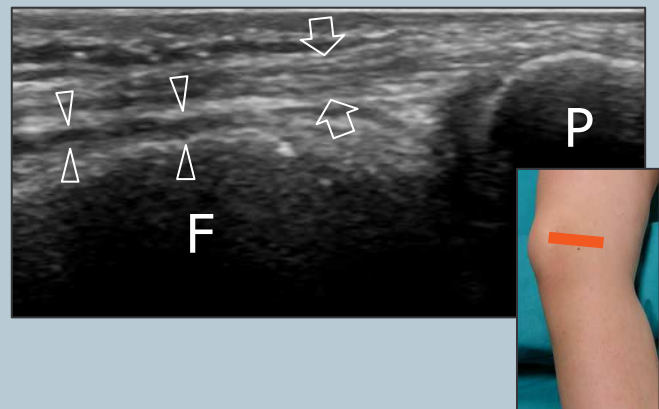
2 suprapatellar and parapatellar joint recesses

Deep to the distal third of the quadriceps tendon, the suprapatellar fat pad is found just cranially to the patella. Immediately superficial to the femur, the prefemoral fat pad appears as a large hyperechoic space. The suprapatellar synovial recess lies deep to the quadriceps tendon and the suprapatellar fat pad and superficial to the prefemoral fat; in normal states, it appears as a thin hypoechoic S-shaped space. Dynamic scanning during isometric contraction of the quadriceps or squeezing the parapatellar recesses with the non-examining hand may be helpful to detect small effusions. If needed, compression with the probe may help to differentiate effusion and synovial thickening.



Legend: arrows, quadriceps tendon; asterisks, suprapatellar synovial recess; 1, suprapatellar fat pad; 2, prefemoral fat pad; F, femur; P, patella

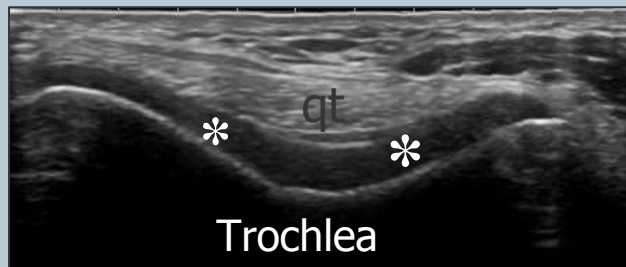Imaging should be extended over the lateral and medial sides of the quadriceps tendon because small synovial fluid tend to accumulate in the lateral and medial parts of the suprapatellar recess (which are dependent with the patient supine) and within the parapatellar recesses.



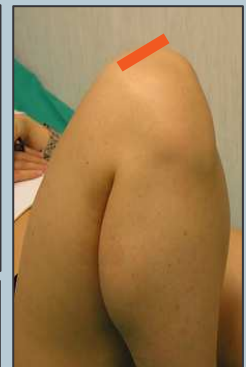Legend: arrowheads, lateral parapatellar recess; arrows, medial patellar retinaculum; F, femur; P, patella

3 femoral trochlea

With full knee flexion, the femoral V-shaped trochlea and the overlying articular cartilage are examined on axial planes. In this position, the quadriceps tendon is pushed anteriorly by the femoral trochlea and assumes a curved course over it.

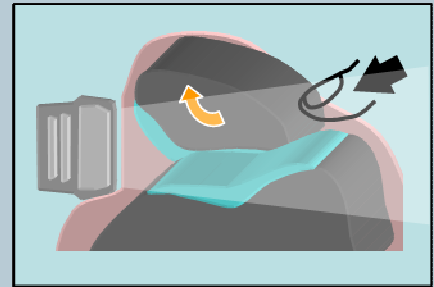


Legend: arrows, articular cartilage of the trochlea; qt, quadriceps tendon

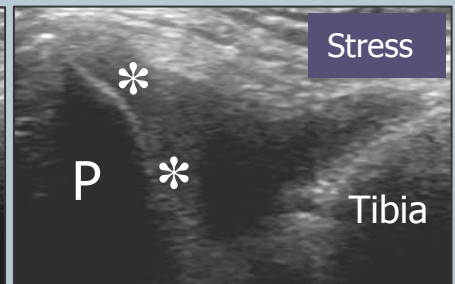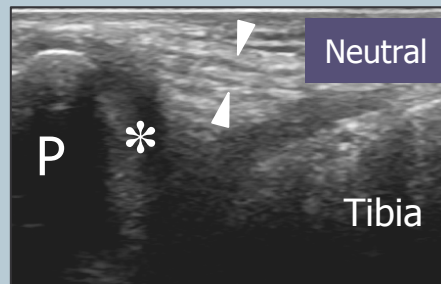


3 patellar retinacula and patellar medial articular facet

The medial and lateral retinacula are imaged on each side of the patella by means of axial planes: they appear as bilayered structures that cannot be discriminated from the underlying joint capsule. An attempt to evaluate the medial articular facet of the patella with US can be made by tilting and pushing the transducer internally while keeping the knee extended. The lateral facet is not visible with US.

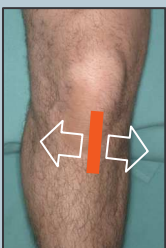

Legend: arrowheads, medial patellar retinaculum; asterisks, articular cartilage of the medial facet of the patella; P, patella

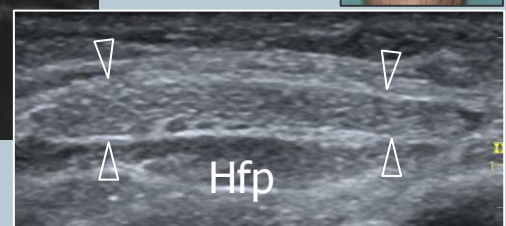
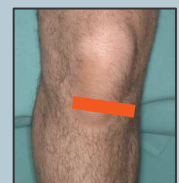
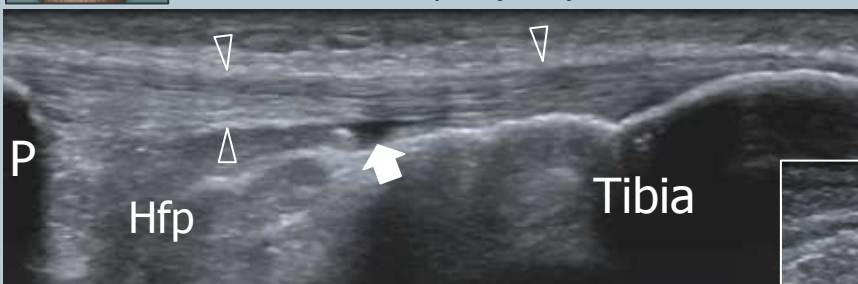
Check the prepatellar bursa, which is located over the lower pole of the patella and the proximal patellar tendon: in normal conditions, the bursa is not visible with US. Avoid excessive pressure with the probe over this bursa not to squeeze the fluid away from the field-of-view of the US image. Much gel may help to avoid excessive pressure on the bursa with the probe.

4 patellar tendon



With patient's positioning described at point-1, examine the patellar tendon from its cranial origin down to its distal insertion using long- and short-axis planes. Because the lower pole of the patella has a V-shaped appearance, one should be aware that the tendon inserts not only on the apex but also along the inferolateral and inferomedial edges of the bone. Short-axis US images over the proximal patellar tendon should be also performed because tendinopathy may occur out of the midline.

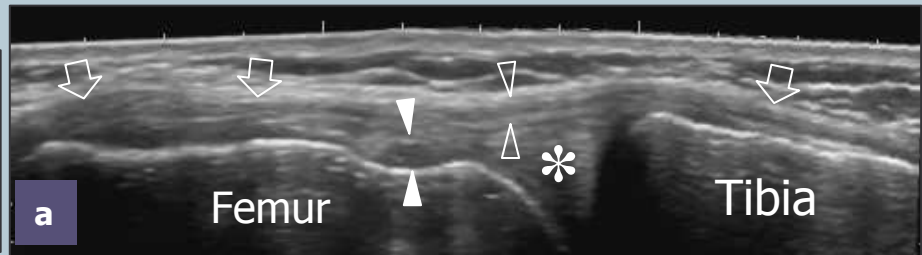
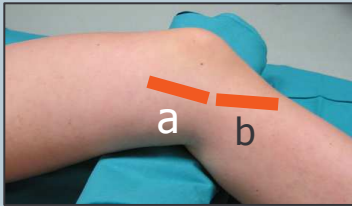


Legend: arrowheads, patellar tendon; arrow, deep infrapatellar bursa; Hfp, Hoffa pat; P, patella

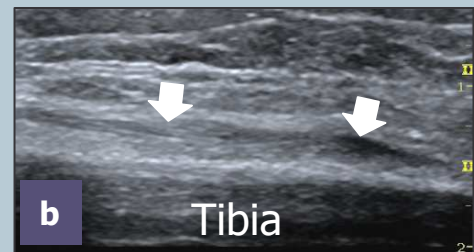
Deep to the patellar tendon, look at the intracapsular Hoffa fat pad and check the deep infrapatellar bursa between the distal patellar tendon and the anterior aspect of the tibial epiphysis. Mild distension of the bursa appears as a small triangular hypoechoic area and should be regarded as normal. Normally, the superficial infrapatellar bursa is not visible.

5 MEDIAL KNEE: medial collateral ligament and pes anserinus tendons

For examination of the medial knee, the patient is asked to rotate the leg externally while maintaining 20°-30° of knee flexion. Place the transducer obliquely-oriented over the long-axis of the medial collateral ligament. Care should be taken to examine the entire length of this ligament. Dynamic scanning during valgus stress can improve the assessment of its integrity. Check the soft-tissues immediately superficial to the base of the medial meniscus.



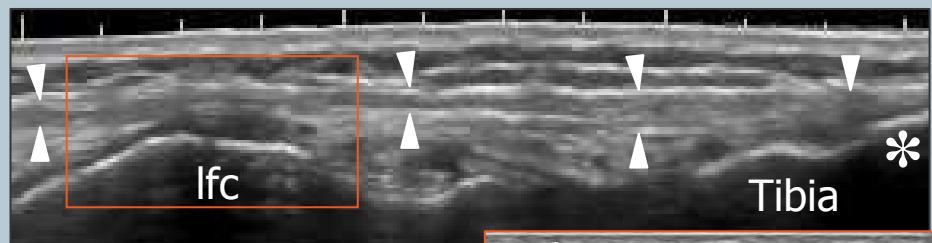
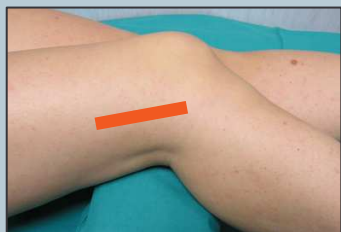Follow the profile of the medial collateral ligament distally and then rotate the transducer forward to image the tendons of the pes anserinus complex (sartorius, gracilis and semitendinosus) in their long-axis. These tendons are closely apposed and cannot be separated at the level of the insertion on the tibia (small convave area).



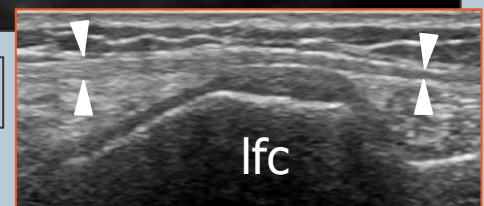Legend: void arrows, medial collateral ligament; asterisk, medial meniscus; void arrowheads, superficial portion of medial collateral ligament; white arrowheads, meniscofemoral ligament; white arrows, pes anserinus complex insertion

6 LATERAL KNEE: iliotibial band

For examination of the lateral knee, rotate the patient's leg internally while maintaining 20°-30° of knee flexion. Check the iliotibial band on its long-axis down to reach the Gerdy's tubercle. If doubts exist on whether the probe is correctly oriented, consider that the iliotibial band is located between the anterior and middle third of the lateral aspect of the knee and oriented along the major axis of the thigh. Check the soft-tissues immediately superficial to the base of the lateral meniscus: when a meniscal cyst is suspected, examine the knee in forceful flexion to produce bulging of the cyst outside the joint space thus improving its detection.

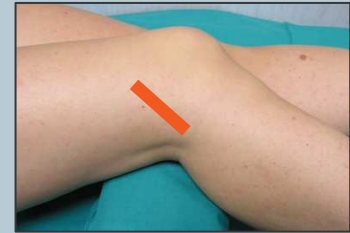
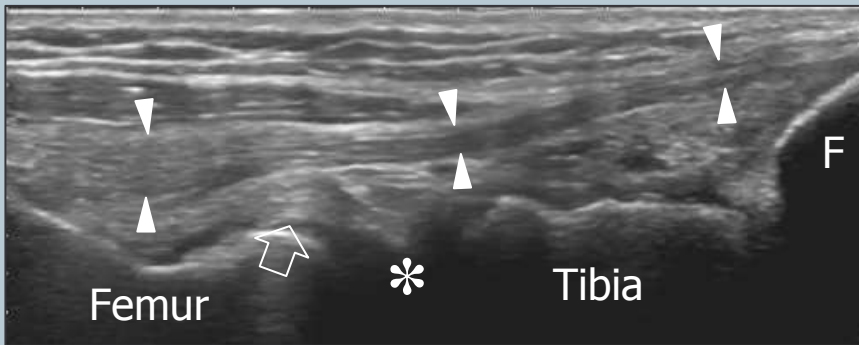


Legend: arrowheads, iliotibial band; asterisk, Gerdy's tubercle; lfc, lateral femoral condyle



7 lateral collateral ligament

With extended knee, place the lower edge of the probe on the peroneal head and then rotate its upper edge anteriorly until the lateral collateral ligament appears as more elongated as possible in the US image. Just deep to the proximal part of the lateral collateral ligament, the popliteal tendon can be imaged in its bony groove. Transverse US planes may help to assess the relationship of the lateral collateral ligament with the more posterior biceps femoris tendon.

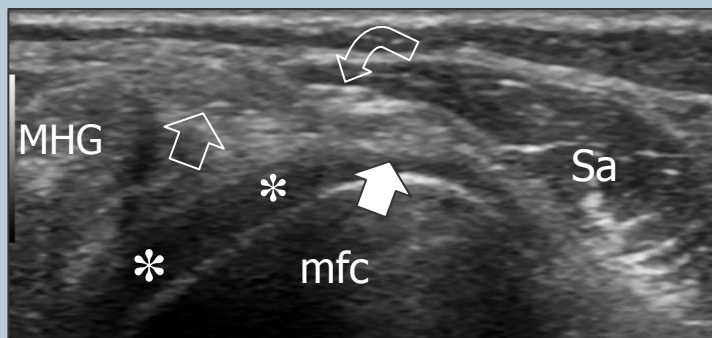
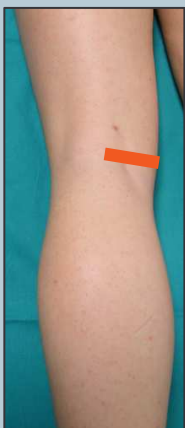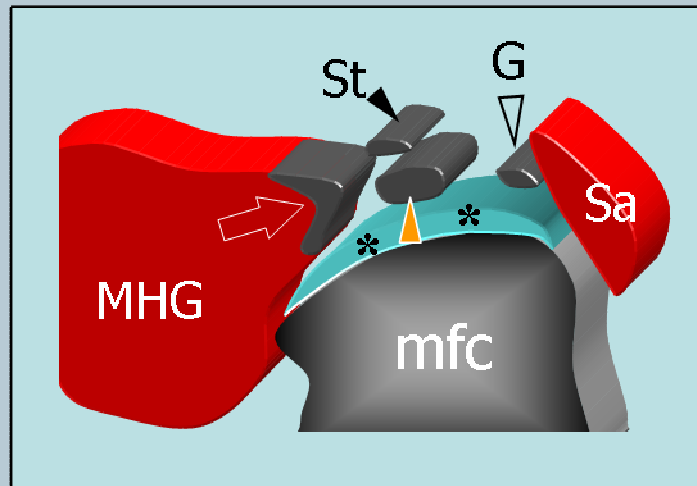


Legend: arrow, popliteal tendon; arrowheads, lateral collateral ligament; asterisk, lateral meniscus; F, fibular head

Check the superior tibiofibular joint for joint effusion and paraarticular ganglia by means of axial and coronal US images obtained over the anterior aspect of the fibular head.

8 POSTERIOR KNEE: medial tendons

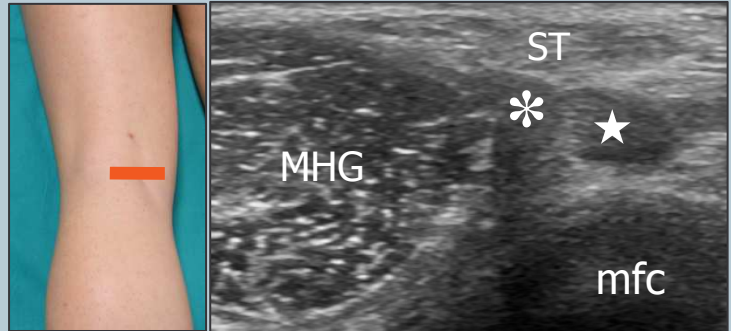
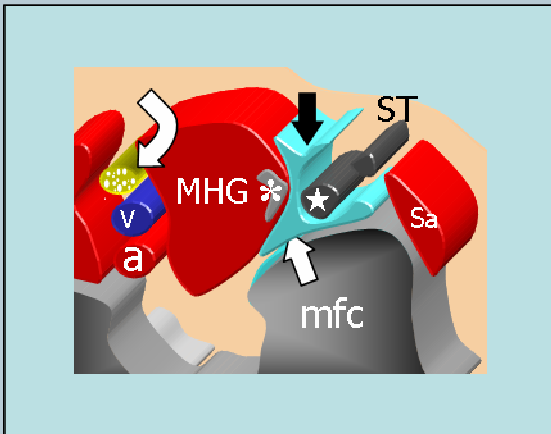
For examination of the posterior knee, the patient is asked to lie prone with the knee extended. Scanning the posteromedial knee on transverse planes demonstrates, from medial to lateral, the sartorius – made, at this level, of muscle fibers - the gracilis tendon and the semitendinosus tendon that is located behind the semimembranosus tendon.



Legend: asterisks, articular carilage of the medial femoral condyle; curved arrow, saphenous nerve; mfc, medial femoral condyle; MHG, medial head of gastrocnemius; Sa, sartorius muscle; void arrow, semitendinosus tendon; white arrow, gracilis tendon

9 semimembranosus-gastrocnemius bursa

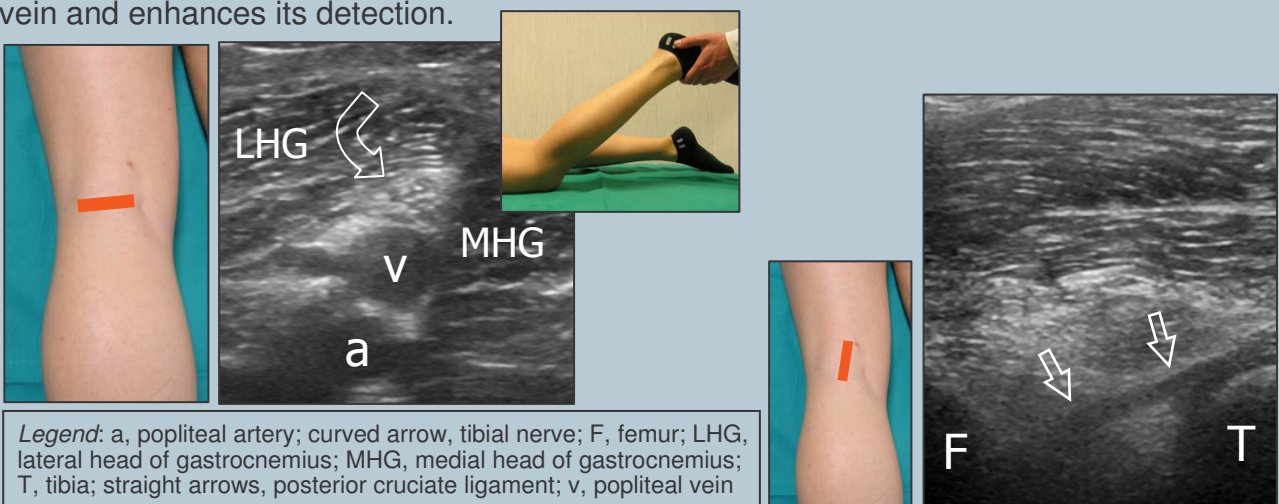
Check the semimembranosus-gastrocnemius bursa between the semimembranosus tendon medially and the medial head of the gastrocnemius laterally using axial planes and the cartilage of the posterior aspect of the medial femoral condyle using sagittal planes.



Legend: a, popliteal artery; asterisk, tendon of the medial head of gastrocnemius; curved arrow, tibial nerve; mfc, medial femoral condyle; MHG, medial head of gastrocnemius; star, semimembranosus tendon; Sa, sartorius muscle; ST, semitendinosus tendon; straight arrows, semimembranosus-gastrocnemius bursa; v, popliteal vein

10 popliteal neurovascular bundle and intercondylar fossa

In the popliteal fossa, sweep the probe up and down over the popliteal neurovascular bundle to demonstrate the popliteal artery (deep), the popliteal vein (intermediate) and the tibial nerve (superficial) which are aligned on an oblique sagittal plane. Because the patient is prone, the popliteal vein tends to collapse: a small elevation of the leg from the examination bed, which is obtained while flexing the knee, causes filling of the popliteal vein and enhances its detection.

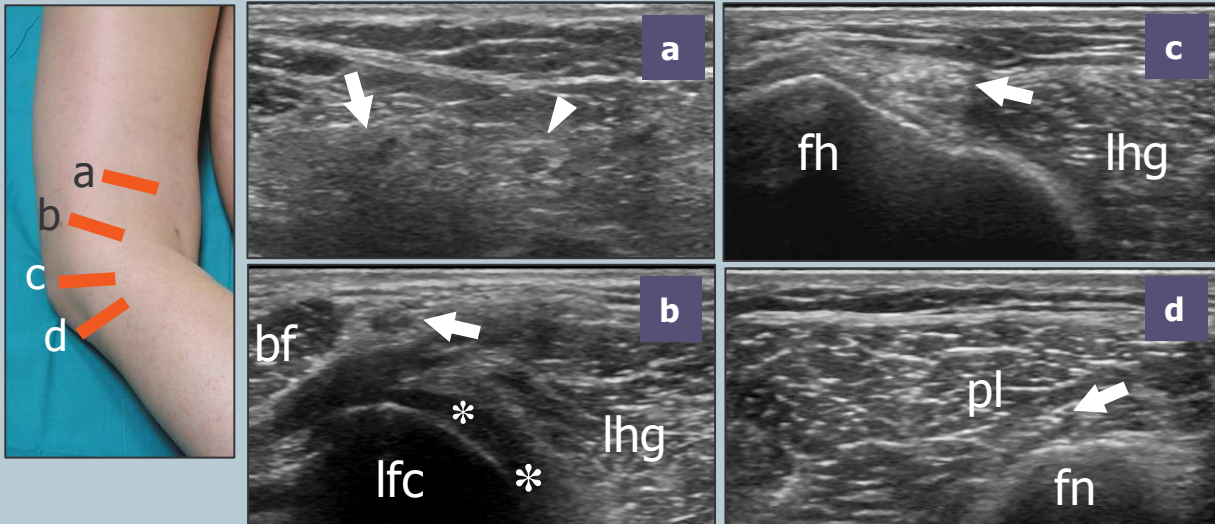


Legend: a, popliteal artery; curved arrow, tibial nerve; F, femur; LHG, lateral head of gastrocnemius; MHG, medial head of gastrocnemius; T, tibia; straight arrows, posterior cruciate ligament; v, popliteal vein

More deeply, in the intercondylar fossa, examine the mid-distal portion of the posterior cruciate ligament in its long-axis using oblique sagittal planes, with the proximal end of the probe rotated slightly medially in the direction of the medial femoral condyle. If an anterior cruciate ligament tear is suspected, check the lateral aspect of the intercondylar fossa for a hematoma (indirect sign).

11 peroneal nerve

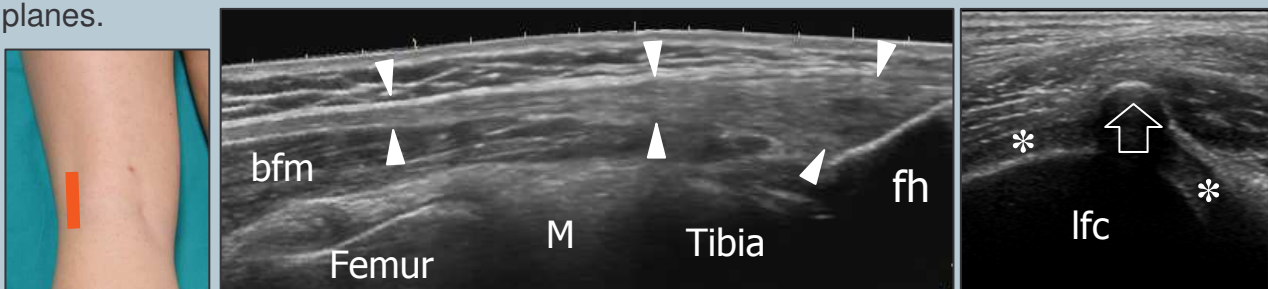
From the position described at point-12, shift the probe up over the tibial nerve up to find the origin of the common peroneal nerve from the sciatic nerve. Follow the common peroneal nerve in its short-axis throughout the lateral region of the popliteal space down to reach the fibular head and neck. The peroneal nerve is found posteriorly to the biceps femoris. Note the divisional (superficial and deep) branches of the peroneal nerve that wind the fibula passing deep to the peroneus longus attachment.



Legend: arrow, peroneal nerve; arrowhead, tibial nerve; asterisks, articular cartilage of lateral femoral condyle; bf, biceps femoris muscle; fh, fibular head; fn, fibular neck; lhg, lateral head of gastrocnemius; lfc, lateral femoral condyle; pl, peroneus longus muscle

12 posterolateral corner and biceps femoris

Moving to the posterolateral aspect of the knee, examine the biceps femoris muscle and tendon by means of long- and short-axis planes. Proximal images must include careful evaluation of the myotendinous junction of the two heads of the biceps femoris muscle because this is a common site of sport-related tears. The biceps femoris tendon can be followed straight downward from its origin to the fibular head. A small sesamoid - the fabella - can be occasionally seen in the tendon of the lateral head of the gastrocnemius. Check the cartilage of the posterior aspect of the lateral femoral condyle using sagittal planes.



Legend: arrow, fabella; arrowheads, biceps femoris tendon; asterisks, articular cartilage of lateral femoral condyle; bfm, biceps femoris muscle; M, lateral meniscus; fh, fibular head; lfc, lateral femoral condyle