

# US of Acute Scrotal Trauma: Optimal Technique, Imaging Findings, and Management<sup>1</sup>

## TEACHING POINTS

See last page

Corinne Deurdulian, MD • Carol A. Mittelstaedt, MD • Wui K. Chong, MD • Julia R. Fielding, MD

The primary causes of scrotal trauma are blunt, penetrating, degloving, and electrical burn injuries to scrotal contents. Knowledge of the scrotal anatomy and appropriate imaging techniques are key for accurate evaluation of scrotal injuries. Ultrasonography (US) is the first-line imaging modality to help guide therapy for scrotal trauma, except in degloving injury, which results in scrotal skin avulsion. Blunt injury (eg, from an athletic accident or motor vehicle collision) is the most common cause of scrotal trauma, followed by penetrating injury from gunshot or other assault. Trauma often may result in hematoma, hydrocele, hematocele, testicular fracture, or testicular rupture. The timely diagnosis of rupture, based on a US finding of discontinuity of the echogenic tunica albuginea, is critical because emergent surgery results in salvage of the testis in 80%–90% of rupture cases. The radiologist should be familiar also with other nuances associated with penetrating trauma, iatrogenic and postoperative complications, and electrical injury. Color flow and duplex Doppler imaging are highly useful techniques not only for assessing testicular viability and perfusion but also for evaluating associated vascular injuries such as pseudoaneurysms. A thorough familiarity with the US findings of scrotal trauma helps facilitate appropriate management. Supplemental material available at [radiographics.rsna.org/cgi/content/full/27/2/357/DC1](http://radiographics.rsna.org/cgi/content/full/27/2/357/DC1).

©RSNA, 2007

RadioGraphics 2007; 27:357–369 • Published online 10.1148/rg.272065117 • Content Codes: **ER** **GU** **US**

<sup>1</sup>From the Department of Imaging, W.G. “Bill” Hefner V.A. Medical Center, 1601 Brenner Ave, Salisbury, NC 28144 (C.D.); and Abdominal Imaging Section, Department of Radiology, University of North Carolina School of Medicine, Chapel Hill, NC (C.A.M., W.K.C., J.R.F.). Presented as an education exhibit at the 2005 RSNA Annual Meeting. Received June 7, 2006; revision requested June 30 and received September 14; accepted September 26. All authors have no financial relationships to disclose. Address correspondence to C.D. (e-mail: [drcorinne@hotmail.com](mailto:drcorinne@hotmail.com)).

©RSNA, 2007

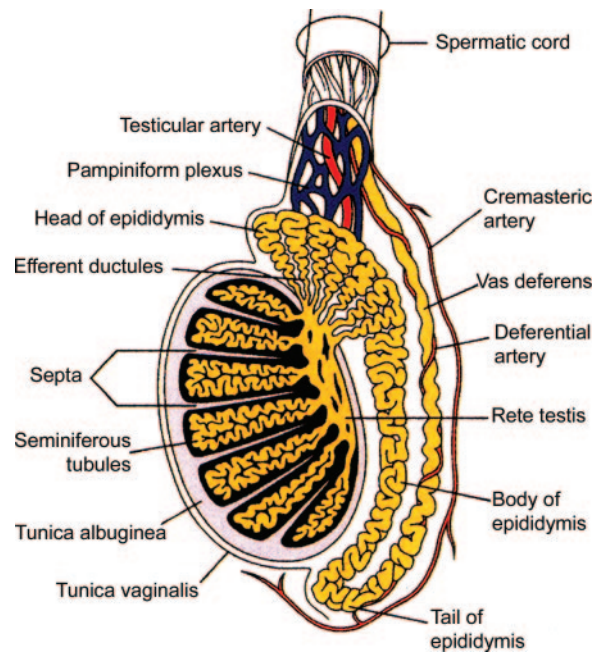
## Introduction

Scrotal trauma accounts for less than 1% of all trauma-related injuries, because of the anatomic location and mobility of the scrotum. The peak occurrence of scrotal trauma is in the age range of 10–30 years (1). **Mechanisms of trauma include blunt, penetrating, thermal (ie, burn), and degloving injuries.** Blunt trauma is the most commonly occurring form and usually results from athletic injury (about 50% of blunt trauma cases), motor vehicle collision (9%–17% of cases), or assault (2). Penetrating trauma is usually due to gunshot wounds and less commonly due to stab wounds, animal attacks, and self-mutilation. In degloving or avulsion injury, the scrotal skin shears off, and skin grafting may be required. Postsurgical and thermal injuries are rare. The right testis is injured more often than the left one because of its greater propensity to be trapped against the pubis or inner thigh (3,4). Patients with scrotal trauma usually present emergently, and rapid and accurate diagnosis is necessary to guide treatment and prevent loss of the testis. Delay in diagnosis or inaccurate diagnosis may result in decreased fertility, delayed orchiectomy, infection, ischemia or infarction, and atrophy (4–7).

Ultrasonography (US) is commonly performed for the assessment of scrotal abnormalities. It is ideal for the assessment of scrotal trauma, as it can be used for noninvasive evaluation of the scrotal contents, testicular integrity, and blood flow, as well as to visualize hematomas, other fluid collections, and foreign bodies. The objective of this article is to familiarize the reader with the scrotal anatomy and the US manifestations of testicular trauma, including hematomas, fractures, and ruptures, as well as with other nuances associated with postoperative complications, penetrating injury, electrical injury, and vascular injury. Emphasis is placed on findings that may necessitate immediate surgical intervention.

## Imaging Technique

The patient is positioned supine, and a rolled towel or sheet is placed between the legs to support the scrotum. The penis is displaced superiorly or superolaterally with a towel draped over it. Scanning is performed with a high-frequency (8–15-MHz) transducer in sequential sagittal and



**Figure 1.** Drawing shows the normal intrascrotal anatomy. (Reprinted, with permission, from reference 8.)

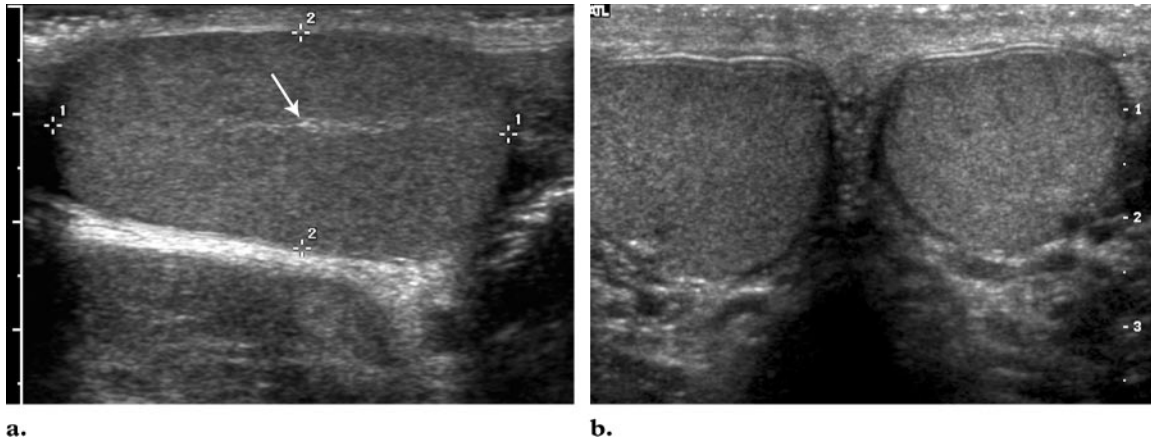
transverse planes with appropriate placement of the focal zone, depth, and gain settings. The use of a high-frequency transducer allows greater resolution of the scrotal contents. However, in cases of marked scrotal enlargement, a lower frequency transducer may be employed.

Scanning of both testes is performed in sagittal and transverse planes with size measurements. Transverse side-by-side images of both testes should be obtained for comparison of echotexture, skin thickness, and color Doppler flow pattern. The epididymis should be imaged on the long and short axes. Color and power Doppler imaging are used to detect flow within the scrotal structures and to confirm symmetric or abnormal flow patterns.

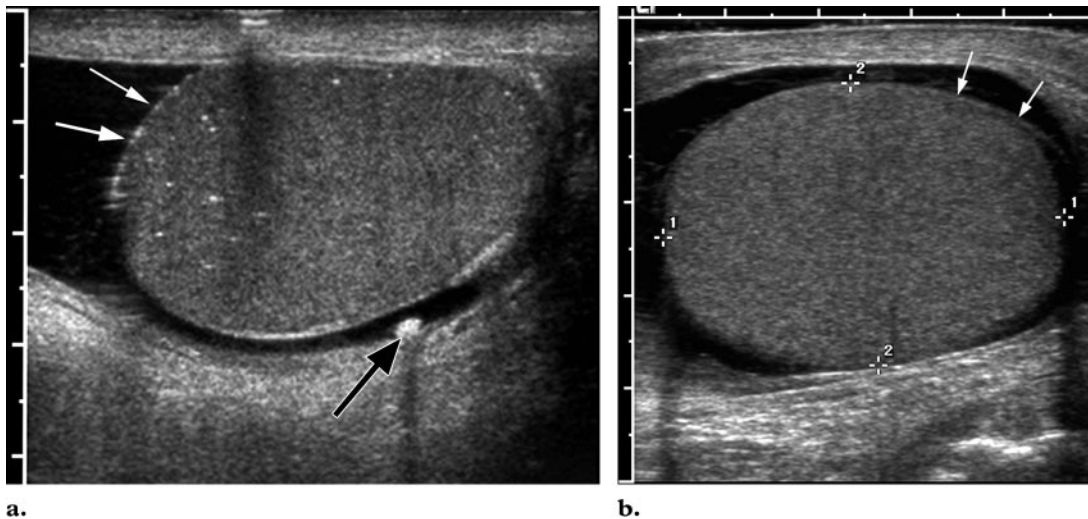
## Normal Anatomy

The scrotal sac, beneath the scrotal skin, comprises many layers that are not readily visible at US, including the superficial (dartos) fascia, external spermatic fascia, cremaster muscle and fascia, internal spermatic fascia, and tunica vaginalis (Fig 1). Consisting of parietal and visceral layers, the tunica vaginalis contains a potential space where hydroceles or other fluid collections may develop (2,8). The testis is an ovoid structure surrounded by the tunica albuginea and contains

Teaching  
Point



**Figure 2.** Normal anatomy. Gray-scale US images of normal testes in sagittal (**a**) and transverse (**b**) planes demonstrate a uniformly gray echotexture. In **b**, both testes have the same echotexture. The mediastinum of the testis (arrow) is depicted in **a** as a horizontal echogenic band.

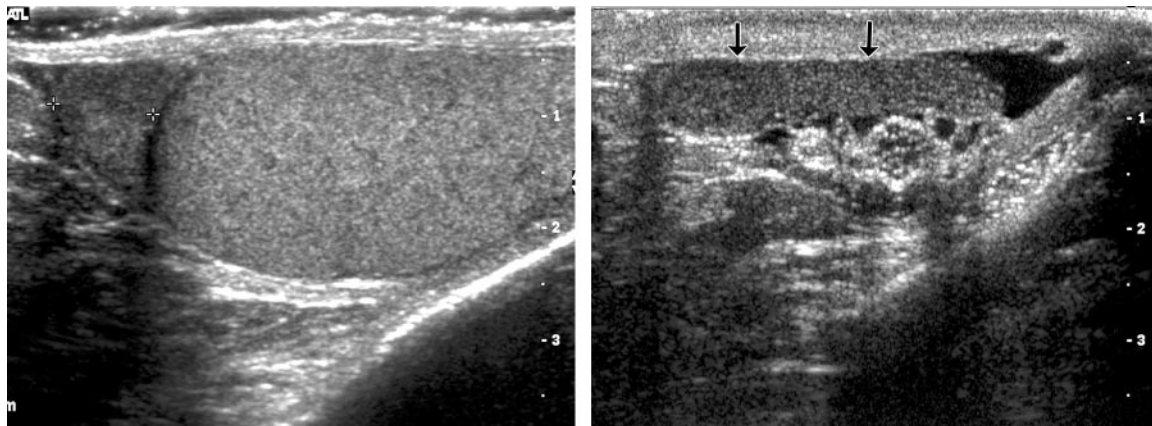


**Figure 3.** Tunica albuginea. Sagittal US images of the testes in two different patients with hydroceles show the tunica albuginea as an echogenic line (white arrows) that outlines the testis. In **a**, small punctate echogenic foci are visible within the testis, findings consistent with microlithiasis. A scrotal pearl (black arrow) also is depicted.

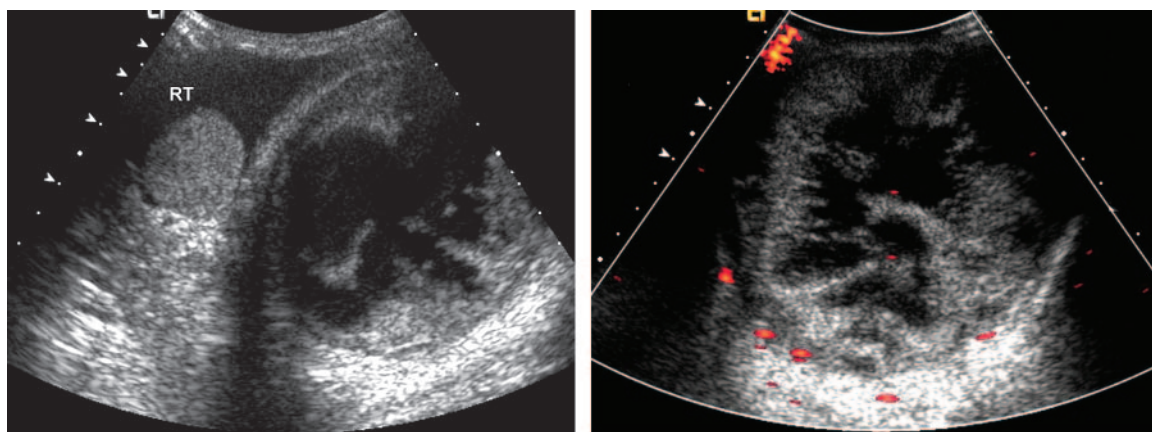
seminiferous tubules, which converge to form the rete testis in the mediastinum. The rete testis drains into the efferent ductules, which drain into the tubules that form the epididymal head. The epididymal head is found along the superior pole of the testis, and its body and tail extend inferolaterally. The epididymal tail continues as the vas deferens in the spermatic cord (2,9).

The testis has medium homogeneous echogenicity with a length of 3–5 cm, width of 2–4 cm, and an anteroposterior dimension of approximately 3 cm (Fig 2). The mediastinum of the testis appears as an echogenic band that extends

along the long axis of the testis (Fig 2a). The tunica albuginea is not normally visible at US unless there is fluid surrounding the testis. In such cases, the tunica can be seen as an echogenic line surrounding the testis (Fig 3). A curved structure with a length of 6–7 cm, the epididymis appears isoechoic or hypoechoic when compared with the testis (Fig 4). The head of the epididymis is approximately 10–12 mm in anteroposterior dimension (Fig 4a). The body has an average thickness



**Figure 4.** Normal epididymis. Sagittal US images depict a normal epididymal head (area between the cursors in **a**) and body with tail (arrows in **b**). The echotexture of the epididymis is similar to that of the testis. The view of the body and tail was obtained by scanning in a coronal plane.



**Figure 5.** Intratesticular hematoma in a patient with continued scrotal swelling 1 year after blunt trauma. **(a)** Transverse US image of the scrotum demonstrates a normal-sized right testis (*RT*) surrounded by fluid, with a large complex cystic mass in place of the left testis. **(b)** Transverse view obtained with power Doppler imaging in the region of the left testis shows a complex fluid-filled mass with dimensions of  $12.1 \times 11.2$  cm and with multiple septa. No normal parenchyma is identifiable in the left testis, and there is no visible flow, findings indicative of replacement of the entire testis by a hematoma.

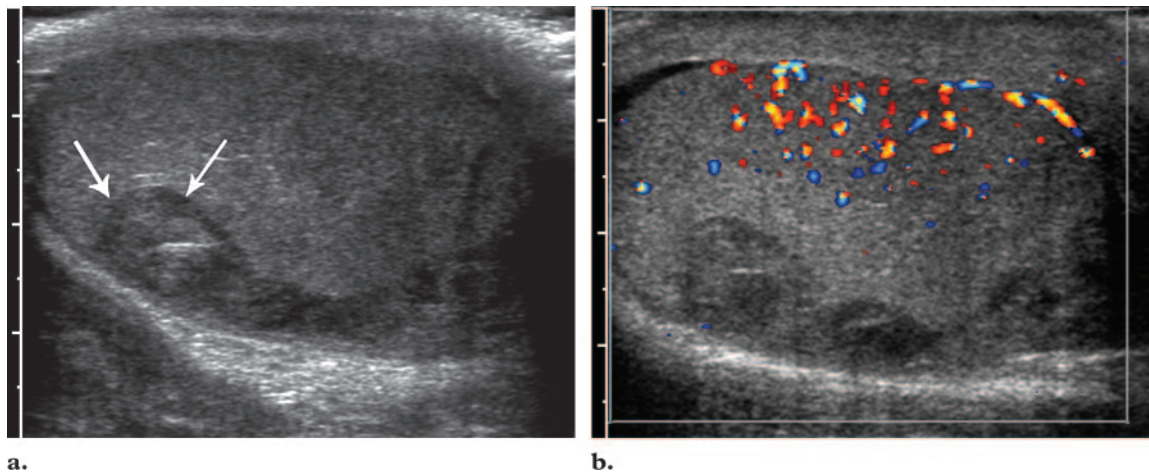
of 1–2 mm (normal thickness, <4 mm) and is best depicted with coronal scanning of the scrotum (Fig 4b) (9).

### Clinical and US Assessment

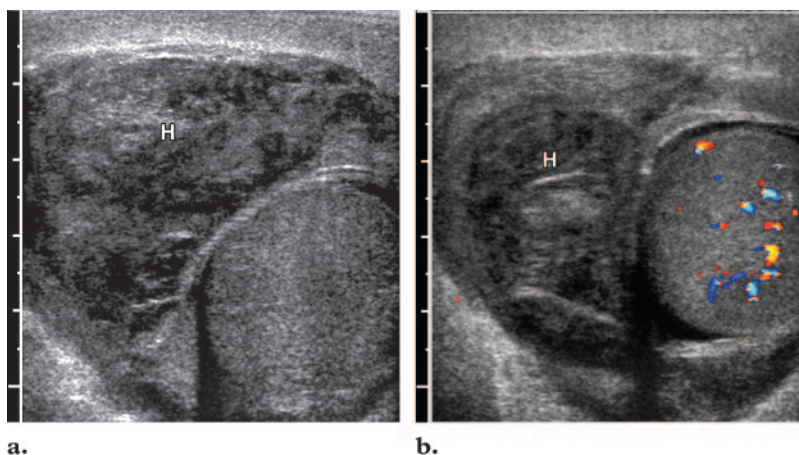
When a patient presents with scrotal trauma, a clinical assessment is made for acute scrotal pain, swelling, and bruising. The overlying skin is examined to determine the extent of its integrity and for sites of any entry and exit wounds. The

testis and epididymis also are palpated, and a penile examination is performed by the clinician. After any necessary wound cultures, urinalysis, and urine cultures are performed, the patient undergoes imaging with US unless there is scrotal avulsion (3).

US is the first-line imaging test for scrotal trauma, and US findings are crucial in clinical decision making (4–6,10). US manifestations include fluid collections, testicular disruption, and vascular injury. A hydrocele, or fluid between the two layers of the tunica vaginalis, may hinder



**Figure 6.** Intra-testicular hematoma. **(a)** Sagittal gray-scale US image shows an ill-defined hypoechoic area (arrows) that represents a hematoma in the posterior part of the left testis. **(b)** Sagittal color Doppler image shows flow in the testis, except in the area of hematoma, where there is a testicular fracture.



**Figure 7.** Extratesticular hematoma in a patient with scrotal swelling after a right inguinal hernia repair. Transverse US images demonstrate a large hypoechoic region ( $8.6 \times 3.8 \times 4.7$  cm) within the right-sided scrotal wall on the gray-scale image **(a)** and no internal flow on the color Doppler image **(b)**, findings that are indicative of an extratesticular hematoma (*H*). The right testis in **b** appears to have normal internal flow.

the clinical examination but aid US by providing an acoustic window. Management of testicular trauma depends on testicular integrity and perfusion. If the testis is ruptured, emergent surgery can salvage the testis in 80%–90% of cases (5,7,11). The surgical approach varies with the type of trauma.

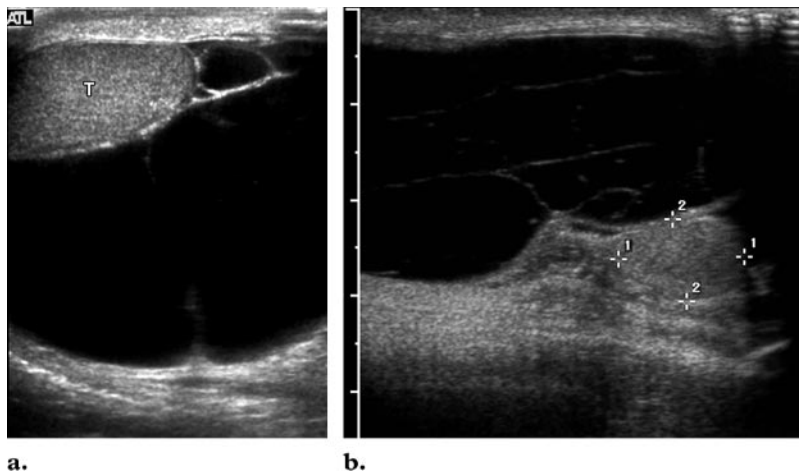
## Blunt Scrotal Trauma

### Fluid Collections

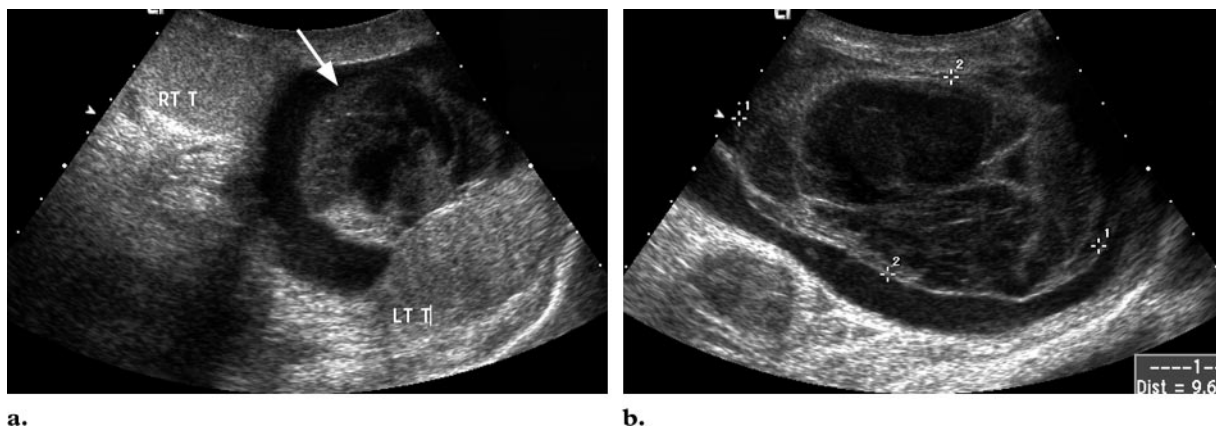
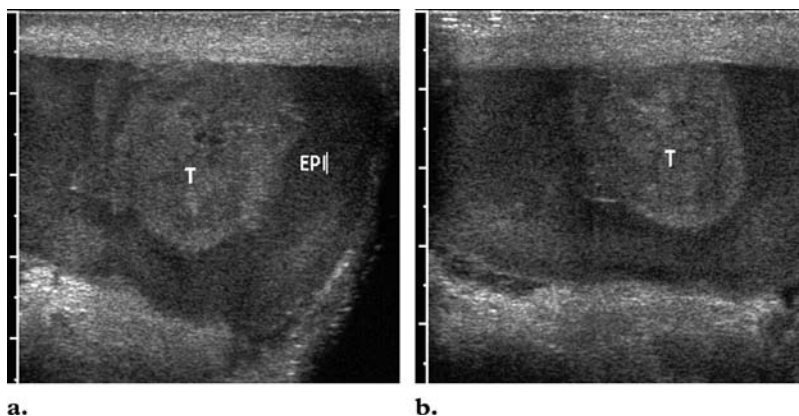
**Hematomas.**—Hematomas may occur in intra-testicular locations (Figs 5, 6; see also Movie 1 at [radiographics.rsna.org/cgi/content/full/27/2/357](http://radiographics.rsna.org/cgi/content/full/27/2/357)

/DC1) or in extratesticular soft tissues such as the scrotal wall or epididymis. The lesions are usually focal, may be multiple, and may be hyperechoic (in acute bleeding) or hypoechoic (as the hemorrhage ages) and lack vascularity (Fig 6; see also Movie 1). The fluid in a complex hematoma may be heterogeneous. Hematomas of the scrotal wall may appear as focal thickening of the wall or as fluid collections within the wall (Fig 7; see also Movie 2 at [radiographics.rsna.org/cgi/content/full/27/2/357/DC1](http://radiographics.rsna.org/cgi/content/full/27/2/357/DC1)).

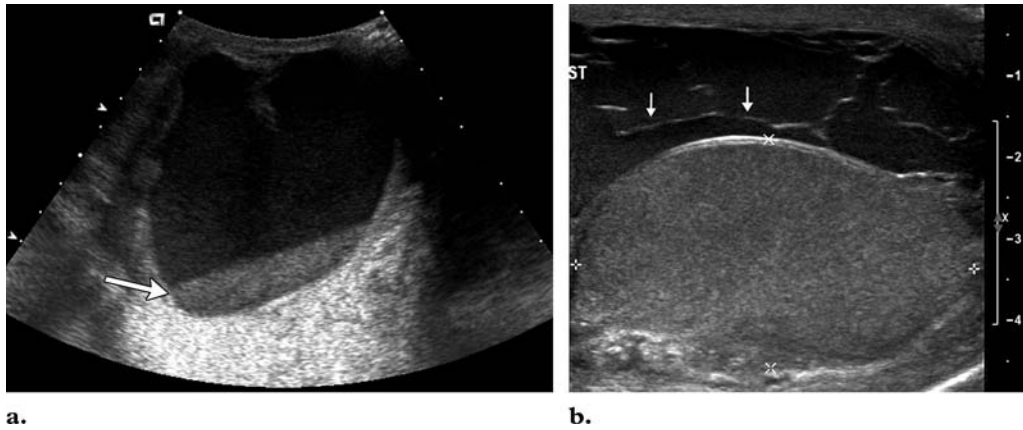
**Figure 8.** Hydroceles in two patients. **(a)** Transverse US image of the left scrotum shows a large hydrocele that has displaced the testis (*T*) anteriorly. **(b)** Sagittal image shows a very large right-sided hydrocele that contains fine internal septa, with the right testis (area demarcated by cursors) displaced posteriorly.



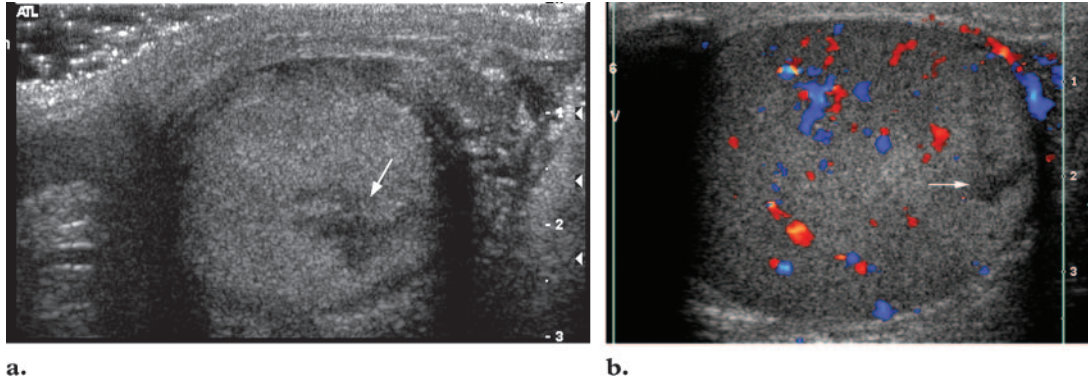
**Figure 9.** Hematocele due to testicular rupture immediately after blunt scrotal trauma. Transverse US images (**b** slightly superior to **a**) show uniformly echogenic fluid surrounding the testis (*T*), a finding indicative of blood in a hematocele. *EPI* = epididymis.



**Figure 10.** Older hematocele. Sagittal US images obtained approximately 1 week **(a)** and 6 weeks **(b)** after trauma show uniform echotexture and internal flow in both testes, but with differences in the echotexture of the hematoma. A complex cystic mass (arrow in **a**) anterior to the left testis represents a hematoma with a hematocele. The mass demarcated by cursors in **b** had a more complex and more masslike appearance that was believed to be due to a clot. At surgery after 6-week follow-up US, a large amount of fluid and an old clot were found with an intact testis. *LT T* = left testis, *RT T* = right testis.



**Figure 11.** Postoperative hematocele. **(a)** Transverse US image obtained 2 months after surgical repair of a large right inguinal hernia demonstrates complex layering of fluid (arrow) in the right scrotal sac, a finding consistent with a hematocele. **(b)** Sagittal US image obtained after a right inguinal hernia repair in another patient shows a septate fluid collection with fine echoes (arrows) anterior to the testis (area between the cursors). At Doppler imaging in both patients, flow in the testis was normal.



**Figure 12.** Testicular fracture. **(a)** Transverse US image of the testis shows a hypoechoic irregular linear area (arrow) indicative of a fracture. **(b)** Transverse color Doppler image depicts normal flow throughout the testis, except in the area of the fracture (arrow).

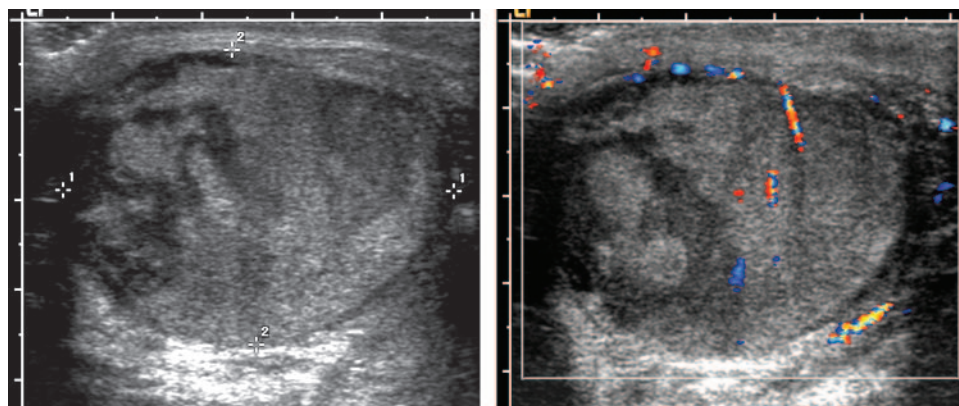
**Hydroceles.**—Hydroceles are predominantly anechoic fluid collections that occur in the potential space between the two layers of the tunica vaginalis (Figs 1, 3, 8). Up to 50% of acquired hydroceles are due to trauma (12), and hydroceles may occur in up to 25% of patients with major trauma (13). Rupture of the bulbous urethra may result in extravasation of urine into the scrotum, which may mimic a hydrocele.

**Hematoceles.**—Similar to hydroceles, hematoceles are complex collections that separate the visceral and parietal layers of the tunica vaginalis. Like hematomas, they are acutely echogenic and become more complex and more hypoechoic with age (Figs 9, 10; see also Movie 3 at [radiographics](#)

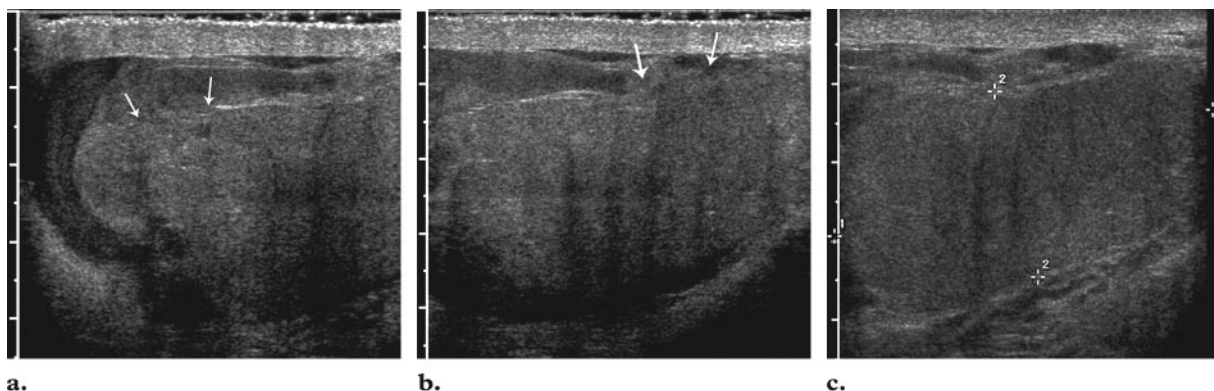
[.rsnajmls.org/cgi/content/full/27/2/357/DC1](#)) (14). Subacute and chronic hematoceles may contain fluid-fluid levels or low-level internal echoes (Fig 11) (2).

### Testicular Injuries

**Fracture.**—A testicular fracture appears as a linear hypoechoic band that extends across the testicular parenchyma and represents a break in the normal testicular architecture (Figs 12, 13). The overall contour remains smooth, as the testicular shape and the tunica albuginea are maintained.



**Figure 13.** Testicular fractures and intratesticular hematomas. **(a)** Sagittal gray-scale image of the right testis shows a markedly heterogeneous testis with ill-defined hypoechoic areas that represent intratesticular blood. No peritesticular fluid is visible, and the tunica albuginea appears intact. Because of the extensive hematomas, the specific fracture site is not identifiable. **(b)** Color Doppler image shows appropriate flow within the traumatized testis.



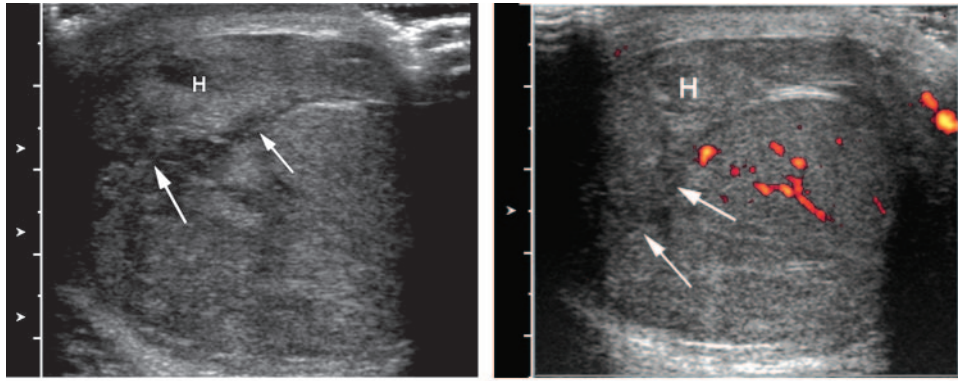
**Figure 14.** Ruptured testis with hematocele (same patient as in Fig 9). **(a-c)** Sagittal gray-scale US images of the left testis demonstrate an oblong testis with a heterogeneous echotexture and very irregular outline, with two areas of discontinuity in the tunica albuginea, a defect in the superior pole of the testis (arrows in **a**), and a defect in the middle part of the testis (arrows in **b**). The echogenic fluid surrounding the testis is consistent with a hematocele. **(d)** Sagittal color Doppler image shows flow within the testis. At surgery, the tunica albuginea was found to have ruptured in two places.

An associated hematocele or testicular hematoma may be seen (Figs 6, 9; see also Movie 1). Doppler imaging is used to determine vascular integrity. Testicular fractures are treated conservatively if normal flow is identified. If flow is absent, emergent surgery is indicated, as this finding represents ischemia (14,15).

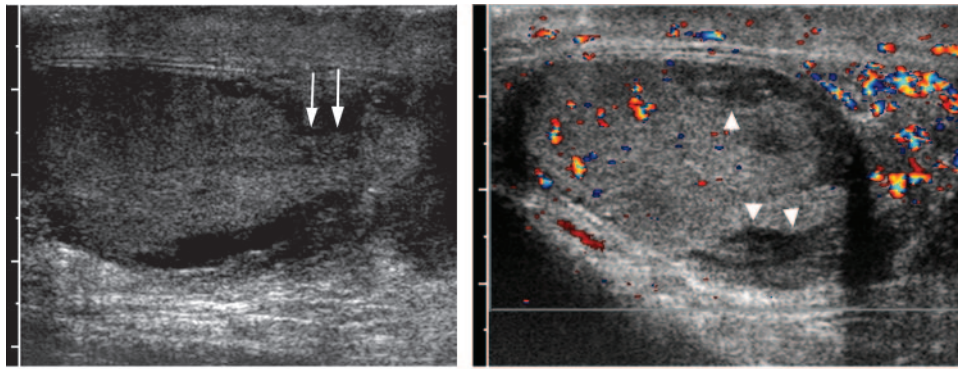
**Rupture.**—In testicular rupture, there is hemorrhage and extrusion of testicular contents into the scrotal sac (Figs 14–17; see also Movies 4–6 at [radiographics.rsna.org/cgi/content/full/27/2/357/DC1](http://radiographics.rsna.org/cgi/content/full/27/2/357/DC1)) (14). **Discontinuity of the echogenic tunica albuginea is indicative of testicular rupture and necessitates emergent surgery.** In this type of in-

jury, US images also demonstrate poorly defined testicular margins and heterogeneous echotexture, with focal hyperechoic or hypoechoic areas in the testicular parenchyma corresponding to areas of hemorrhage or infarction (Figs 14–17; see also Movies 4–6) (10,13,16). Associated findings may include scrotal wall thickening and hematocele. Color and duplex Doppler images may show decreased flow or no flow. Buckley and McAninch reported that the single imaging finding of heterogeneous echogenicity of the testicular parenchyma with loss of contour definition had a

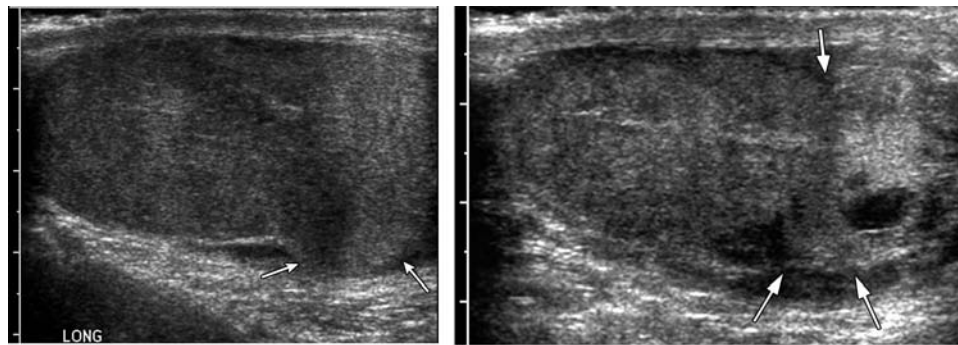




**a.** **b.**  
**Figure 15.** Ruptured testis with hematoma due to a fall onto a pole. **(a)** Transverse US image of the left testis shows a heterogeneous echotexture with internal cystic areas that represent hematomas, discontinuity (arrows) in the tunica albuginea, and an extratesticular hematoma (*H*). **(b)** Power Doppler image shows no flow in the extratesticular hematoma (*H*), decreased flow within the testis, and discontinuity (arrows) in the tunica albuginea.

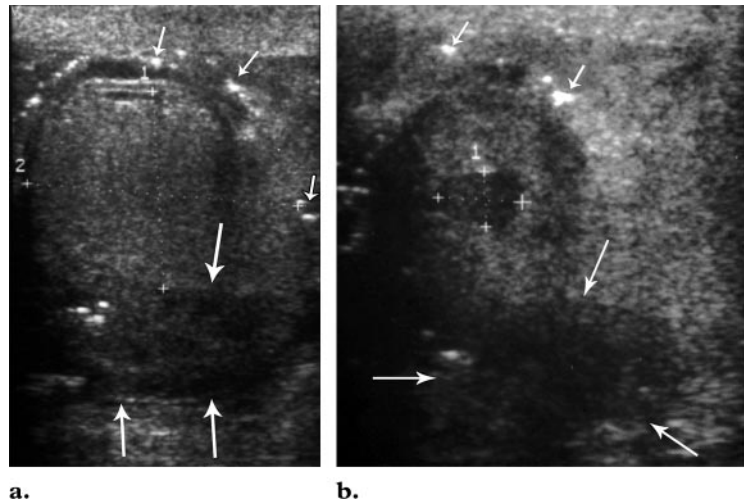


**a.** **b.**  
**Figure 16.** Testicular rupture. **(a)** Sagittal gray-scale US image demonstrates extrusion of the testicular contents (arrows) through the tunica albuginea. **(b)** Color Doppler image shows multiple hypoechoic foci with no flow (arrowheads) in the periphery of the testis, findings indicative of hematomas or infarcts. At surgery, extrusion of more than 50% of the testicular contents through the tunica albuginea was found.



**a.** **b.**  
**Figure 17.** Testicular rupture in a patient with groin pain and swelling after an athletic injury (knee to the right side of the groin). Sagittal US images show the right testis with an abnormal contour and somewhat bilobed shape (arrows); hypoechoic and anechoic areas within the inferior pole of the testis, especially visible in **b**; and irregularity of the tunica albuginea (arrows), which is best depicted in the video clip ([Movie 6 radiographics.rsna.org/cgi/content/full/27/2/357/DC1](http://www.radiographics.rsna.org/cgi/content/full/27/2/357/DC1)). The area of heterogeneous tissue at the inferior pole of the testis (arrows in **a**) is believed to represent extruded testicular contents. On color Doppler images (not shown), blood flow was seen in the superior to middle parts of the testis but not in the inferior part. At surgery, the nonviable-appearing parenchyma that extruded through the tunica albuginea was removed and the rupture was repaired.

**Figure 18.** Penetrating trauma. Transverse US images obtained in a patient with a gunshot wound to the scrotum show tiny hyperechoic foci (small arrows in **a**) that represent air and buckshot, with a focal hypoechoic area (demarcated by cursors in **b**) that represents intratesticular hematoma. Accumulated blood (large arrows) is depicted posterior to the testis, within the scrotal sac. The testis, which is demarcated by cursors in **a**, is difficult to define in **b** because of the surrounding blood and damage to the testis. Soft-tissue thickening of the scrotal wall also is visible.



sensitivity of 100% and a specificity of 93.5% for the diagnosis of rupture in a series of 65 patients with blunt scrotal trauma (5). However, the reported accuracy of the US-based diagnoses of rupture varies in the literature from 56% to 94% (16).

### Unusual Complications and Findings

Scrotal trauma may be associated with acute epididymitis, epididymo-orchitis, and torsion. It also has been reported that 10%–15% of testicular tumors are found incidentally at imaging after an episode of scrotal injury (16).

### Management

The injury is managed conservatively if the tunica albuginea appears intact on US images. Immediate exploration is warranted if the tunica is violated (indicating rupture), if there is nonperfusion of the testis, or if the US findings are equivocal and there is a high clinical suspicion of rupture (4). It may be difficult to identify the fracture plane through the testis. In a series of scrotal trauma cases evaluated by Jeffrey et al, the fracture plane or fragmentation of the testis was seen in only 17% of rupture cases (10). It also may be difficult to differentiate hematoma from extruded testicular contents (Fig 17; see also Movie 6) (14,17). The tunica albuginea may be hard to delineate, and subtle disruption therefore may be difficult to identify (Fig 17; see also Movie 6) (9). If the US findings are equivocal, the method of management will be determined on the basis of the clinical findings, history, and level of suspicion (4).

It is generally agreed that early intervention is very important in order to improve testicular salvage rates (5,11,17). Surgical delay may decrease the salvage rate from 80%–90% to 45%–55% (10,12) and may necessitate orchiectomy (9). Surgery includes débridement and primary closure of the tunica albuginea (5). **Potential complications of delayed diagnosis include testicular ischemic necrosis, abscess, and loss of spermatogenesis (14).** Testicular atrophy is a rare late sequela of rupture but does not require additional treatment. It is postulated that trauma-related atrophy is due to ischemia and resorption of nonviable testicular tissue, which result from increased pressure within the tunica secondary to hematoma formation (6).

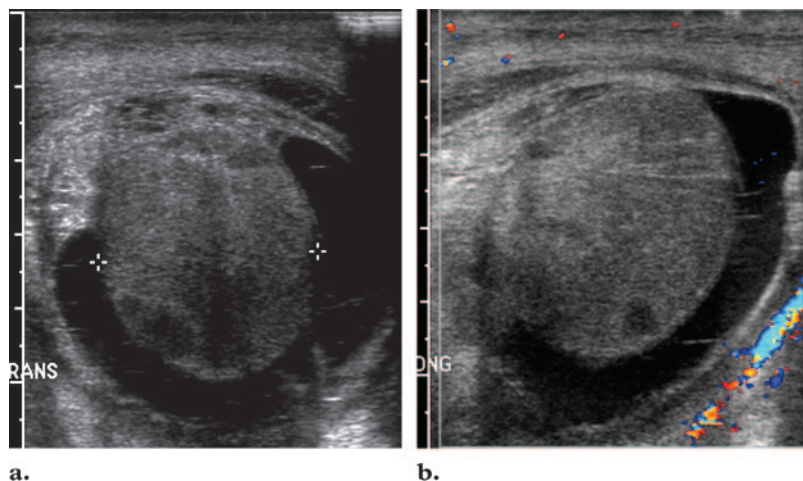
Teaching Point

### Penetrating Injury

Gunshot is the most common cause of penetrating testicular and scrotal trauma. Other less common causes include stabbing, self-mutilation, and emasculation (18). US is capable of depicting bullet fragments and other foreign bodies from penetrating injury (Fig 18), as well as other abnormalities that also may be seen after blunt trauma. It also is useful for identifying vascular injury, such as transection of the spermatic cord, which may result in testicular ischemia.

### US Findings

In a study by Learch et al, of 19 patients with gunshot wounds to the scrotum, eight had isolated hematoceles, hydroceles, or hematomas that were managed conservatively (19). Testicular rupture was diagnosed at US in six patients, although a fracture plane was seen in only two of the six. Five of the six underwent surgical explo-



**Figure 19.** Testicular ischemia in a patient with scrotal pain and swelling after open surgical repair of a hernia. **(a)** Transverse US image shows a heterogeneous hypoechoic testis that is surrounded by a complex hydrocele. **(b)** Color Doppler image demonstrates no intratesticular flow. The mesh that was used to repair the hernia had obstructed the venous return and caused ischemia. After the mesh was released around the spermatic cord, the testicular flow improved. At follow-up US, increased flow was seen in the left testis.

ration (the sixth patient did not undergo the procedure because of delayed presentation), and the presence of a rupture was confirmed in four of the five patients. Although tunical disruption was found in the fifth patient at surgery, the testis was intact. US also enabled the identification of foreign bodies in the testis and extratesticular soft tissues and hypoechoic tracks from missiles in the epididymis (Fig 18) (19).

In a study by Cline et al, surgery was performed because of imaging and clinical evidence of deep scrotal injury in 29 of 30 patients with gunshot wounds and stab wounds (20). The most common injury was a unilateral fractured testis, followed by transection of the spermatic cord and bilateral testicular injuries. The overall salvage rate among 23 injured testes was 35% (20).

### Management

**Testicular fractures and ruptures from penetrating injury are managed in the same way as are fractures and ruptures from blunt injury. In patients with complete vascular transection, immediate surgical exploration with microvascular reanastomosis is required (3).** Low-velocity missiles and stab wounds usually require exploration above and below any injured sites, often with a combined inguinal and scrotal approach. High-velocity missile injury is associated with a higher rate of vascular thrombosis and tissue loss, and the prognosis is guarded (3). It is also important to look for injury to the contralateral testis, extratesticular tissues, and penis, as penetrating trauma usually causes injury to more than one location. Injuries to the epididymis may be difficult to diagnose because it is small and easily obscured by hematoma. However, such injuries are usually managed conservatively, unless there is resultant infertility (19).

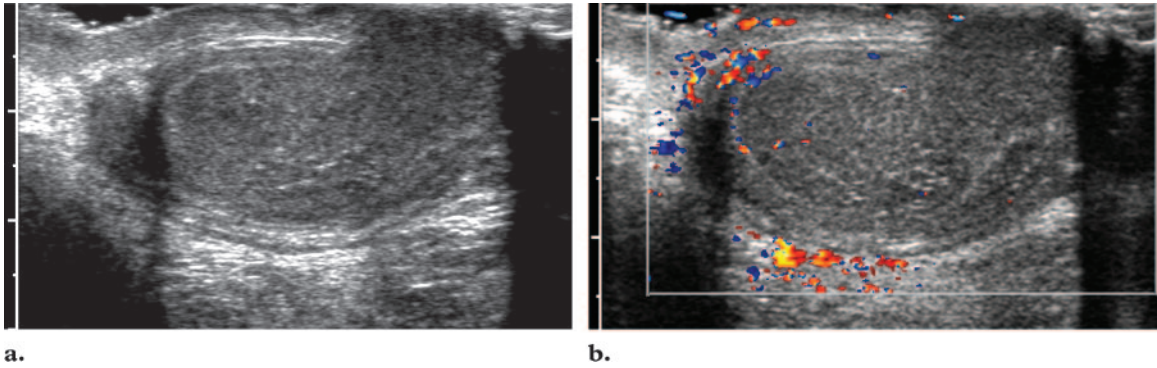
## Iatrogenic or Postoperative Injuries

### Mechanisms of Injury

Inguinal herniorrhaphy is a commonly performed operation that may result in complications, most frequently pain and nerve damage (21). Wound infection at the surgical site and of the mesh has been reported to range from 5% to 7% (22). Injury to the testis and scrotal sac is rare. The two primary mechanisms involved in genital tract injury are transection of the spermatic cord (usually recognized and immediately repaired during surgery) and cord compression with resultant ischemia (due to intraoperative handling of the vas, excessively tight placement of the mesh arms around the spermatic cord, or mesh-induced delayed fibrosis) (21). Compression injury usually manifests after a delay, unless nerve injury with resultant pain, or vascular injury to the gonads, is present. Delayed injury may be manifested by infertility, especially in cases of bilateral hernia repair and repair in children.

### US Findings

US is most helpful for detecting injuries to the testis or scrotal sac such as ischemia, infarction, hematoma, hydrocele, hemocele, and infection (Figs 7, 11, 19; see also Movie 2). Dattola et al found that US is much more sensitive (86%) than clinical examination (36%) for detecting postoperative complications (23). Ischemic orchitis occurs in 0.6% of patients who undergo an open surgical repair for a hernia (Fig 19), versus 0.08% of those who undergo a laparoscopic repair,



**Figure 20.** Scrotal electrical burn injury. **(a)** Sagittal gray-scale image demonstrates a hypoechoic left testis. **(b)** Sagittal color Doppler image shows no flow within the left testis, a finding suggestive of infarction. On other color Doppler images (not shown), the right testis had a similar appearance. Image resolution at US was somewhat limited because of burn damage to the skin. At surgery, diffuse parenchymal coagulative necrosis, subcutaneous fat necrosis, and acute inflammation were found.

according to the results of two studies (21). Iatrogenic testicular atrophy is rare, and its significance is uncertain, as the degree of atrophy is usually minimal (24). Atrophy also is more likely to be associated with open rather than laparoscopic repair (6).

### Electrical Injury

Electrical injuries occur in a spectrum that ranges in severity from low-voltage to high-voltage burns. Greater thermal injury results from high-voltage currents because of the resultant higher temperatures (25). Two types of high-voltage electrical burns may occur with exposure to a current of more than 1000 V: “flash” and “true” burns. Flash burns are usually more limited and may cause either full- or partial-thickness burns. Vascular injury may be secondary to vasospasm or damage to the endothelium and may lead to thrombosis, hemorrhage, and infarction. **A true electrical burn results from the passage of an electric current through the body, between points of entry and exit (26). Gray-scale US images of the scrotum in such cases may demonstrate infarction of the testis, and Doppler images may show no flow in one or both testes (Fig 20).**

#### Teaching Point

In a series of 70 patients with burns from a high-voltage electric current, Escudero-Nafs et al reported that the most common entry sites were the upper extremities and the most common exit sites were the lower extremities. The scrotum accounted for none of the entry sites and three of the exit sites (26). Imaging findings were not described.

### Vascular Injury

Intratesticular pseudoaneurysm, a rare vascular complication of blunt trauma, may be manifested on gray-scale images as a round hypoechoic or anechoic focus in the testis. On color Doppler images, the mass contains variably turbulent flow with a vascular neck. Flow enters the pseudoaneurysm in systole and exits in diastole, producing a to-and-fro pattern. If the tunica albuginea is intact, the pseudoaneurysm can be managed conservatively and monitored until thrombosis occurs (27).

### Conclusions

US is the first-line imaging test for evaluation of scrotal trauma and plays a critical role in decision

making about injury management. An understanding of US techniques, scrotal anatomy, and mechanisms of injury allows the sonographer to distinguish conditions that require immediate surgical exploration (eg, rupture) from those that can be managed conservatively. Determining vascular integrity is particularly important in the presence of penetrating trauma and electrical burns.

## References

- Munter DW, Faleski EJ. Blunt scrotal trauma: emergency department evaluation and management. *Am J Emerg Med* 1989;7(2):227–234.
- Dogra VS, Gottlieb RH, Oka M, Rubens DJ. Sonography of the scrotum. *Radiology* 2003;227:18–36.
- Mevorach RA. Scrotal trauma. WebMD Web site. <http://www.emedicine.com/med/topic2857.htm>. Published April 15, 2002. Accessed August 21, 2006.
- Mulhall JP, Gabram SG, Jacobs LM. Emergency management of blunt testicular trauma. *Acad Emerg Med* 1995;2(7):639–643.
- Buckley JC, McAninch JW. Use of ultrasonography for the diagnosis of testicular injuries in blunt scrotal trauma. *J Urol* 2006;175(1):175–178.
- Howlett DC, Marchbank NDP, Sallomi DF. Ultrasound of the testis. *Clin Radiol* 2000;55:595–601.
- Gross M. Rupture of the testicle: the importance of early surgical treatment. *J Urol* 1969;101:196–197.
- Sudakoff GS, Quiroz F, Karcaaltincaba M, Foley WD. Scrotal ultrasonography with emphasis on the extratesticular space: anatomy, embryology, and pathology. *Ultrasound Q* 2002;18(4):255–273.
- Gorman B, Carroll BA. The scrotum. In: Rumack CM, Wilson SR, Charboneau JW, eds. *Diagnostic ultrasound*. 3rd ed. St Louis, Mo: Elsevier Mosby, 2005; 849–888.
- Jeffrey RB, Laing FC, Hricak H, McAninch JW. Sonography of testicular trauma. *AJR Am J Roentgenol* 1983;141:993–995.
- Cass AS, Luxenberg M. Testicular injuries. *Urology* 1991;37(6):528–530.
- Krone KD, Carroll BA. Scrotal ultrasound. *Radiol Clin North Am* 1985;23(1):121–139.
- Bree RL, Hoang DT. Scrotal ultrasound. *Radiol Clin North Am* 1996;34(6):1183–1205.
- Siegel MJ. The acute scrotum. *Radiol Clin North Am* 1997;35(4):959–976.
- Ragheb D, Higgins JL Jr. Ultrasonography of the scrotum: technique, anatomy, and pathologic entities. *J Ultrasound Med* 2002;21:171–185.
- Herbener TE. Ultrasound in the assessment of the acute scrotum. *J Clin Ultrasound* 1996;24:405–421.
- Fournier GR, Laing FC, McAninch JW. Scrotal ultrasonography in the management of testicular trauma. *Urol Clin North Am* 1989;16:377–385.
- Choe JM, Battino B. Testicular trauma. WebMD Web site. <http://www.emedicine.com/med/topic2859.htm>. Published July 20, 2004. Accessed August 21, 2006.
- Learch TJ, Hansch LP, Ralls PW. Sonography of patients with gunshot wounds of the scrotum: imaging findings and their value. *AJR Am J Roentgenol* 1995;165:879–883.
- Cline KJ, Mata JA, Venable DD, Eastham JA. Penetrating trauma to the male external genitalia. *J Trauma* 1998;44(3):492–494.
- Ridgway PF, Shah J, Darzi AW. Male genital tract injuries after contemporary inguinal hernia repair. *BJU Int* 2002;90:272–276.
- Taylor EW, Duffy K, Lee K, et al. Surgical site infection after groin hernia repair. *Br J Surg* 2004;91(1):105–111.
- Dattola P, Alberti A, Giannetto G, Basile G, Basile M. Inguino-crural hernias: preoperative diagnosis and post-operative follow-up by high-resolution ultrasonography—a personal experience. *Ann Ital Chir* 2002;73(1):65–68.
- Akbulut G, Serteser M, Yucel A, et al. Can laparoscopic hernia repair alter function and volume of testis? randomized clinical trial. *Surg Laparosc Endosc Percutan Tech* 2003;13(6):377–381.
- Hostetler MA. Burns, electrical. WebMD Web site. <http://www.emedicine.com/ped/topic2734.htm>. Published November 17, 2004. Accessed August 21, 2006.
- Escudero-Nafs FJ, Leiva-Oliva RM, Collado-Aromir F, Rabanal-Suarez F, De Molina-Nofiez JM. High-tension electrical burns: primary treatment of seventy patients. *Ann MBC* 1990;3(4):1–7. [http://www.medbc.com/annals/review/vol\\_3/num\\_4/text/vol3n4p256.htm](http://www.medbc.com/annals/review/vol_3/num_4/text/vol3n4p256.htm). Accessed August 21, 2006.
- Dee KE, Deck AJ, Waitches GM. Intratesticular pseudoaneurysm after blunt trauma. *AJR Am J Roentgenol* 2000;174:1136.

## US of Acute Scrotal Trauma: Optimal Technique, Imaging Findings, and Management

*Corinne Deurdulian, MD et al*

RadioGraphics 2007; 27:357–369 • Published online 10.1148/rg.272065117 • Content Codes: ER GU US

---

### Page 358

Mechanisms of trauma include blunt, penetrating, thermal (ie, burn), and degloving injuries.

### Page 364

Discontinuity of the echogenic tunica albuginea is indicative of testicular rupture and necessitates emergent surgery.

### Page 366

Potential complications of delayed diagnosis include testicular ischemic necrosis, abscess, and loss of spermatogenesis.

### Page 367

Testicular fractures and ruptures from penetrating injury are managed in the same way as are fractures and ruptures from blunt injury. In patients with complete vascular transection, immediate surgical exploration with microvascular reanastomosis is required.

### Page 368

A true electrical burn results from the passage of an electric current through the body, between points of entry and exit. Gray-scale US images of the scrotum in such cases may demonstrate infarction of the testis, and Doppler images may show no flow in one or both testes.