

The liver: how we do it

Fiona Macnaught and Nicole Campbell-Rogers

Department of Nuclear Medicine and Ultrasound, Westmead Hospital, Westmead, New South Wales, Australia.
Correspondence to Fiona Macnaught via ASUM. Email author@asum.com.au

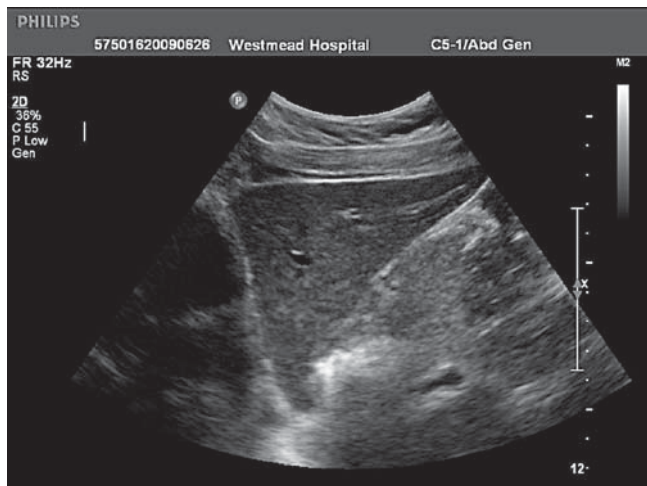


Fig. 1: Left lobe of the liver in sagittal, including the left hepatic vein.

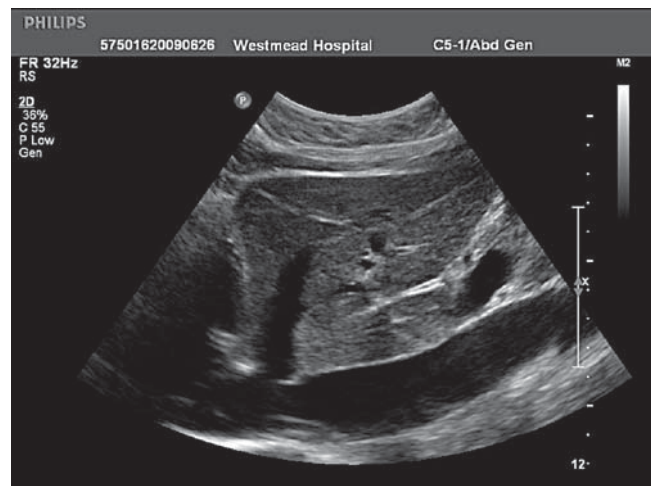


Fig. 2: Left lobe/caudate lobe in sagittal, with IVC.

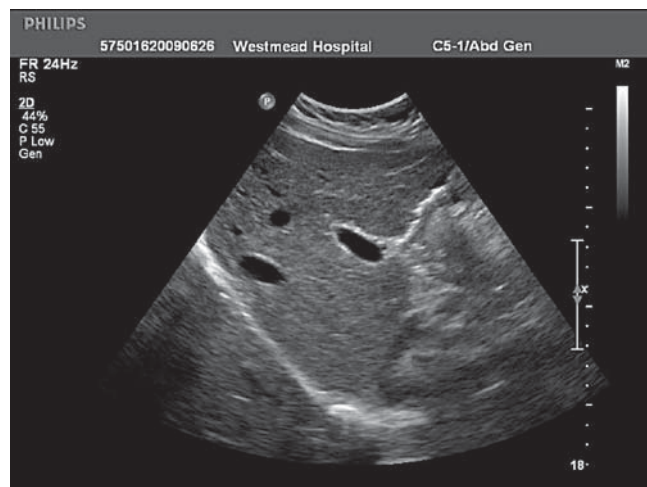


Fig. 3: Right lobe of the liver in sagittal at the level of the porta hepatus.

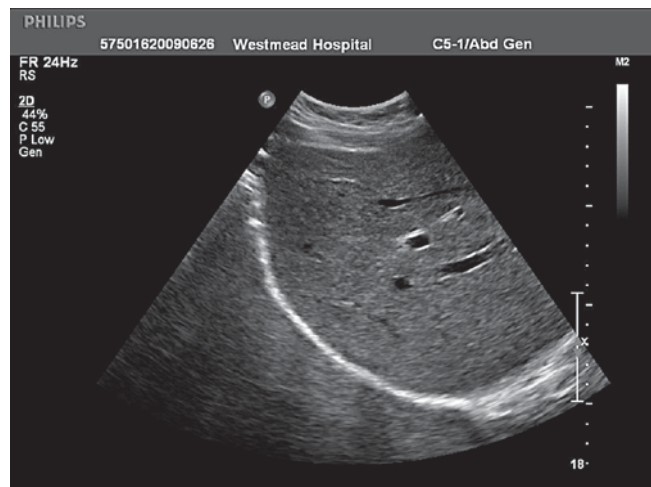


Fig. 4: Right lobe, dome region in sagittal. Comment should be made if there is right pleural fluid present.

The liver is the largest solid organ in the body and a large source of referrals for ultrasound assessment in our unit. Pain, abnormal liver function tests, suspected masses and infections as well as trauma comprise a significant proportion of the indications for liver assessment. Is it any wonder that imaging of the liver can be quite daunting? It is worth discussing the techniques used in our practice to aid in obtaining the highest quality diagnostic scan possible of the liver. Of all the organs in the body, liver ultrasound requires an intimate knowledge of the knobology of the machine so that the highest quality images are produced for each individual patient. Changing the TGC, depth, focus, focal zone, sector width, resolution and harmonics are essential.

High quality ultrasound equipment is used for liver scanning. The ultrasound machine should have greyscale, harmonic, colour Doppler, power Doppler and spectral Doppler capabilities. We use a curvilinear array transducer, typically

in the range of 5–2 MHz or 5–1 MHz. These frequency ranges allow for high resolution of the deeper structures within the liver, and adequate penetration of an enlarged, fatty or cirrhotic liver. One or more focal zones are selected, depending on the individual case at hand. On the rare occasion, you may also wish to interrogate the surface of the liver parenchyma using a higher resolution linear array transducer, such as an 8–4 MHz.

Patients in our centre are required to fast for at least six hours prior to the examination. We also ask them not to chew gum and to refrain from smoking for the same time period. In our experience, this minimises bowel gas, and allows adequate filling of the gallbladder.

Once in the scanning room the examination is explained to the patient and he or she is asked to raise the clothing from above their waist, and towels are placed under the shirt and into the waistband of the lower clothing to minimise gel

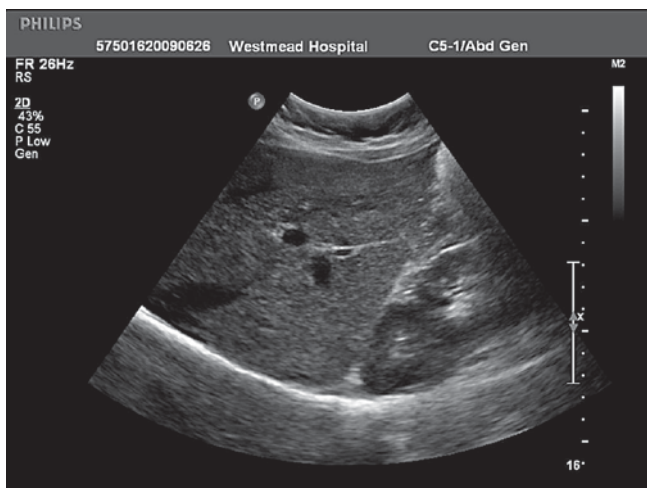


Fig. 5: Right lobe of liver/adjacent right kidney. This image is used to assess the echogenicity of the liver.

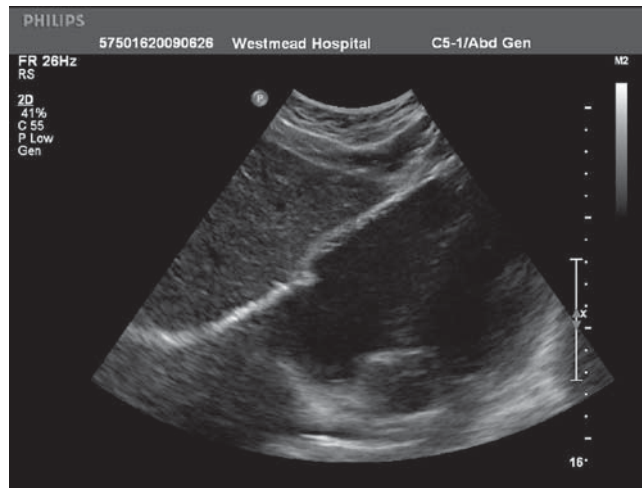


Fig. 6: Left lobe of the liver in transverse, including the heart. Comment should be made if pericardial fluid is present.

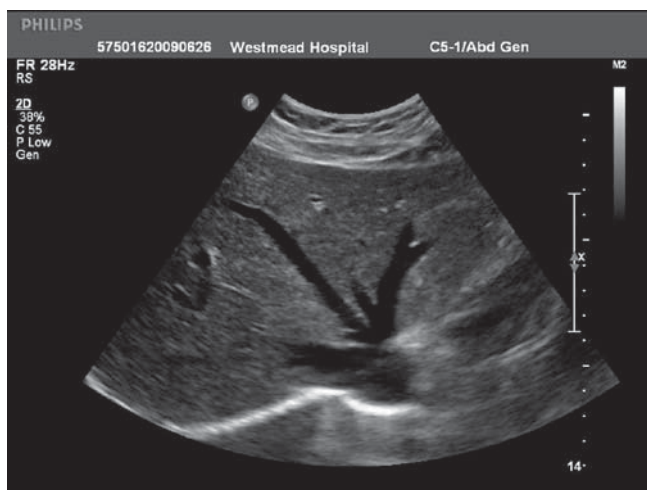


Fig. 7: Transverse assessment of the hepatic veins. This can usually be achieved subcostally, however, the intercostal approach may be needed in certain cases. In our centre, we document colour flow in the hepatic vessels and, in certain clinical settings, will document spectral Doppler traces from all three hepatic veins at the IVC confluence.

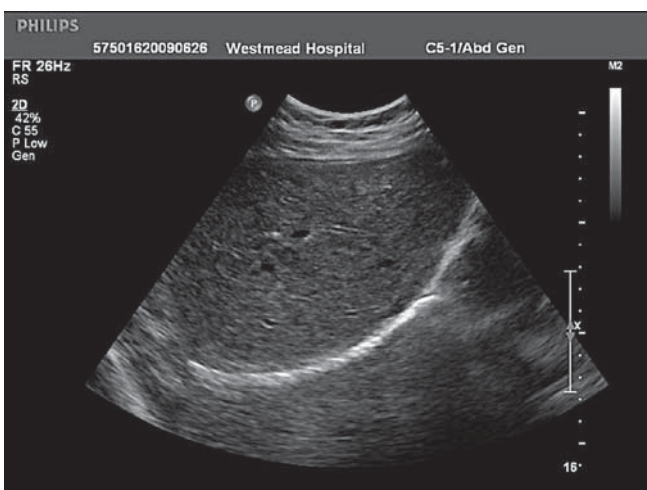
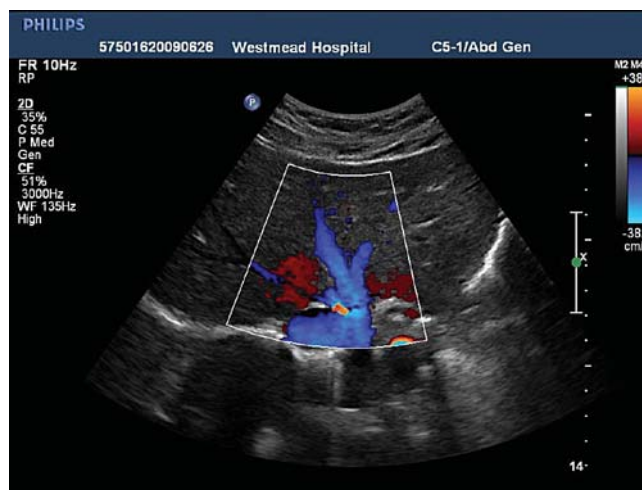

Fig. 8: Transverse image of the right dome area.

contamination to the patient's clothes. The patient then lies supine on the scanning table and warm gel is applied to the abdomen. Typically, the head of the scanning bed is inclined at 10–15°. This aids with patient comfort, and allows optimal imaging of the liver.

Initial assessment of the liver involves scanning from lateral to the left lobe, through the entire left lobe, caudate lobe, then right lobe and out of the right lobe in the sagittal plane.

(Fig. 1) This is done initially from a subcostal approach. If the entire liver cannot be adequately visualised, we ask the patient to take a deep breath and hold for as long as possible, then repeat the sagittal sweep. When language and communication are difficult, it often helps to breathe deeply and hold your breath to demonstrate to the patient what you require of him or her. If the liver is still not adequately visible, it may be necessary to roll the patient onto their left side in a decubitus position, with the right arm stretched above the head. This can aid in moving the liver out from the ribs.

Once the liver has been assessed in the sagittal plane, turn the transducer through 90° and interrogate the liver in the transverse plane. Ensure that you can see from the dome right down to the lower segment. Again, this may require a combination of breath holding and multiple body positions.

Another technique that can be employed for the liver scan is to image intercostally (between the ribs). This can be done in both the sagittal and transverse planes with the transducer being moved over the relevant intercostal spaces.

Careful observation of the surface of the liver should be made, and notes taken on whether the liver has a smooth border, or a nodular appearance. Also, an overall assessment of the size of the liver should be made.

In our unit, the size of the liver is assessed visually on a case by case basis. Measurement of the liver is not



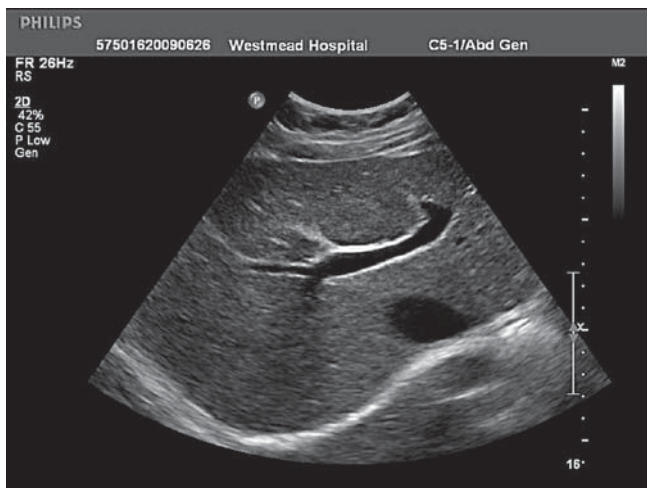


Fig. 9: Transverse image of the porta hepatis.

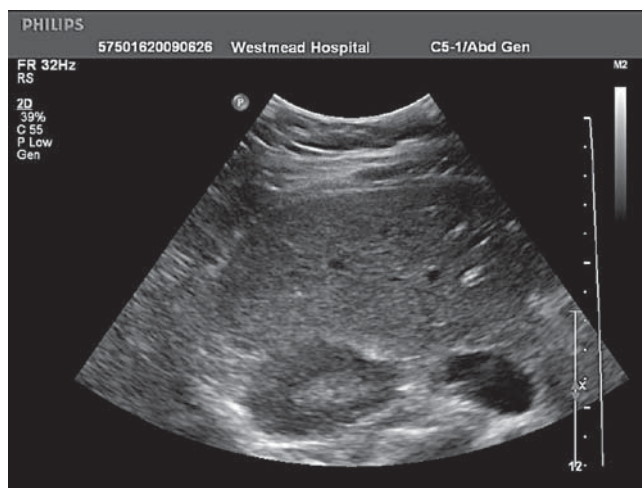


Fig. 10: Transverse image of the lower segment including superior pole of the right kidney.

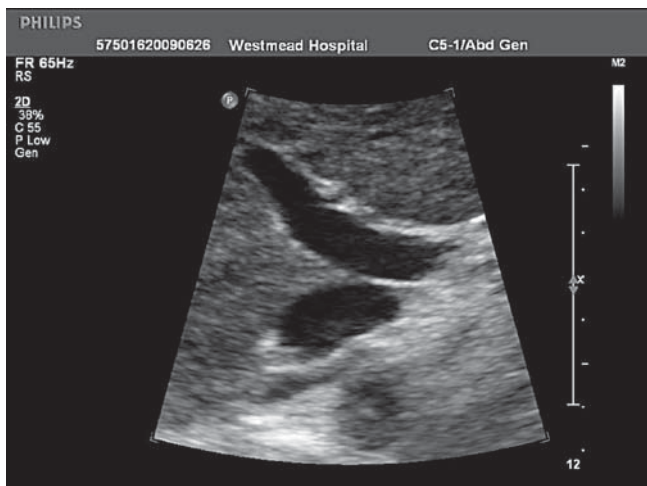


Fig. 11: Assessment of the porta hepatis. Decide whether to assess the structures around the porta hepatis using a subcostal and/or intercostal approach. A measurement of the main portal vein at the porta hepatis should be obtained on a high definition zoomed image as well as colour and spectral analysis. Comment should be made of the vessel diameter, with the upper limit of normal at 13 mm (Rumack, Wilson and Charboneau, 2005). For spectral assessment, ensure that the MPV is directed up towards the liver, then record the direction of the bloodflow within it. Towards the liver is known as hepatopetal (normal), however situations may exist where flow is reversed (hepatofugal) or bidirectional.

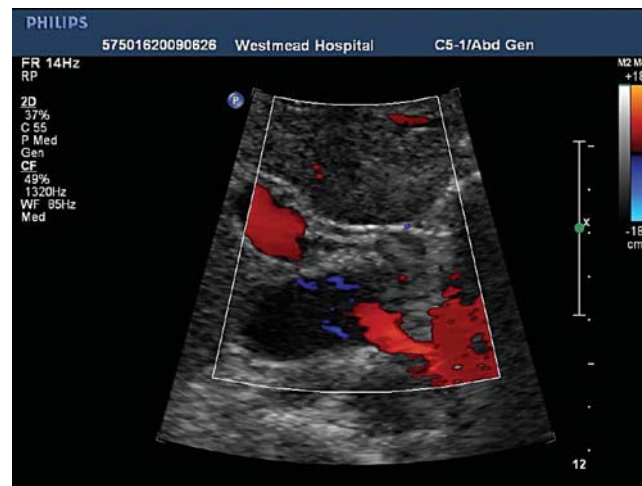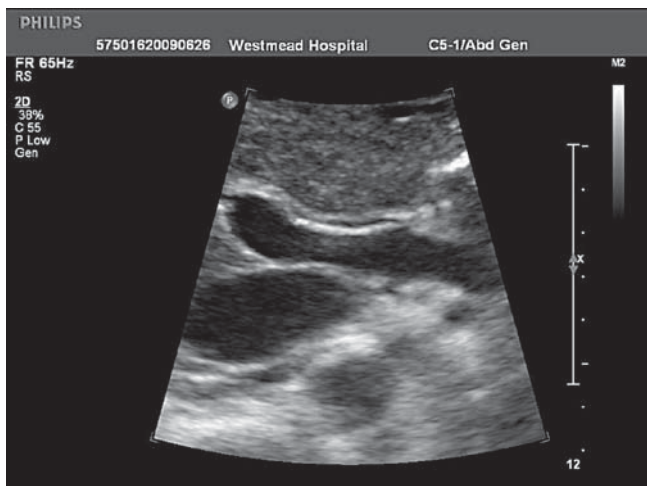
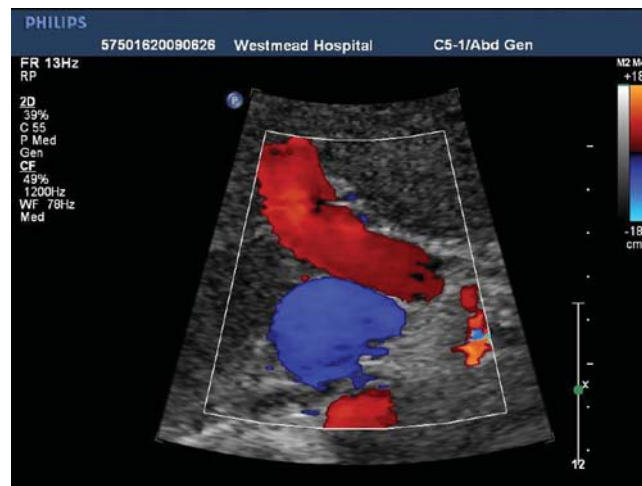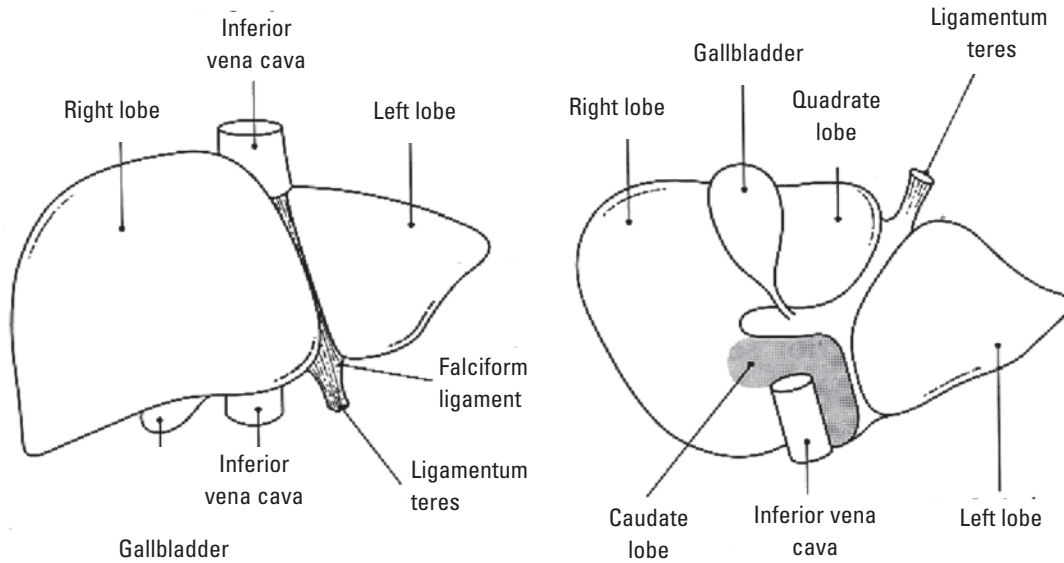


Fig. 12: Assessment of the common bile duct. Ideally we would like to interrogate the CBD throughout its entire course from the liver to the pancreas, however this may be challenging due to the presence of bowel gas. A measurement of the CBD (inner border to inner border) should be obtained at the level of the portal vein bifurcation, as well as more distally if it appears to have a greater diameter in that region. The presence of debris, calculi or other material within the duct should be noted. We usually accept 6mm as the upper limit of normal for CBD diameter. Patients post cholecystectomy typically have a CBD which is greater in calibre than 6 mm. (Rumack, *et al.* 2005).



Gross anatomy of the liver.

undertaken in our unit due to documented variability in obtaining an accurate and reproducible result. Comment should also be made on the general echotexture and echogenicity of the liver. For example, does it appear smooth, without great variations in grey levels, or coarse with many patchy ill-defined areas throughout? The echogenicity of a normal liver should appear isoechoic to a normal kidney. A very echogenic liver will appear as bright as the portal vein branches, and thus make resolution of the vessels difficult.

Once you can be certain that you have interrogated all eight segments of the liver, record representative images (Figs. 1–12).

If there are focal lesions present within the liver, each should be individually measured in three planes. The border of the lesion should be assessed (as smooth, nodular, etc.), as well as the internal echotexture. Colour Doppler and spectral waveforms of any internal or peripheral vessels should be obtained. The position of each lesion should be assessed and where possible determination of the segmental location should be noted. In some centres an assessment using ultrasound contrast agents may be obtained, however we do not use these at our centre.

Various artifacts may be present during ultrasound assessment of the liver, and as a sonographer you should be aware of these. For example, when scanning at the level of the diaphragm, a mirror artifact may be seen due to full reflection of the sound waves from the airfilled lung above the diaphragm. Also, particularly in elderly patients, the

ligamentum teres may become calcified, which can appear as a shadowing mass within the liver parenchyma in the short axis. This “lesion” will, however, elongate when the transducer is rotated into the longitudinal plane. Remember, all real lesions must be visible in two planes.

As with any ultrasound investigation, we may encounter difficulties whilst imaging the liver. Communication issues may present challenges, however body language and demonstration of breathing techniques by the sonographer can help to overcome these. Some patients do not have favourable body habitus for ultrasound, however, if you optimise the machine settings and image in a number of patient positions you will ensure that you have obtained the best images possible for that patient. In our experience, satisfactory investigation and images of the liver can be obtained in most patients in 10–15 minutes. Where appropriate, limitations need to be conveyed to the referring physician.

In summary, thoughtful preparation and attention to technique permit good quality liver ultrasound examinations.

References

- 1 Bisset RAL, Khan AN. *Differential Diagnosis in Abdominal Ultrasound*. London: WB Saunders; 2002. pp 28.
- 2 Rumack C, Wilson S and Charboneau J. *Diagnostic Ultrasound 3rd ed*. Missouri: Mosby; 2005. pp 172–3.

