



**PHILIPS**

Ultrasound

## Quick guide

# POC ultrasound for AAA

**Bob Jones, DO, FACEP**

MetroHealth Medical Center, Cleveland, OH

**Diane Gramer, RDMS, RVT, RT(R)**

MetroHealth Medical Center, Cleveland, OH

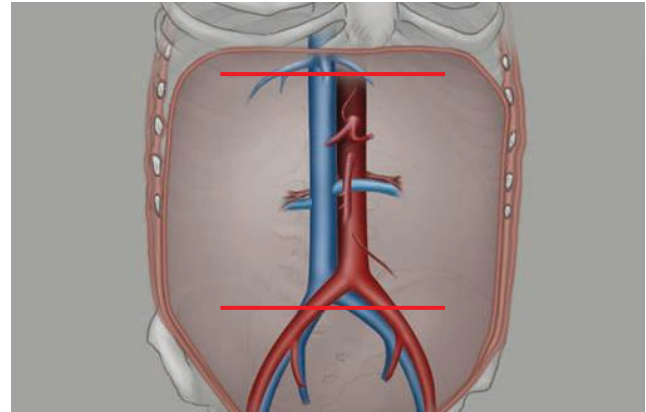
## The more you see, the more you can do

Ruptured abdominal aortic aneurysms (AAAs) are associated with a very high mortality rate. Only about 50% of patients with leaking or ruptured AAAs will have the classic triad of back pain, hypotension, and a pulsatile mass. Prompt recognition and emergent surgical management are key factors in reducing morbidity and mortality. The use of bedside ultrasound can rapidly diagnose the presence of an AAA and provide more rapid disposition.<sup>1-3</sup>

# POC ultrasound for AAA

## The basics

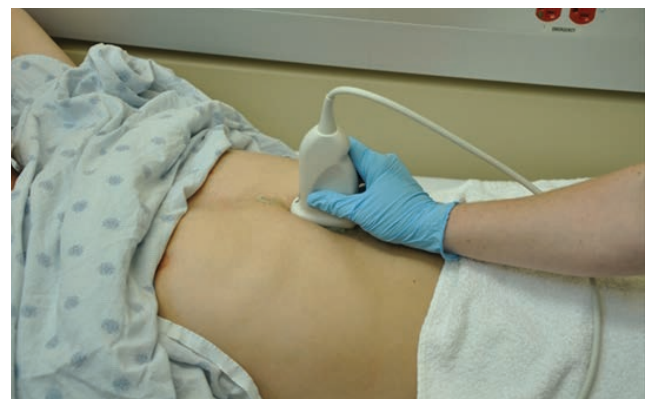- A low frequency transducer (in the range of 1–5 MHz) is needed for adequate penetration.
- A curvilinear transducer with a large footprint may allow for easy transducer manipulation on the abdominal wall.
- It is also possible to use a low frequency phased array transducer.
- The aorta must be evaluated from the diaphragm down to the bifurcation into the iliac arteries.
- The aorta is scanned in both the sagittal and transverse planes.
- Note that the majority of AAAs are infrarenal.



Scan the aorta from the diaphragm to the bifurcation into the iliac arteries in both the sagittal and transverse planes

## Sonographic evaluation – sagittal view

- The exam is begun by placing the transducer in a sagittal plane in the subcostal region. The transducer orientation marker is toward the patient's head.
- The proximal aorta and its branches will be identified in its long axis. Note the pulsations of the aorta.

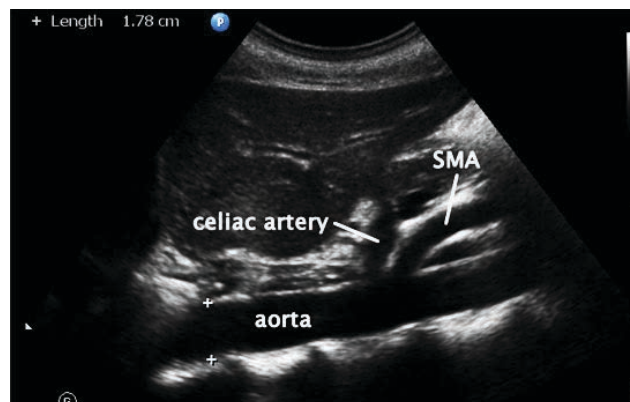


Transducer placement for the sagittal view

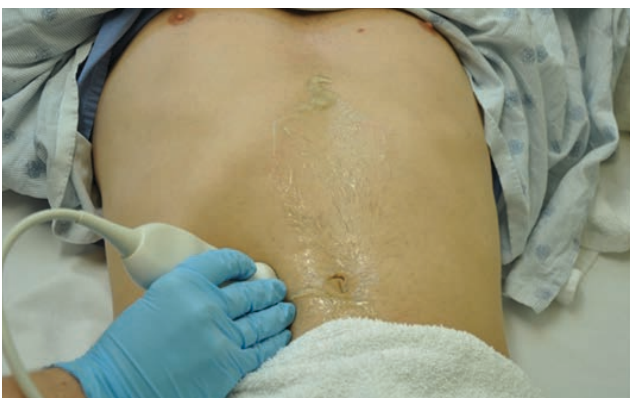# POC ultrasound for AAA

## Sonographic evaluation – sagittal view *continued*

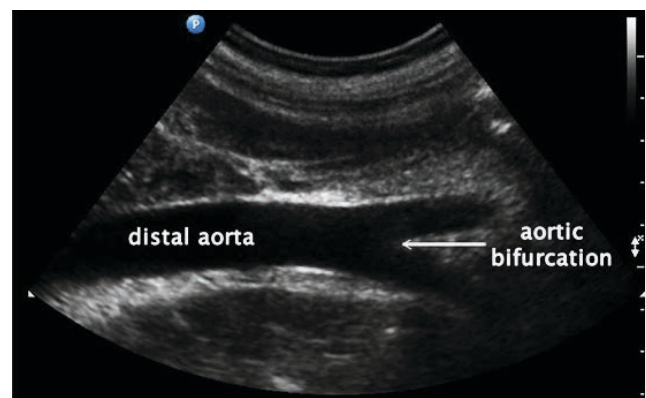
- Visualizing the SMA and celiac branches can be used to confirm the identity of the aorta. The inferior vena cava (IVC) will have counter-pulsations seen during real-time scanning and could potentially be confused with the aorta in the sagittal plane.
- Using a rock-and-glide technique, slide the transducer in a caudal direction following the aorta in its sagittal plane. Increased transducer pressure may be needed in this region to displace bowel gas.
- Follow the aorta using the rock-and-glide technique until reaching bifurcation. The distal aorta becomes more superficial so the depth may need to be decreased as the transducer is moved caudally.
- At the level of the bifurcation, the transducer can be moved to the patient's right and angled toward the aorta to visualize both the right and left common iliac arteries in a coronal view.



Sagittal image of the proximal aorta with celiac artery and SMA branches noted



Transducer placement for a coronal view of the aortic bifurcation

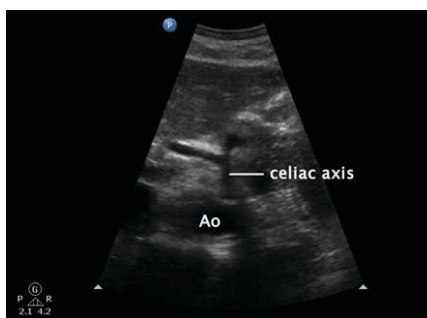


Coronal image of the aortic bifurcation

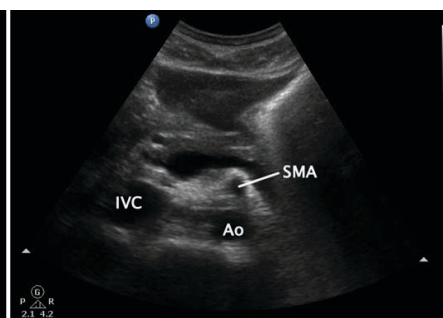
# POC ultrasound for AAA

## Sonographic evaluation – transverse view

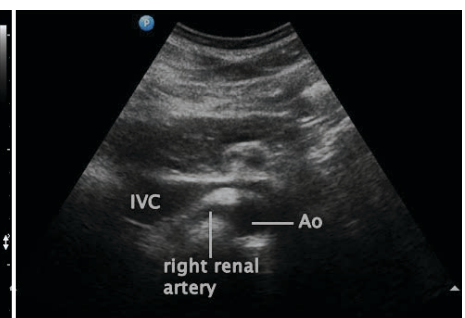
- The transducer is placed in the transverse plane in the subcostal space. The transducer orientation marker is directed toward the patient's right.
- The depth should be set so that the relationship of the aorta to the vertebral body can be determined. Failure to allow enough depth on the screen is a common imaging pitfall.
- Slide the transducer down in a caudal direction. The celiac axis will be the first branch noted to arise from the aorta. Due to its appearance, it is commonly referred to as the *seagull sign*.
- Move the transducer in a caudal direction. The SMA will be noted next as it arises from the aorta and passes anterior to the aorta.
- Continuing caudal, the next branches of the aorta visualized are the paired renal arteries. Identifying the renal arteries can be helpful to the vascular surgeon since the relationship of the aneurysm to the renal arteries can determine the surgical approach.
- Follow the aorta in the transverse plane until the bifurcation is reached.



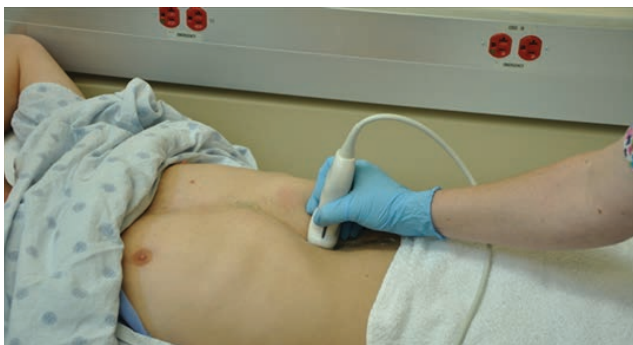Transverse view – level of the celiac axis



Transverse view – level of the SMA



Transverse view – level of the right renal artery

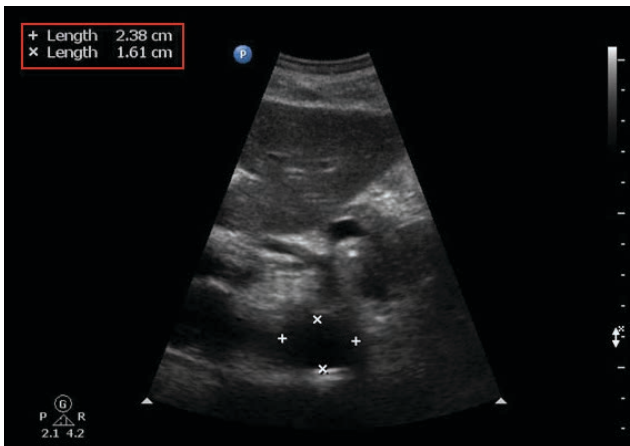


Transverse view – transducer placement

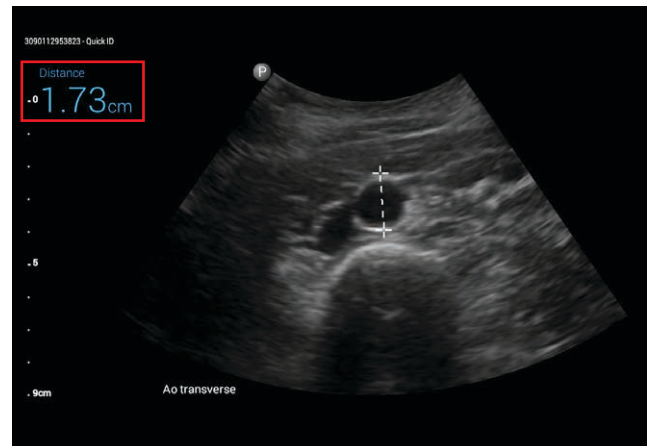
# POC ultrasound for AAA

## Measuring the aorta

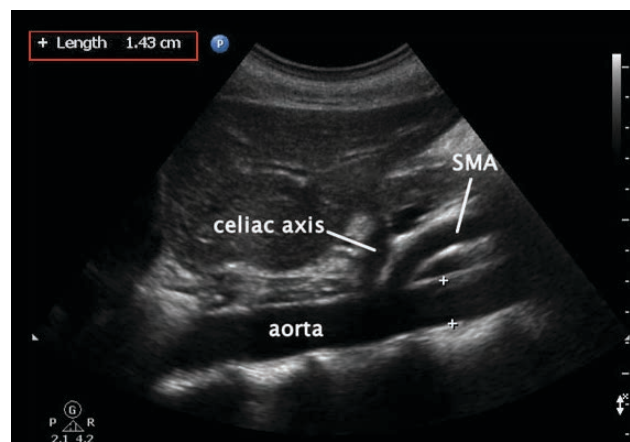
- The normal aorta is no larger than 3 cm in diameter at any point. The aorta tapers distally as it approaches its bifurcation.
- The aorta can be measured in both the sagittal and transverse planes. The measurements are taken from the outer wall-to-outer wall.
- Measuring in the transverse orientation is less susceptible to tangential measuring error, as a longitudinal view can be outside the plane of the widest section of the aneurysm and can give a falsely small measurement.
- The normal maximum diameter of the common iliac artery is 1.5 cm in men and 1.2 cm in women.



Transverse view of a normal aorta with measurements



Transverse view of the aorta measuring 1.73 cm

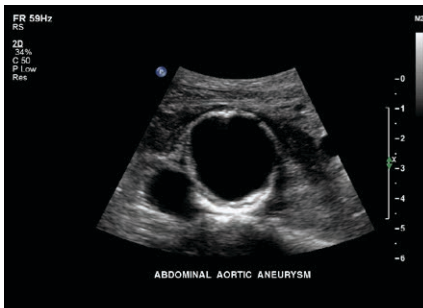


Sagittal view of the aorta measuring 1.43 cm

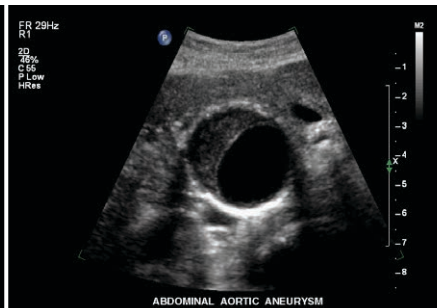
# POC ultrasound for AAA

## Abdominal aortic aneurysm

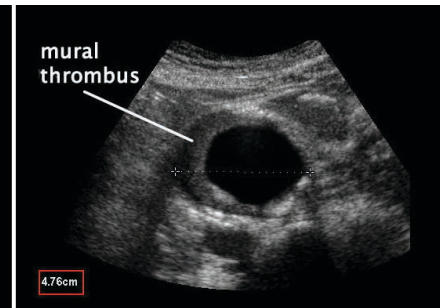
- Sonographic criteria for the diagnosis of an AAA include a focal dilatation of the abdominal aorta of more than 3 cm, an increase in the aortic diameter to 1.5 times the normal expected diameter, and a ratio of infrarenal to suprarenal aortic diameter of 1.2 cm or greater.
- Aneurysms can be defined by location: suprarenal, juxtarenal and infrarenal. Over 90% of abdominal aneurysms are infrarenal.
- Aneurysms can be defined by shape: fusiform, saccular, and hourglass. Most abdominal aneurysms are fusiform.
- Aneurysms can be associated with atherosclerotic changes, which include atherosclerotic plaques with or without calcifications and/or mural thrombus.



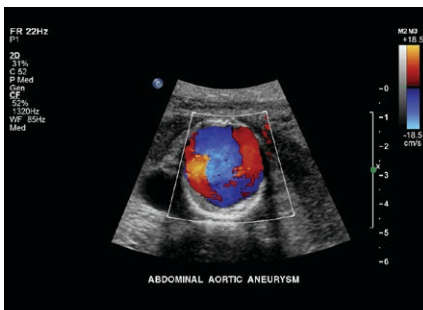
Transverse view of AAA



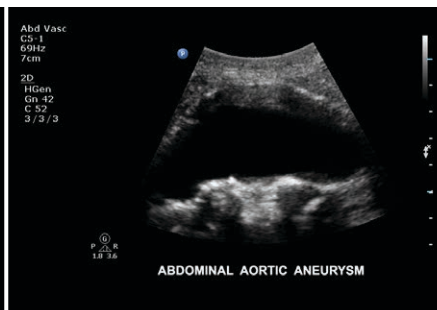
Transverse view of AAA with mural thrombus



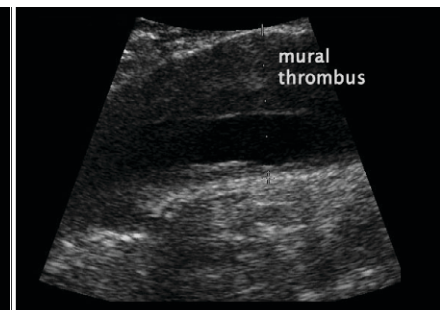
Transverse view of AAA with mural thrombus



Transverse view of AAA with color Doppler



Zoomed sagittal view of AAA



Zoomed sagittal view of AAA with mural thrombus

# POC ultrasound for AAA

## Clinical pearls

- Bedside ultrasound is essentially 100% sensitive in the detection of AAA and can be used to quickly include or exclude the diagnosis of AAA. Patients found to have a normal aorta can be evaluated for other potential diagnoses.
- Do not mistake the IVC for the abdominal aorta. Confirm by scanning both sagittally and transversely. The IVC is more easily compressible, and does not have a thick wall. The aorta is more resistant to compression.
- With advancing age, the abdominal aorta often becomes tortuous and takes a winding path. Care must be taken to follow it along its entire length.
- Remember the coronal approach if bowel gas is impeding the image.
- Look carefully for any evidence of echogenic thrombus. A well-organized thrombus around the lumen may make the aneurysm more difficult to see.
- Measure the aorta outerwall-to-outerwall (including mural thrombus, if present).
- Measure the aorta in the transverse view to ensure you are not underestimating the size.
- Bowel gas is frequently encountered. Applying firm, slow, direct pressure by pressing down on the patient's abdomen with the transducer helps displace the bowel gas to allow visualization of the aorta.
- Hemodynamically unstable patients with large AAAs (>5.5 cm) should be taken emergently to the operating room for repair.
- In patients with an AAA, the diagnosis of aortic rupture is made only 4% of the time with ultrasound and is usually based on the presence of a complex fluid collection in the retroperitoneum.<sup>2</sup>
- Ultrasound is considered to be insensitive for the detection of direct evidence of rupture. Findings such as luminal disruption or retroperitoneal hematomas are reported to be detected infrequently with ultrasound.<sup>4</sup>
- Patients with aortic dissection may present in a similar fashion as patients with aortic rupture. Therefore, it is important to recognize the sonographic findings associated with aortic dissection. Aortic dissection is diagnosed by the identification of an undulating intimal flap. The lumen is divided by the flap into a true and false lumen.

# POC ultrasound for AAA

## Bibliography

1. Kuhn M, et al. Emergency department ultrasound scanning for abdominal aortic aneurysm: accessible, accurate, and advantageous. *Ann Emerg Med.* 2000;36(3):219-23.
2. Shuman W, et al. Suspected leaking abdominal aortic aneurysm: use of sonography in the emergency room. *Radiology.* 1988;168(1):117-9.
3. Tayal VS, Graf CD, Gibbs MA. Prospective study of accuracy and outcome of emergency ultrasound for abdominal aortic aneurysm over two years. *Acad Emerg Med.* 2003;10(8):867-71.
4. Catalano O, Siani A. Ruptured abdominal aortic aneurysm: categorization of sonographic findings and report of 3 new signs. *J Ultrasound Med.* 2005;24(8):1077-83.



---

For additional resources related to **POC ultrasound** visit [www.philips.com/CCEducation](http://www.philips.com/CCEducation)

---

For information about **Philips Sparq ultrasound system** go to [www.philips.com/sparq](http://www.philips.com/sparq)

---

For more information about **Lumify, the Philips app-based ultrasound system**, go to: [www.Philips.com/Lumify](http://www.Philips.com/Lumify) or call 1-844-MYLUMIFY

---

For feedback or comments please contact us at [www.ultrasoundeducation@philips.com](mailto:www.ultrasoundeducation@philips.com)

This quick guide document reflects the opinion of the author, not Philips. Before performing any clinical procedure, clinicians should obtain the requisite education and training, which may include fellowships, preceptorships, literature reviews, and similar programs. This paper is not intended to be a substitute for these training and education programs, but is rather an illustration of how advanced medical technology is used by clinicians.

